

# Use of rubber bands for circumscribed application of topical eutectic mixture of local anaesthetics cream


## Problem

Topical anaesthetics are widely used in day-to-day practice for many minor dermatologic procedures. However, at times they fail to give the desired effect because of the spillage of cream to the surrounding area. To prevent this spillage, the use of a surgical tape loop has been suggested by the authors in the past.<sup>1</sup>We observed, however, that creating a loop with surgical tape is somewhat cumbersome and not suitable for small areas.


## Solution

To overcome this problem, we describe the use of rubber bands of varied sizes to minimise the spread of local anaesthetic cream beyond the desired area. These are freely available in most general stores and the appropriate size

[Figure 1] can be chosen according to the size of the area to be anaesthetised. The rubber band of appropriate size is stuck on the surgical tape [Figure 2]. The local anaesthetic cream is filled in the rubber band loop and this cream-filled contraction may be stuck on the skin [Figure 3]. We have not noticed any contact dermatitis with these rubber bands so far. This technique can be used on any anatomical site and at any age including children and the patients can lie down or sit comfortably after application. We have observed a marked improvement in quality, time of onset, and duration of anaesthesia achieved with this method. However, we have not done any comparative study so far. The rubber bands are easily available and disposable thus making this technique more user friendly than using a surgical tape loop as described previously.



**Figure 1:** Different sizes of rubber bands that can be used as per requirement.



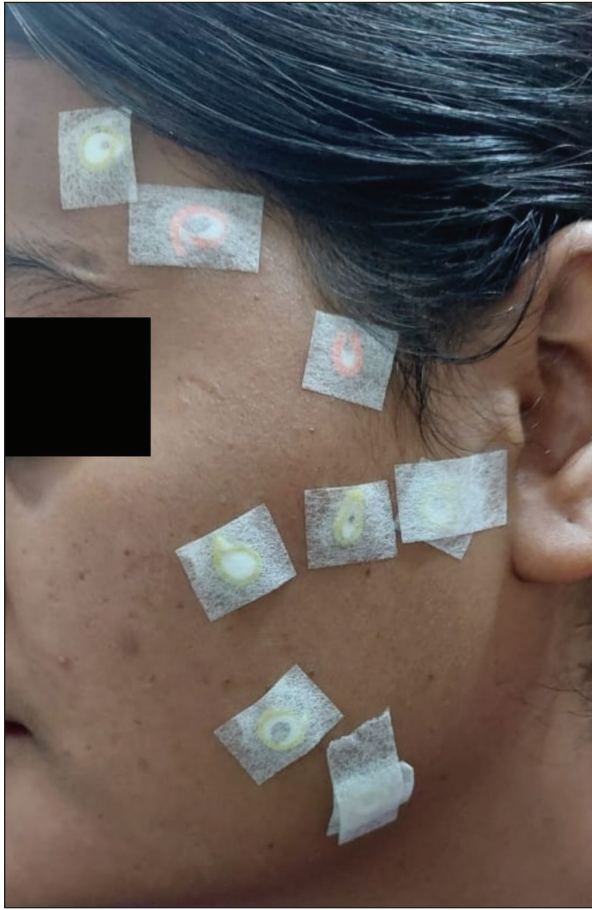**Figure 2:** Rubber band filled with local anaesthetic cream and stuck on the surgical tape.

**How to cite this article:** Gupta S, Jangra RS, Gupta N. Use of rubber bands for circumscribed application of topical eutectic mixture of local anaesthetics cream. *Indian J Dermatol Venereol Leprol.* 2024;90:694-5. doi: 10.25259/IJDVL\_1247\_2023

**Received:** November 2023 **Accepted:** December 2023 **Epub Ahead of Print:** April, 2024 **Published:** August, 2024

**DOI:** 10.25259/IJDVL\_1247\_2023 **PMID:** 38841973

This is an open-access article distributed under the terms of the Creative Commons Attribution-Non Commercial-Share Alike 4.0 License, which allows others to remix, tweak, and build upon the work non-commercially, as long as the author is credited and the new creations are licensed under the identical terms.



**Figure 3:** Surgical tape stuck on the skin area to be anaesthetised.

**Declaration of patient consent:** Authors certify that they have obtained appropriate patient consent.

**Financial support and sponsorship:** Nil.

**Conflicts of interest:** There are no conflicts of interest.

**Use of artificial intelligence (AI)-assisted technology for manuscript preparation:** The authors confirm that there was no use of artificial intelligence (AI)-assisted technology for assisting in the writing or editing of the manuscript and no images were manipulated using AI.

**Sanjeev Gupta, Ravi Shankar Jangra<sup>1</sup>,  
Nanya Gupta<sup>2</sup>**

Departments of Dermatology, Maharishi Markandeshwar Institute of Medical Sciences and Research, Ambala, Haryana, <sup>1</sup>Sun Skin Clinic, Ambala, <sup>2</sup>Kalpana Chawla Government Medical College, Karnal, Haryana, India.

**Corresponding author:**

Dr. Sanjeev Gupta,  
Department of Dermatology, Maharishi Markandeshwar Institute of Medical Sciences and Research, Ambala, Haryana, India.  
sanjeevguptadr@gmail.com

### Reference

1. Jangra RS, Gupta S, Gupta S, Anu. Sticky boundary to retain a thick layer of eutectic mixture of local anesthetics cream at surgical site for effective anesthesia. *J Am Acad Dermatol* 2020;83:e7–e9.