

Cerebriform congenital melanocytic naevus on the sole

A 24-years old woman presented with asymptomatic, raised, black, skin lesions on the sole of her right foot since birth. Examination revealed three, hyperpigmented nodulo-plaques on the right foot distal plantar aspect proximal to the second toe. [Figure 1a]. Dermoscopy showed cerebriform appearance with sulci and gyri [Figure 1b]. Histopathology showed basaloid naevus cells with

melanin in the upper dermis and naevus cells interspersed within the dense collagen bundles and extended around the adnexal structures. A diagnosis of cerebriform congenital melanocytic naevus (CMN) was made, which is a rare morphological variant of CMN reported previously on the scalp. The index case is the first report of cerebriform CMN on the sole of the foot.

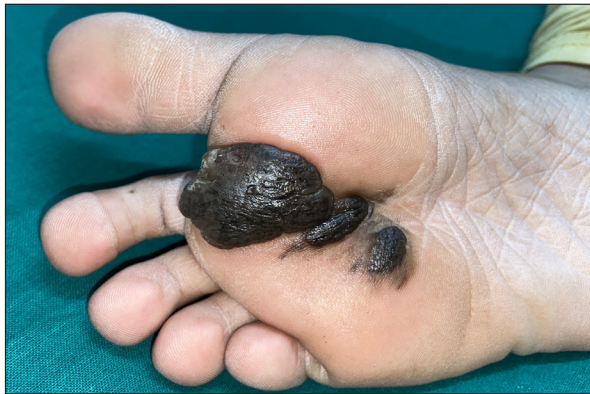

Figure 1a: Three well-defined hyperpigmented plaques on the sole of the right foot.

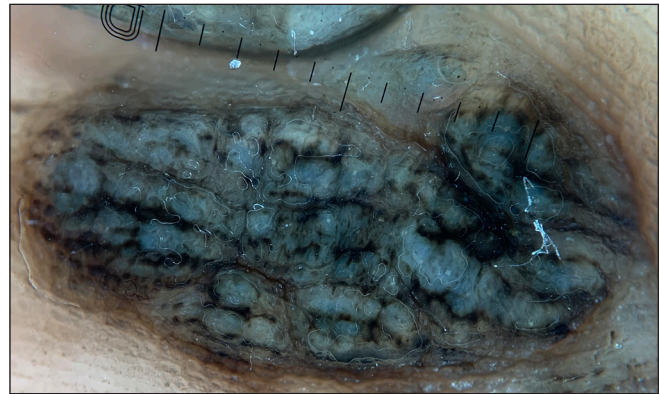


Figure 1b: Dermoscopy (Dermlite, 10x, polarised mode) showing prominent sulci and gyri, giving a cerebriform appearance of the naevus with accentuation of pigmentation in the sulci.

Declaration of patient consent: The authors certify that they have obtained all appropriate patient consent.

Financial support and sponsorship: Nil.

Conflicts of interest: There are no conflicts of interest.

Use of artificial intelligence (AI)-assisted technology for manuscript preparation: The authors confirm that there was no use of artificial intelligence (AI)-assisted technology for assisting in the writing or editing of the manuscript and no images were manipulated using AI.

Akshay Meena^{1*}, **Arun Somasundaram^{1*}**,
Karthik L¹, **Sheetanshu Kumar¹**, **Pampa Ch Toi¹**

¹Department of Dermatology & Sexually Transmitted Diseases,
Jawaharlal Institute of Postgraduate Medical Education and
Research, Puducherry, India.

*Contributed equally as first authors.

Corresponding author:

Dr. Sheetanshu Kumar,

Department of Dermatology & Sexually Transmitted Diseases,
Jawaharlal Institute of Postgraduate Medical Education and
Research, Puducherry, India.

kumar.sheetanshu@gmail.com

How to cite this article: Meena A, Somasundaram A, L K, Kumar S, Toi PC. Cerebriform congenital melanocytic naevus on the sole. Indian J Dermatol Venereol Leprol. doi: 10.25259/IJDVL_1518_2024

Received: October, 2024 **Accepted:** February, 2025 **Epub Ahead of Print:** March, 2025

DOI: 10.25259/IJDVL_1518_2024

This is an open-access article distributed under the terms of the Creative Commons Attribution-Non Commercial-Share Alike 4.0 License, which allows others to remix, transform, and build upon the work non-commercially, as long as the author is credited and the new creations are licensed under the identical terms.