

Indian Journal of Dermatology, Venereology & Leprology

Journal indexed with SCI-E, PubMed, and EMBASE

Vol 74 | Issue 2 | Mar-Apr 2008

C O N T E N T S

EDITORIAL

Management of autoimmune urticaria

Arun C. Inamadar, Aparna Palit 89

VIEW POINT

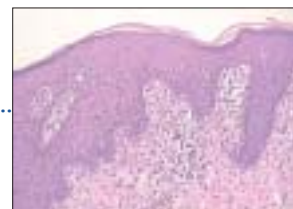Cosmetic dermatology versus cosmetology: A misnomer in need of urgent correction

Shyam B. Verma, Zoe D. Draelos 92

REVIEW ARTICLE

Psoriasiform dermatoses

Virendra N. Sehgal, Sunil Dogra, Govind Srivastava, Ashok K. Aggarwal 94



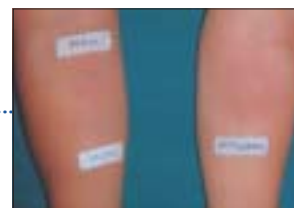ORIGINAL ARTICLES

A study of allergen-specific IgE antibodies in Indian patients of atopic dermatitis

V. K. Somani 100

Chronic idiopathic urticaria: Comparison of clinical features with positive autologous serum skin test

George Mamatha, C. Balachandran, Prabhu Smitha 105



Autologous serum therapy in chronic urticaria: Old wine in a new bottle

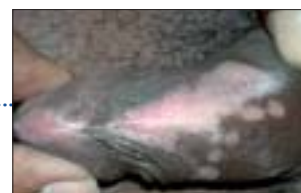A. K. Bajaj, Abir Saraswat, Amitabh Upadhyay, Rajetha Damisetty, Sandipan Dhar 109

Use of patch testing for identifying allergen causing chronic urticaria

Ashimav Deb Sharma 114

Vitiligoid lichen sclerosis: A reappraisal

Venkat Ratnam Attali, Sasi Kiran Attali 118



BRIEF REPORTS

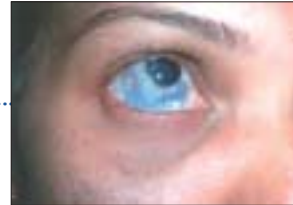Activated charcoal and baking soda to reduce odor associated with extensive blistering disorders

Arun Chakravarthi, C. R. Srinivas, Anil C. Mathew 122



Nevus of Ota: A series of 15 cases

Shanmuga Sekar, Maria Kuruvila, Harsha S. Pai 125



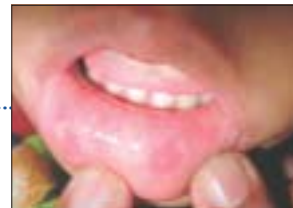Premature ovarian failure due to cyclophosphamide: A report of four cases in dermatology practice

Vikrant A. Saoji 128

CASE REPORTS

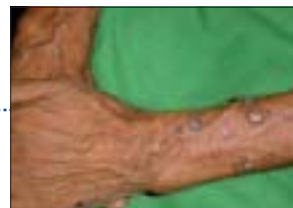Hand, foot and mouth disease in Nagpur

Vikrant A. Saoji 133



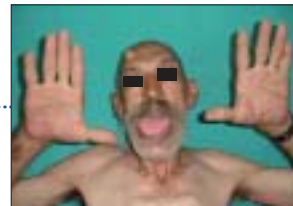Non-familial multiple keratoacanthomas in a 70 year-old long-term non-progressor HIV-seropositive man

Hemanta Kumar Kar, Sunil T. Sabhnani, R. K. Gautam, P. K. Sharma, Kalpana Solanki, Meenakshi Bhardwaj 136



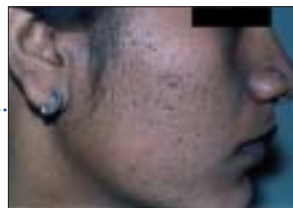Late onset isotretinoin resistant acne conglobata in a patient with acromegaly

Kapil Jain, V. K. Jain, Kamal Aggarwal, Anu Bansal 139



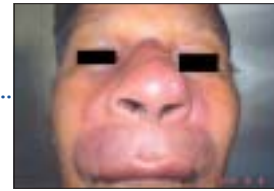Familial dyskeratotic comedones

M. Sendhil Kumaran, Divya Appachu, Elizabeth Jayaseelan 142



Nasal NK/T cell lymphoma presenting as a lethal midline granuloma

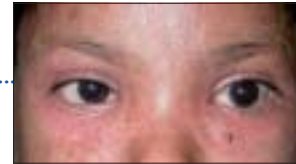Vandana Mehta, C. Balachandran, Sudha Bhat, V. Geetha, Donald Fernandes



145

Childhood sclerodermatomyositis with generalized morphea

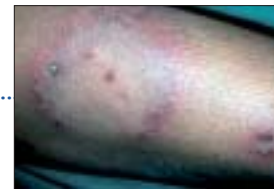Girishkumar R. Ambade, Rachita S. Dhurat, Nitin Lade, Hemangi R. Jerajani.....



148

Subcutaneous panniculitis-like T-cell cutaneous lymphoma

Avninder Singh, Joginder Kumar, Sujala Kapur, V. Ramesh.....



151

LETTERS TO EDITOR

Using a submersible pump to clean large areas of the body with antiseptics

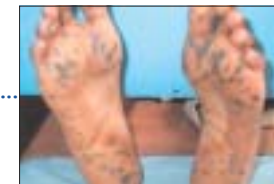C. R. Srinivas



154

Peutz-Jeghers syndrome with prominent palmoplantar pigmentation

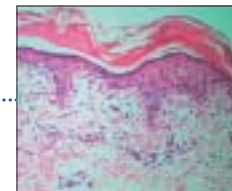
K. N. Shivaswamy, A. L. Shyamprasad, T. K. Sumathi, C. Ranganathan



154

Stratum corneum findings as clues to histological diagnosis of pityriasis lichenoides chronica

Rajiv Joshi



156

Author's reply

S. Pradeep Nair

157

Omalizumab in severe chronic urticaria

K. V. Godse.....

157

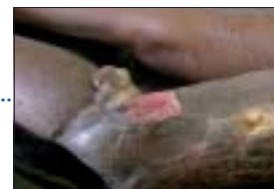Hypothesis: The potential utility of topical eflornithine against cutaneous leishmaniasis

M. R. Namazi

158

Nodular melanoma in a skin graft site scar

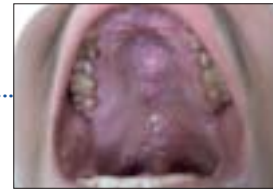A. Gnaneshwar Rao, Kamal K. Jhamnani, Chandana Konda



159

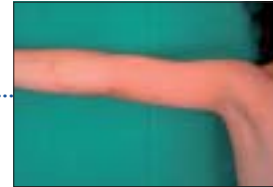Palatal involvement in lepromatous leprosy

A. Gnaneshwar Rao, Chandana Konda, Kamal Jhamnani..... 161



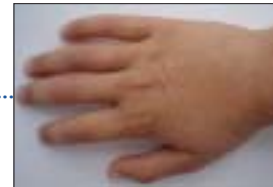Unilateral nevoid telangiectasia with no estrogen and progesterone receptors in a pediatric patient

F. Sule Afsar, Ragip Ortac, Gulden Diniz 163



Eruptive lichen planus in a child with celiac disease

Dipankar De, Amrinder J. Kanwar..... 164

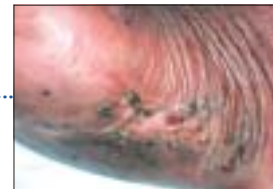

Xerosis and pityriasis alba-like changes associated with zonisamide

Feroze Kaliyadan, Jayasree Manoj, S. Venkitakrishnan..... 165

Treatment of actinomycetoma with combination of rifampicin and co-trimoxazole

Rajiv Joshi 166



Author's reply

M. Ramam, Radhakrishna Bhat, Taru Garg, Vinod K. Sharma, R. Ray, M. K. Singh, U. Banerjee, C. Rajendran 168

Vitiligo, psoriasis and imiquimod: Fitting all into the same pathway

Bell Raj Eapen 169

Author's reply

Engin Şenel, Deniz Seçkin 169

Multiple dermatofibromas on face treated with carbon dioxide laser: The importance of laser parameters

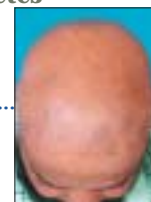Kabir Sardana, Vijay K. Garg 170

Author's reply

D. S. Krupa Shankar, A. Kushalappa, K. S. Uma, Anjay A. Pai..... 170

Alopecia areata progressing to totalis/universalis in non-insulin dependent diabetes mellitus (type II): Failure of dexamethasone-cyclophosphamide pulse therapy

Virendra N. Sehgal, Sambit N. Bhattacharya, Sonal Sharma, Govind Srivastava, Ashok K. Aggarwal 171



Subungual exostosis

Kamal Aggarwal, Sanjeev Gupta, Vijay Kumar Jain, Amit Mital, Sunita Gupta..... 173

Clinicohistopathological correlation of leprosy

Amrish N. Pandya, Hemali J. Tailor 174

RESIDENT'S PAGE

Dermatographism

Dipti Bhute, Bhavana Doshi, Sushil Pande, Sunanda Mahajan, Vidya Kharkar 177

FOCUS

Mycophenolate mofetil

Amar Surjushe, D. G. Saple 180

QUIZ

Multiple papules on the vulva

G. Raghu Rama Rao, R. Radha Rani, A. Amareswar, P. V. Krishnam
Raju, P. Raja Kumari, Y. Hari Kishan Kumar 185



E-IDVL

Net Study

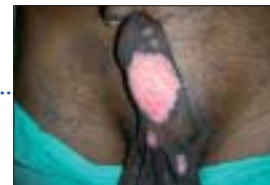Oral isotretinoin is as effective as a combination of oral isotretinoin and topical anti-acne agents in nodulocystic acne

Rajeev Dhir, Neetu P. Gehi, Reetu Agarwal, Yuvraj E. More 187

Net Case

Cutaneous diphtheria masquerading as a sexually transmitted disease

T. P. Vetrichevvel, Gajanan A. Pise, Kishan Kumar Agrawal,
Devinder Mohan Thappa 187



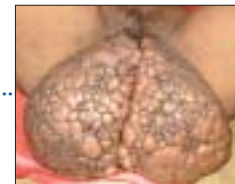Net Letters

Patch test in Behcet's disease

Ülker Gül, Müzeyyen Gönül, Seray Külcü Çakmak, Arzu Kılıç 187

Cerebriform elephantiasis of the vulva following tuberculous lymphadenitis

Surajit Nayak, Basanti Acharjya, Basanti Devi, Satyadarshi Pattnaik,
Manoj Kumar Patra 188



Net Quiz

Vesicles on the tongue

Saurabh Agarwal, Krishna Gopal, Binay Kumar 188



Multiple dermatofibromas on face treated with carbon dioxide laser: The importance of laser parameters

Sir,

Dermatofibroma (DF) is one of the common dermatologic diseases treated by practicing dermatologists.^[1] The use of carbon dioxide laser has emerged as an effective option for treatment of numerous epidermal and dermal dermatological lesions, including benign and malignant growths, keloids, vascular deformities, warts and tattoos.^[2] The focus has now shifted from continuous wave (CW) to super-pulse (SP) and now ultrapulse (UP) mode.^[3] The latter mode combines efficacy and minimal tissue damage and is preferred by most laser surgeons worldwide.^[3]

The case published^[4] highlights two concepts. One the use of CO₂ laser, and second its apparent beneficial effects on fibrosis. But surprisingly, no mention is made of some standard facts that are mandatory in laser article publications worldwide:^[3] the type of laser, the make, the mode used (CW, SP, UP), the sub-mode used (continuous, repeat, pulsed), the energy used (joules/cm²) and in most pulsed surgery - the total power (W), power/pulse (mJ), pulse width (in μ s), frequency (Hz) and pulse diameter.^[3]

Nowadays, it is routine to use a two-step procedure, first to debulk the tissue with CW mode and then to destroy the base with UP mode, with the end-point varying depending on the lesion to be treated.^[3] This use of UP mode ensures better cosmesis.^[3] Notwithstanding the high recurrence that is the norm in similar conditions with fibroblastic proliferation like keloids,^[3] it is heartening to note the decent results obtained by the authors.^[4] But, we were surprised to note that no mention was made of a previous study on 18 patients (20 lesions) with PDL where 15 of 20 lesions (75%) responded.^[5] With so little on the subject, a proper perspective was warranted in the article on whether PDL is superior to CO₂ or not.

Kabir Sardana, Vijay K. Garg

Department of Dermatology and STD, Maulana Azad Medical College,
New Delhi, India

Address for correspondence: Dr. Kabir Sardana, Sect. 28, 466,
Noida - 201 303, UP, India. E-mail: kabirjdv@gmail.com

REFERENCES

1. Sehgal VN, Sardana K, Khandpur S. Giant combined dermatofibroma with satellitosis. *Clin Exp Dermatol* 2004;29:147-9.
2. Hruza G. Lasers in dermatology: Laser treatment of warts and other epidermal and dermal lesions. *Dermatol Clin* 1997;15:487-505.
3. Willard RJ, Moody BR, Hruza GJ. Carbon dioxide and erbium: YAG laser ablation. Chapter 6, *In: Goldman MP, editor. Cutaneous and cosmetic laser surgery*. 1st ed. Elsevier Inc: 2006. p. 155-83.
4. Krupa Shankar DS, Kushalappa AA, Suma KS, Pai SA. Multiple dermatofibromas on face treated with carbon dioxide laser. *Indian J Dermatol Venereol Leprol* 2007;73:194-5.
5. Wang SQ, Lee PK. Treatment of dermatofibroma with a 600 nm pulsed dye laser. *Dermatol Surg* 2006;32:532-5.