

CAPILLARY HAEMANGIOMA

Alok Kumar Roy, Kalyan Chakravarty

A 16-year-old boy presented with a hyperpigmented, velvety, not compressible, plaque on the medial side of right leg just below the knee for the last 10 years. Biopsy report revealed the lesion was nothing but capillary haemangioma. The case is presented here due to unusual presentation with a tendency to persist.

Key Words : Capillary haemangioma, Unusual presentation

Introduction

Capillary haemangioma consists of one or several bright red, soft, lobulated tumours. They usually first appear between the third week and fifth week of life, increase in size for several months upto 1 year and then start to regress.¹ Complete spontaneous resolution is common but ultimately 6% of capillary haemangiomas constitute a cosmetic handicap.

Case Report

A 16-year-old Hindu male patient came to our out-patient department with the complaint of a hyperpigmented, velvety, plaque-like lesion on the medial side of right leg just below the knee which was present for the last 10 years. Initially the lesion was of the size of a pinhead and it gradually increased for the present size of 8 cmx5 cm. He gave the history of bleeding following trauma at the time he first noticed the lesion.

It was not associated with any history of pain but he complained of occasional pruritus. On examination, a well-defined, hyperpigmented lesion with sharp but irregular margin, firm in consistency with prominent skin markings was present. The

From the Department of Dermatology, RG Kar Medical College, Calcutta-700004, and Skin Clinic 883, Jessore Road, Calcutta-700055, India.

Address correspondence to : Dr Alok Kumar Roy F43/7, Karunamayee Housing Estate, Calcutta-700091.

lesion was not compressible. Routine examinations of blood, stool and urine were within normal limits. X-ray showed no bony involvement.

Histopathological examination revealed hypertrophic epidermis with hyperkeratosis and in mid-dermis and deep-dermis, newly formed capillaries were seen (Fig. 1),

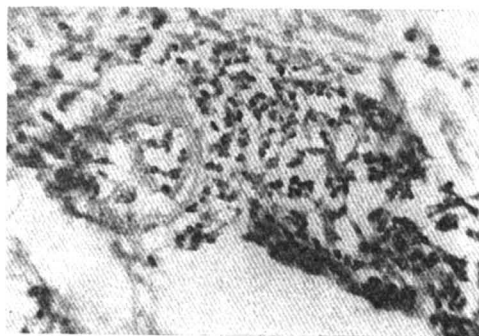


Fig. 1. Histopathological picture (H&Ex250).

consistent with the diagnosis of capillary haemangioma.

Discussion

Though complete resolution is common, ultimately 6% of capillary haemangioma constitute a cosmetic blemish.² Some authorities describe verrucous haemangioma as separate entity,³ but in our case histopathology was typical of capillary haemangioma. Verrucous appearance was not there and histopathological changes typical of verrucous haemangioma were also

not present in this case.^{4,5}

References

1. Lever WF, Lever GS. Histopathology of the skin. Philadelphia: J B Lippincott, 1990: 690.
2. Bowers RE, Graham EA, Tomlinson KA. The natural history of the strawberry nevus. Arch Dermatol 1960; 82: 667-80.
3. Imperial R, Helwig FB. Verrucous hemangioma. Arch Dermatol 1967; 89: 247-53.
4. Pavithran K. Verrucous haemangioma. Ind J Dermatol Venereol Leprol 1989; 55: 265.
5. Cyriac MJ, Zachariah J, Harilal KR. Verrucous hemangioma. Ind J Dermatol Venereol Leprol 1990; 56: 145.

OBITUARY

DR PRITI NAYAK



Death is the most inevitable event which happens with everyone in life. But there are few, who make their identity immortal. Dr Priti Nayak was one of them. The sun of her life rose on 27th October, 1955 and 27th June, 1996 marked the day of her sad demise.

Late Dr Priti Nayak was a versatile personality. She was an outstanding student, an efficient teacher, a good administrator, a loving and caring mother and a sincere wife. Apart from all these she was a poetess and a philosopher. She passed her MD degree in 1981. Later on, she joined as an Honorary Assistant Professor in L G Hospital and had worked as a Professor-in-Charge for more than 5 years. The 24th National Conference of I A D V L held at Ahmedabad was a good success owing to a major contribution by her who was the Exhibition Committee Chairperson.

Her Sudden demise is not only a great loss for her family, parents and friends but also for the society and nation. There are only few souls who glitter like stars in the universe and no doubt our beloved late Dr Priti Nayak is now one of the glittering stars. We all pray to the God that her soul may rest in peace.