

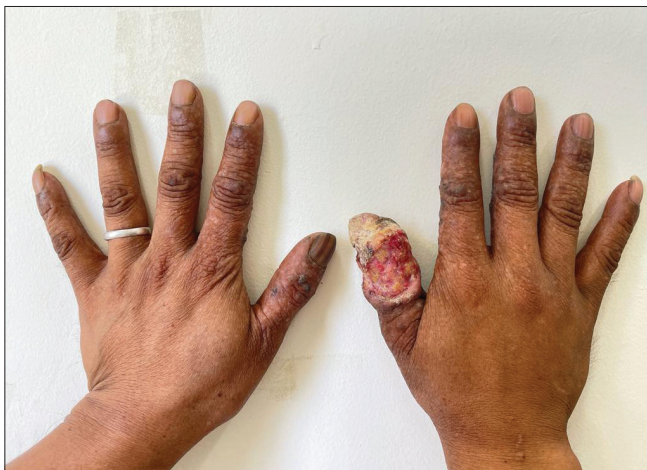# Synergistic effect of long-standing exposure to X-ray and developer solution in the causation of squamous cell carcinoma of right thumb: A case report

Dear Editor,

X-ray is an indispensable diagnostic imaging tool with multiple indications. Being an ionising radiation, X-rays are carcinogenic. We report a case of squamous cell carcinoma (SCC) of the right thumb in a radiographic technician who exposed his hands to the X-ray and developer solution for a prolonged period.

A 45-year-old male, X-ray technician by occupation, presented with a non-healing ulcer on his right thumb of 5 years' duration. He was treated elsewhere with multiple courses of antibiotics and antiseptic wound dressing without appreciable improvement. On enquiring, he revealed dipping of his right hand into the X-ray developer solution several times daily for 20 years. He also exposed his right hand frequently to the X-ray beam to hold the film while performing dental radiography. He has been performing about ten dental radiographic imaging daily for the past 20 years. He has no past or family history of cutaneous malignancies.

On examination, there was a single ulcero-proliferative lesion involving his dorsal right thumb extending from the hyponychium until 2 cm distal to the metacarpophalangeal joint. There was onychia and an increased girth of the



**Figure 1:** Ulcer involving dorsum of right thumb with indurated rolled out borders.

right thumb. Poikilodermatous changes involved his palms and fingers, while hyperpigmented keratotic lesions affected the palms. Poikiloderma and keratotic lesions were more prominent over the right hand. X-ray of the right hand showed resorption of the terminal thumb phalanx [Figure 1]. A single enlarged lymph node was palpable in the right axillary region (central group) which was mobile, firm, and non-tender.

A biopsy from the ulcer margin confirmed the clinical diagnosis of SCC. Biopsy of the palmar keratotic lesion revealed hyperkeratosis, and parakeratosis without any neoplasia. Fine Needle Aspiration Cytology (FNAC) from the enlarged right axillary lymph node revealed reactive lymphoid hyperplasia. A thorough systemic workup ruled out systemic metastasis. Under general anaesthesia, amputation of the right thumb was performed at the level of metacarpophalangeal joint and complemented the defect with flap coverage. Dissection of the level 1 and level 2 axillary lymph nodes (except Rotter's lymph nodes) and the adjoining fibro-fatty tissue was performed in the same sitting [Figure 2]. Histologic examination of the amputated specimen revealed moderately differentiated SCC with surrounding dense desmoplastic reaction and lympho-vascular invasion. [Figure 3] Tumour deposits were observed in 2 of the 39 dissected axillary lymph nodes. Adjuvant chemotherapy is being planned for the patient.

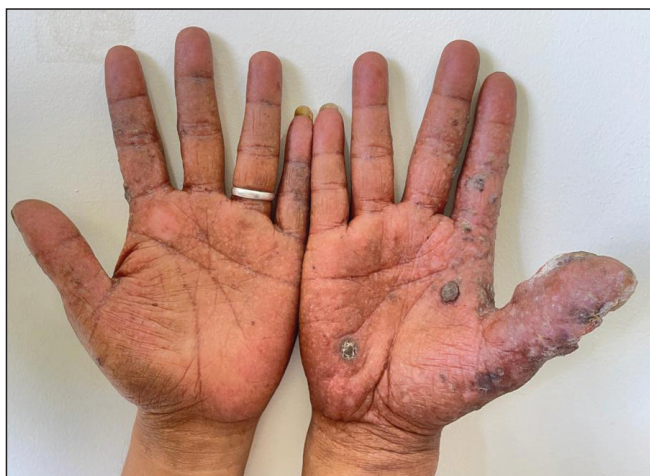X-ray, being an ionising radiation, can induce double-stranded breaks in the cellular DNA which can progress to carcinoma in the absence of repair or apoptosis.<sup>1</sup> The reported patient has been holding periapical film with his hands (right > left) for more than 20 years while performing dental radiography, and exposing his hands to 300 mA X-ray beam. As per guidelines of the International Commission on Radiological Protection (ICRP), cumulative X-ray exposure should be less than 50 mSv per year and less than 100 mSv in 5 consecutive years.<sup>2</sup> The X-ray exposure in the present case during each exposure was 0.2 mSv. Thus, the cumulative exposure amounted to 600 mSv per year and 3000 mSv in five consecutive years which greatly exceeds the recommended safety limit.

**How to cite this article:** Chenkual S, Laldinthari C, Balasubramanian P, Lalhruaizela S, Lalhruaitluanga L, Zote Z, *et al.* Synergistic effect of long standing exposure to X-ray and developer solution in the causation of squamous cell carcinoma of right thumb: A case report. *Indian J Dermatol Venereol Leprol.* 2024;90:650-1. doi: 10.25259/IJDVL\_120\_2023

**Received:** February, 2023 **Accepted:** November, 2023 **Epub Ahead of Print:** April, 2024 **Published:** August, 2024

**DOI:** 10.25259/IJDVL\_120\_2023 **PMID:** 38594981

This is an open-access article distributed under the terms of the Creative Commons Attribution-Non Commercial-Share Alike 4.0 License, which allows others to remix, tweak, and build upon the work non-commercially, as long as the author is credited and the new creations are licensed under the identical terms.



**Figure 2:** Poikiloderma and hyperkeratotic lesions involving the palms (more on the right hand side).

The patient also immersed his bare right hand into the developer solution frequently for 20 years. The X-ray developer solution contains hydroquinone and its carcinogenic potential is evident through previous reports of SCC on the face following its usage as a bleaching agent.<sup>3</sup> Apart from the present case, there is a single report, describing SCC involving the right thumb in a radiographic technician due to occupational exposure.<sup>4</sup>

The radiation emitted by the dedicated dental X-ray machine being used widely is 0.005 mSv per exposure which is much less than the radiation emitted by the 300-mA machine used by our patient.<sup>5</sup> The usage of intra-oral film holders will also prevent X-ray exposure to the radiographer's hands.

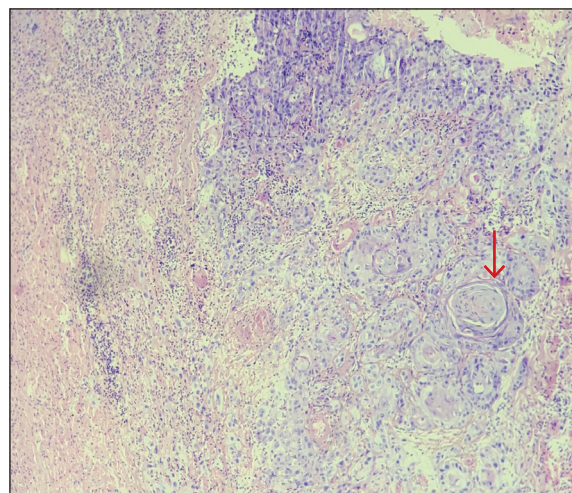
We report this case of occupational SCC caused by prolonged exposure of hands to X-ray. Hydroquinone in the developer fluid may be an additional contributor for carcinogenicity. Our case emphasises the importance of strict adherence to the radiation protection guidelines while performing the radiographic procedures.

**Declaration of patient consent:** The authors certify that they have obtained all appropriate patient consent.

**Financial support and sponsorship:** Nil.

**Conflicts of interest:** There are no conflicts of interest.

**Use of artificial intelligence (AI)-assisted technology for manuscript preparation:** The authors confirm that there was no use of artificial intelligence (AI)-assisted technology for assisting in the writing or editing of the manuscript and no images were manipulated using AI.



**Figure 3:** Histological examination showing atypical keratinocytes with prominent mitotic activity. Multiple keratin pearls (Red arrow) and areas of necrosis are also seen (Haematoxylin and Eosin; 100x).

**Saia Chenkual, Chhakchhuak Laldinthari<sup>1</sup>,  
Pradeep Balasubramanian<sup>1</sup>, Samuel Lalhrui<sup>2</sup>,  
Lalhrui Luanga Lalhrui Luanga,  
Zothansangi Zote<sup>2</sup>, Hmingthanzuali Ralte<sup>2</sup>,  
Wendy L Ralte<sup>3</sup>, C Lalhlanzovi<sup>2</sup>,  
Robert Lalnunpuia<sup>1</sup>**

Departments of Surgery, <sup>1</sup>Dermatology, <sup>2</sup>Pathology, <sup>3</sup>Radio-Diagnosis,  
Zoram Medical College, Falkawn, Aizawl, India

**Corresponding author:**

Dr. Pradeep Balasubramanian,  
Department of Dermatology, Zoram Medical College,  
Falkawn, Aizawl, India.  
drprady85@gmail.com

## References

1. Pauwels EK, Foray N, Bourguignon MH. Breast Cancer Induced by X-Ray Mammography Screening? A review based on recent understanding of low-dose radiobiology. *Med Princ Pract* 2016;25:101–9.
2. The 2007 Recommendations of the International Commission on Radiological Protection. ICRP publication 103. *Ann ICRP* 2007;37:1–332.
3. Ly F, Dioussé P, Ndiaye C, Déme A, Diatta BA, Ndiaye MT. Cutaneous squamous cell carcinomas (SCC) associated with cosmetic skin whitening: 8 cases reported in Senegal. *Ann Dermatol Venereol* 2018;145:83–8.
4. Halboub ES, Barnkgkei I, Alsabbagh O, Hamadah O. Radiation-induced thumbs carcinoma due to practicing dental X-ray. *Contemp Clin Dent* 2015;6:116–8.
5. <https://www.radiologyinfo.org/en/info/safety-xray> [cited 2023 Jan 12].