

Therapy Letters

Extensive and refractory genital herpes in human immunodeficiency virus-infected patient successfully treated with imiquimod: Case report and literature review

Sir,

Herpes genitalis is the most common sexually transmitted disease worldwide. Its incidence has been increasing, especially among positive human immunodeficiency virus patients.¹ The typical presentations of cutaneous herpes simplex virus are well known and rarely cause diagnostic difficulty. However, in patients with advanced human immunodeficiency virus infection, unusual and severe manifestations of herpes simplex virus infection are common and are included among the opportunistic processes that define the acquired immunodeficiency syndrome.² The unusual clinical presentations increasingly observed in clinical practice have led to the use of new treatment modalities such as immunomodulatory agents, in particular topical imiquimod cream as an adjunctive therapy to the first-line drug acyclovir with satisfactory results.¹ Our case report describes a human immunodeficiency virus-infected man with a herpetic infection that was refractory to acyclovir but not to imiquimod, followed by literature review of similar cases.

A 54-year-old human immunodeficiency virus-infected man presented with a 5-month history of painful penile erosions. Physical examination revealed extensive herpetiform erosions involving the penis [Figure 1a]. His CD4 cell count was 299/ μ L and his viral load was undetectable. He had been receiving antiretroviral therapy and had no previous history of genital herpes infection. He had already been treated in a primary health-care unit with acyclovir (4 g daily), penicillin and azithromycin with no improvement. Results of blood tests were positive for syphilis (venereal disease research laboratory 1:32; fluorescent treponemal antibody-absorption positive) and herpes simplex virus (immunoglobulin M negative; immunoglobulin G positive), cytomegalovirus (immunoglobulin M negative;

immunoglobulin G positive) and chlamydia (immunoglobulin M negative; immunoglobulin G positive). Skin biopsy was inconclusive. The patient was hospitalized and began empiric treatment with crystalline penicillin and intravenous acyclovir (800 mg three times daily) for 15 days due to oral acyclovir refractory herpes simplex. He was discharged with partially improved but still unhealed genital ulcers.

A second skin biopsy revealed typical herpes inclusions and multinucleated giant cells and immunohistochemical studies supported the diagnosis of herpes simplex virus 1 and 2 infections [Figure 2a and b]. Subsequently, the patient was treated initially with famciclovir (500 mg two times daily for 8 weeks), but due to high medication cost, it was changed back to acyclovir (400 mg six times daily for 12 weeks). Despite these multiple treatment attempts, he experienced no clinical improvement. The patient was given a trial regimen of topical 5% imiquimod cream applied three times/week for 8 weeks and then five times/week, together with oral acyclovir (400 mg three times daily), for 16 weeks. Complete healing of the lesions was achieved after treatment was completed [Figure 1b].

Herpes simplex virus infections are exceedingly common and pose a particular problem in immunocompromised patients. They may experience an excessive number and size of lesions in both primary and reactivated herpes simplex virus infections in comparison with immunocompetent patients. As CD4 cell counts drop and immunosuppression worsens, recurrent episodes increase in frequency and severity until there is no period of complete healing between episodes. Nonhealing ulcers of the genital region in immunocompromised patients should elicit a high degree of

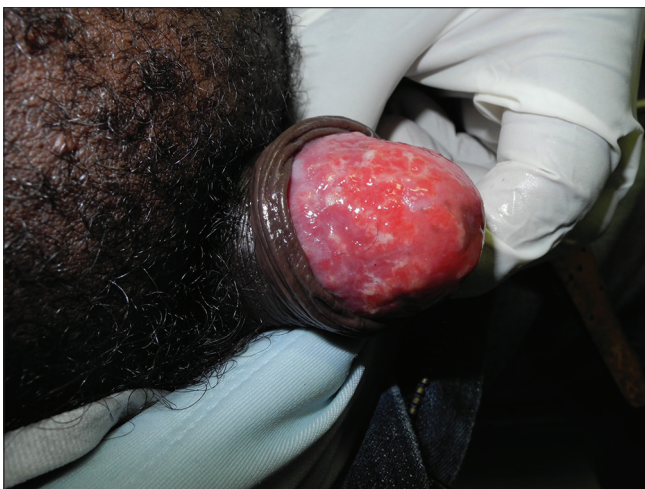

Figure 1a: Genital penile erosions before treatment

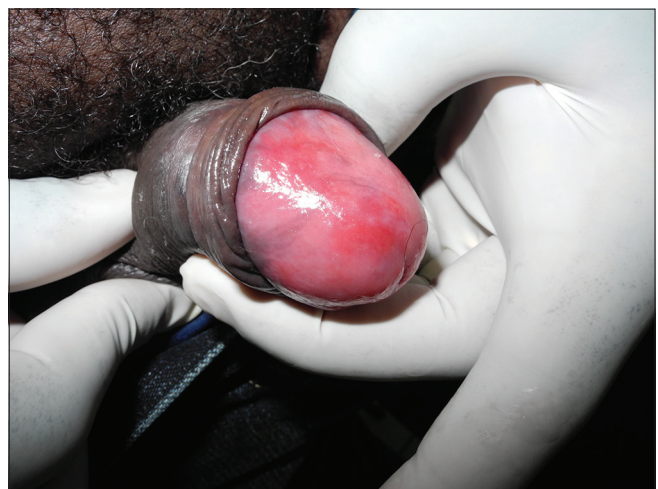

Figure 1b: Clinical result after imiquimod therapy

Table 1: Results after use of imiquimod in antiviral-resistant cases

Author/year	Age/gender	CD4 (mm ³)/CV (copies/ml)	HAART	Area	Treatment	Outcome
Gilbert <i>et al.</i> /2001*	34/male	N/A†	N/A	N/A	Imiquimod	Resolution
Danielson <i>et al.</i> /2002*	28/male	N/A	N/A	N/A	Imiquimod	Resolution
Martinez <i>et al.</i> /2006*	37/male	N/A	N/A	N/A	Imiquimod	Resolution
Abbo <i>et al.</i> /2007*	42/male	N/A	N/A	N/A	Imiquimod	Resolution
Yudin and Kaul/2008 ⁷	34/female	156/>100,000	Yes	Vulva	Valacyclovir Foscarnet Imiquimod	No response No response Resolution
Lautenschlager <i>et al.</i> /2008*	46/male	N/A	N/A	N/A	Imiquimod	Resolution (several recurrences)
Lestre <i>et al.</i> /2011*	49/female	197/32,000	Yes	Perineal	Acyclovir Valacyclovir Imiquimod	No response No response Resolution
Barbosa <i>et al.</i> /2011*	42/male	150/N/A	Yes	Scrotum	Acyclovir Valacyclovir + imiquimod	No response Resolution
Perkins <i>et al.</i> /2011 ⁸	45/male	315/undetectable	Yes	N/A	Acyclovir + imiquimod	Resolution
	45/female	239/undetectable	Yes	Vulvar	Acyclovir Imiquimod	No response Resolution (four recurrences)
	78/male	HIV-/B-cell lymphoma	-	Perianal	Acyclovir Foscarnet Imiquimod	No response Recurrence Resolution
Lascaux <i>et al.</i> /2012 ⁹	42/male	654/18 Log			Acyclovir Imiquimod	No response Resolution
	42/male	414/<17 Log	Yes	Scrotum	Acyclovir Foscarnet Imiquimod	No response No response Resolution
	32/male	10/453 Log	No	Scrotum	Valacyclovir Foscarnet Imiquimod	No response No response Resolution
	45/male	N/A	No	Anal	Acyclovir Foscarnet Imiquimod	No response No response Resolution (recurrence in 1 year)
55/male	130/<17 Log	No	Genital	Foscarnet Imiquimod	Resolution (recurrence) Resolution	
Strehl <i>et al.</i> /2012*	44/female	N/A	N/A	N/A	Imiquimod	Resolution (3 recurrences)
Tangjitgamol <i>et al.</i> /2014 ¹⁰	51/female	262/N/A	Yes	Perineal	Valacyclovir Acyclovir Imiquimod	No response No response Resolution
Leeyaphan <i>et al.</i> /2015	55/male	N/A	N/A	N/A	Imiquimod	Resolution
	35/female				Imiquimod	Resolution
	37/female				Imiquimod	Resolution
	35/male				Imiquimod	Resolution
	40/female				Imiquimod	Resolution
50/female				Imiquimod	Resolution (recurrence in 1 year)	
Deza <i>et al.</i> /2015 ¹¹	45/male	232/126	Yes	Genital	Valacyclovir Acyclovir Imiquimod	No response No response Resolution
Present case/2015	54/male	299/undetectable	Yes	Penis	Acyclovir Famciclovir Acyclovir + imiquimod	No response No response Resolution

*Data available at reference 1, †N/A: Information not available. HAART: Highly active antiretroviral therapy, HIV: Human immunodeficiency virus

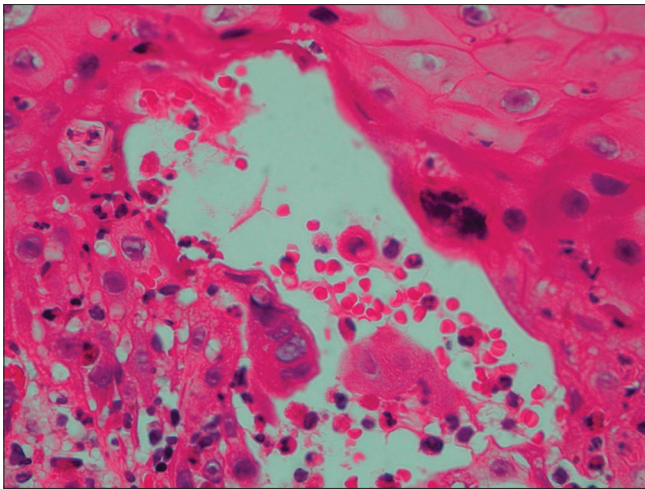


Figure 2a: Multinucleated giant cells with viral nuclear inclusions and nuclear molding (H and E, ×400)

suspicion of chronic herpes simplex virus infection. Chronic herpes simplex virus ulcer of more than 1 month duration is an acquired immunodeficiency syndrome-defining illness in human immunodeficiency virus-infected patients.³

Treatment with antivirals such as acyclovir is still the mainstay of prescribed therapy. For the treatment of recurrent episodes, the use of antivirals can reduce the time of healing, time of cessation of viral shedding and duration of symptoms.¹ Increased dosages of acyclovir, valacyclovir and famciclovir may be required.³

The emergence of drug-resistant herpesvirus strains is associated with the increase in the use of acyclovir.⁴ Foscarnet sodium has been the drug of choice in cases of acyclovir resistance. However, it has also been associated with drug-resistant strains that replicate despite drug presence.⁵ Success with topical imiquimod in cases of nonhuman immunodeficiency virus-associated recurrent genital herpes simplex virus infection with documented acyclovir resistance was reported.⁶ Topical imiquimod is an immunomodulatory drug that signals through toll-like receptors 7 to stimulate cell-mediated immune responses, showing promising results for the treatment of herpes simplex virus infection and in atypical cases, studies showed that imiquimod provides an added benefit.¹ Therefore, imiquimod presents itself as a valuable ally when treating acyclovir refractory herpes simplex virus infections, particularly in the setting of emerging resistance.

Literature review indicated that despite antiviral resistance, treatment with imiquimod has been successful [Table 1]. Data on 25 patients from 14 different studies showed that clinical cure was the main result with only some instances of recurrences ($n = 5$) after topical 5% imiquimod therapy.

Our patient failed to respond to classic acyclovir monotherapy, showing a great response after the addition of topical imiquimod cream. Imiquimod may be considered as a possible adjuvant therapy in resistant genital herpes simplex virus infections in light of our experience with this difficult case.

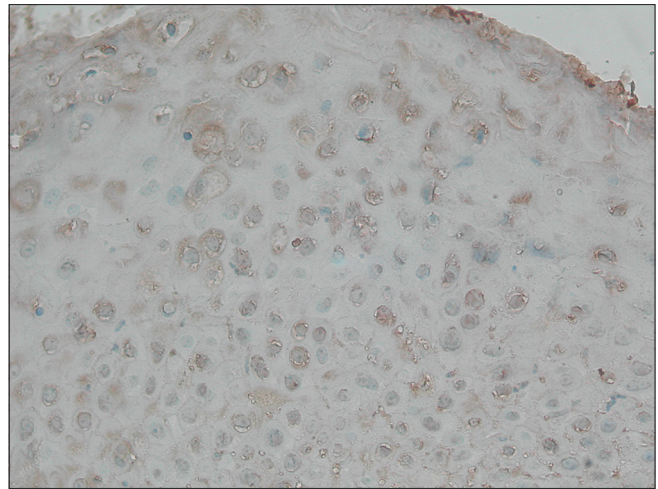


Figure 2b: Immunohistochemical study (×400) positive for herpes simplex virus

Financial support and sponsorship
Nil.

Conflicts of interest
There are no conflicts of interest.

**Helena Reich Camasmie, Caroline Barbosa,
Omar Lupi, Ricardo Barbosa Lima, Marcio Serra,
Antonio Macedo D’Acri, Carlos José Martins**

Dermatology Department, Gaffree and Guinle University Hospital,
Federal University of the State of Rio de Janeiro, Rio de Janeiro, Brazil

Correspondence: Dr. Helena Reich Camasmie,
Rua Mariz e Barros, 775, Tijuca, 20270-002
Rio de Janeiro, Brazil.
E-mail: helena@camasmie.com

References

1. Leeyaphan C, Surawan TM, Chirachanakul P, Prasertworonun N, Punyaratabandhu P, Omcharoen V, *et al.* Clinical characteristics of hypertrophic herpes simplex genitalis and treatment outcomes of imiquimod: A retrospective observational study. *Int J Infect Dis* 2015;33:165-70.
2. Abbo L, Vincek V, Dickinson G, Shrestha N, Doblecki S, Haslett PA. Selective defect in plasmacytoid dendritic cell function in a patient with AIDS-associated atypical genital herpes simplex vegetans treated with imiquimod. *Clin Infect Dis* 2007;44:e25-7.
3. Carrasco DA, Trizna Z, Colome-Grimmer M, Tyring SK. Verrucous herpes of the scrotum in a human immunodeficiency virus-positive man: Case report and review of the literature. *J Eur Acad Dermatol Venereol* 2002;16:511-5.
4. Gilbert J, Drehs MM, Weinberg JM. Topical imiquimod for acyclovir-unresponsive herpes simplex virus 2 infection. *Arch Dermatol* 2001;137:1015-7.
5. Sauder DN. Immunomodulatory and pharmacologic properties of imiquimod. *J Am Acad Dermatol* 2000;43(1 Pt 2):S6-11.
6. Brummitt CF. Imiquimod 5% cream for the treatment of recurrent, acyclovir-resistant genital herpes. *Clin Infect Dis* 2006;42:575.

7. Yudin MH, Kaul R. Progressive hypertrophic genital herpes in an HIV-infected woman despite immune recovery on antiretroviral therapy. *Infect Dis Obstet Gynecol* 2008;2008:592532.
8. Perkins N, Nisbet M, Thomas M. Topical imiquimod treatment of aciclovir-resistant herpes simplex disease: Case series and literature review. *Sex Transm Infect* 2011;87:292-5.
9. Lascaux AS, Caumes E, Deback C, Melica G, Challine D, Agut H, *et al.* Successful treatment of aciclovir and foscarnet resistant herpes simplex virus lesions with topical imiquimod in patients infected with human immunodeficiency virus type 1. *J Med Virol* 2012;84:194-7.
10. Tangjitgamol S, Loharamtaweethong K, Thawaramara T, Chanpanitkitchot S. Vulvar pseudoepitheliomatous hyperplasia associated with herpes simplex virus type II mimicking cancer in an immunocompromised patient. *J Obstet Gynaecol Res* 2014;40:255-8.
11. Deza G, Martin-Ezquerria G, Curto-Barredo L, Villar García J, Pujol RM. Successful treatment of hypertrophic herpes simplex genitalis in HIV-infected patient with topical imiquimod. *J Dermatol* 2015;42:1176-8.

This is an open access article distributed under the terms of the Creative Commons Attribution-NonCommercial-ShareAlike 3.0 License, which allows others to remix, tweak, and build upon the work non-commercially, as long as the author is credited and the new creations are licensed under the identical terms.

Access this article online	
Quick Response Code:	Website: www.ijdv.com
	DOI: 10.4103/0378-6323.199423

How to cite this article: Camasmie HR, Barbosa C, Lupi O, Lima RB, Serra M, D'Acri AM, *et al.* Extensive and refractory genital herpes in human immunodeficiency virus-infected patient successfully treated with imiquimod: Case report and literature review. *Indian J Dermatol Venereol Leprol* 2017;83:256-9.

Received: August, 2016. **Accepted:** August, 2016.

© 2017 Indian Journal of Dermatology, Venereology, and Leprology | Published by Wolters Kluwer - Medknow