

## SEXUALLY INDUCED PENILE OEDEMA

PM Abdul Gaffoor

A case of penile oedema following a prolonged sexual intercourse is discussed.

**Key Words :** Penile oedema, Prolonged sex

### Introduction

Penile oedema can be caused by several reasons, both sexual and nonsexual causes. Because of the genital area any lesion whether sexually or nonsexually induced can cause a lot of psychological trauma to the patient. Because of psychosexual impact a good doctor patient relationship is required to have good understanding of the condition and prompt management.

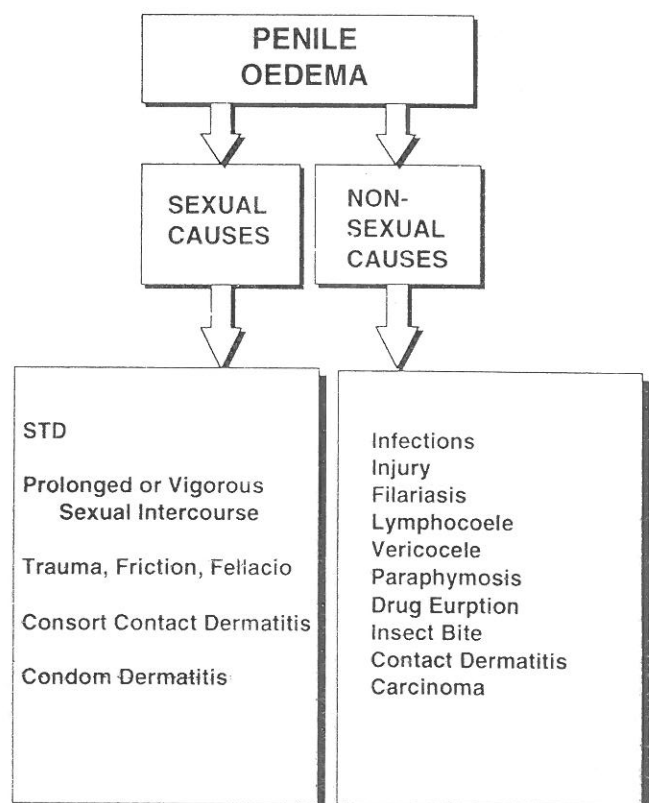
### Case Report

A male patient, 38-year-old, attended the clinic with marked oedema of the shaft of the penis, extending to the corona of the glans penis following a prolonged sexual intercourse. As the patient had no other genital lesions except oedema, patient was reassured and discussed about the condition. The oedema subsided quickly without any treatment.

### Comments

"Penile venereal oedema" occurs within a few hours of intercourse and affect shaft and mucosal surface of the prepuce of the circumcised patients.<sup>1</sup> Penile oedema sometimes occurs after a vigorous or prolonged sexual activity. Thickening of the preputial remnant is prominent and a cord like thickening of the lymphatics around the corona is often present.<sup>2</sup> Such oedema is quite often seen in circumcised men. Penile oedema

develops several hours after repeated vigorous intercourse with a passive partner and no treatment is needed.<sup>3</sup> A female partner with less vaginal fluid or a noncooperative partner can induce penile oedema because of genital friction or trauma that may produce during sexual activity. "Saxophone" like penile oedema due to contact dermatitis has been reported.<sup>4</sup> Manipulations of genitalia by self examinations by the patients because of "venereophobia" may sometimes result in penile oedema. Penile venereal oedema is a rare complication of chlamydial infection, gonorrhoea and perhaps nonchlamydial NGU, genital herpes and other infections.<sup>5</sup> The oedema of the penis can be due to sexual or nonsexual causes. The different causes for penile oedema are shown in Fig 1.



From the Department of Dermatology & Venereology, Hamad Medical Corporation, Doha, Qatar

Address correspondence to : Dr PM Abdul Gaffoor

The penile oedema is caused by several conditions. Sexually transmitted disease and sometimes even a normal sexual intercourse may result in sexually induced penile odema. Fixed drug eruptions of the male genitalia may sometimes cause genital oedema and may sometimes confuse with sexually transmitted diseases especially in sexually active patients. The male genitalia can be involved in various conditions resulting from bacterial, fungal, viral and parasitic diseases or by growths, cysts or manifestations of systemic conditions or extensions of other dermatidities.<sup>6</sup> Many of these may cause penile oedema.

### Acknowledgement

I would like to thank the secretarial assistance of Ms. Maria Illescas-Panasa, Medical Education Dept., Hamad Medical Corporation.

### References

1. Ive FA, Wilkinson DS. Diseases of the umbilical, perianal and genital region. In Textbook of Dermatology (Arthur Rook, DS Wilkinson, FJG Ebling, et al, eds). London: Blackwell Scientific, 1986; 3: 2182.
2. Oates JK. Dermatoses, balanoposthitis, vulvitis, Behcet's Syndrome and Peyronie's Disease. Sexually transmitted diseases (GW Csonka, JK Oates, eds), Bailliere Tindall, 1990; 403.
3. Henry Wilde. Penile venereal edema. Arch Dermatol 1973; 108: 263.
4. Abdul Gaffoor PM. Penile oedema. British Journal of Sexual Medicine 1987; 14: 132-4.
5. Hunter Handsfield H. Colour atlas and synopsis of sexually transmitted diseases. McGraw-Hill 1992; 130.
6. Abdul Gaffoor PM, George WM. Fixed drug eruptions occurring on the male genitalia. Cutis 1990; 45: 242-4.