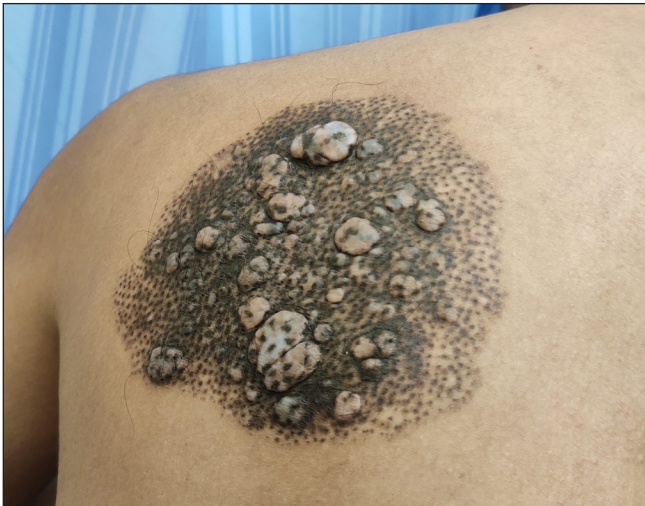

## A rare case of spotted grouped pigmented naevus: Congenital follicular melanocytic naevus

A 24-year-old man presented with a slow-growing, asymptomatic, 20-cm sized well-circumscribed lesion on his left upper back, consisting of several small, follicle-centred, discrete to coalescing, brownish-black to bluish macules. The lesion also demonstrated multiple, soft, well-circumscribed papules and nodules, with overlying follicular pigmentation. There was no hypertrichosis or underlying musculoskeletal defect [Figure 1].

Dermoscopy revealed follicle-centred brownish-black to bluish pigmentation in a reticulo-globular pattern, with intervening normal skin [Figure 2]. On histopathology, the dermis showed aggregates of uniform naevus cells surrounding the hair follicles along with abundant melanophages. Based on clinical features, dermoscopy, and histopathology, we diagnosed it as congenital follicular melanocytic naevus, also called spotted grouped pigmented naevus.



**Figure 1:** A well-circumscribed lesion on the back consisting of multiple brownish-black to bluish hyperpigmented macules and multiple soft well-circumscribed papules and nodules.



**Figure 2:** Dermoscopy showing follicle-centred brownish-black to bluish pigmentation with a reticulo-globular pattern and intervening normal skin (DermLite DL3N; contact, polarised, 10x).

**How to cite this article:** Singh V, Srivastava P, Sharma S, Khunger N. A rare case of spotted grouped pigmented naevus: Congenital follicular melanocytic naevus. *Indian J Dermatol Venereol Leprol.* 2025;91:128-9. doi: 10.25259/IJDVL\_1110\_2023

**Received:** October, 2023 **Accepted:** December, 2023 **Epub Ahead of Print:** March, 2024 **Published:** December, 2024

**DOI:** 10.25259/IJDVL\_1110\_2023 **PMID:** 38594984 **Supplementary file available on:** [https://doi.org/10.25259/IJDVL\\_1110\\_2023](https://doi.org/10.25259/IJDVL_1110_2023)



This is an open-access article distributed under the terms of the Creative Commons Attribution-Non Commercial-Share Alike 4.0 License, which allows others to remix, transform, and build upon the work non-commercially, as long as the author is credited and the new creations are licensed under the identical terms.

**Declaration of patient consent:** The authors certify that they have obtained all appropriate patient consent.

**Financial support and sponsorship:** Nil.

**Conflicts of interest:** There are no conflicts of interest.

**Use of artificial intelligence (AI)-assisted technology for manuscript preparation:** The authors confirm that there was no use of artificial intelligence (AI)-assisted technology for assisting in the writing or editing of the manuscript and no images were manipulated using AI.

***Vishvender Singh<sup>1</sup>, Prakhar Srivastava<sup>2</sup>,  
Shruti Sharma<sup>3</sup> , Niti Khunger<sup>1</sup> ***

<sup>1</sup>Department of Dermatology & STD, Vardhman Mahavir Medical College and Safdarjung Hospital, New Delhi,

<sup>2</sup>Department of Dermatology & STD, Vardhman Mahavir Medical College, Pandit Madan Mohan Malviya Hospital, New Delhi,

<sup>3</sup>Department of Pathology, ICMR National Institute of Pathology, Safdarjung Hospital Campus, New Delhi, India.

**Corresponding author:**

Dr. Vishvender Singh,  
Department of Dermatology & STD,  
Vardhman Mahavir Medical College and Safdarjung Hospital,  
New Delhi, India.  
vsyen22@gmail.com