

An atypical ear nodule

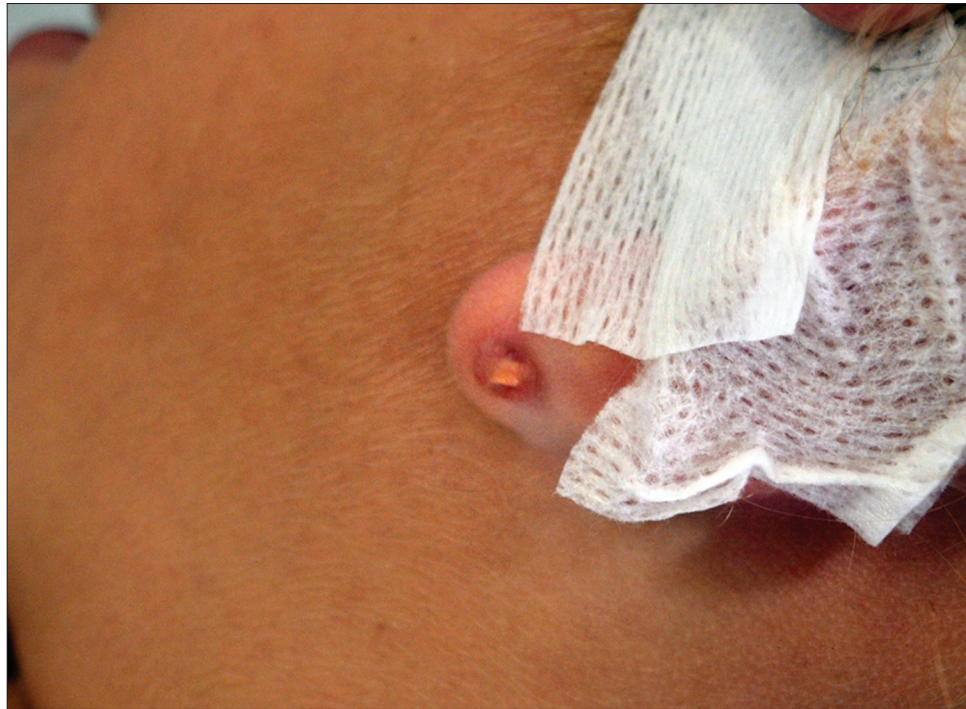

Figure 1: Clinical view of the nodule of left ear lobe

A six-year-old girl presented with a 10 months' history of a nodule on the left ear lobe. Examination revealed that there was a single very firm nodule of about 0.5 cm diameter behind the ear lobe. It was characterized by peripheral erythema and arborizing telangiectatic vessels [Figure 1]. Dermatoscopic evaluation revealed the presence of arborizing, branching and non-branching vessels radiating toward the center of a gold shiny background area; the vessels did not cross the center of the nodule [Figure 2]. The lesion was asymptomatic. The mother reported a previous occurrence of what seemed to be an infection following ear piercing with the spring-loaded gun technique. She also reported never having found the back of the earring again. After administration of a local anesthetic, the nodule was opened surgically. The back of a gold butterfly earring, completely embedded in the left ear lobe, was removed [Figure 3].

Declaration of patient consent

The authors certify that they have obtained all appropriate patient consent.

How to cite this article: Greco V, Napolitano M, Ruggiero A, Lauro W, Scalvenzi M, Patruno C. An atypical ear nodule. *Indian J Dermatol Venereol Leprol* 2022;88:564-5.

Received: April, 2020 **Accepted:** September, 2020 **Epub Ahead of Print:** May, 2021 **Published:** June, 2022

DOI: 10.25259/IJDVL_555_20 **PMID:** 34114427

This is an open-access article distributed under the terms of the Creative Commons Attribution-Non Commercial-Share Alike 4.0 License, which allows others to remix, transform, and build upon the work non-commercially, as long as the author is credited and the new creations are licensed under the identical terms.

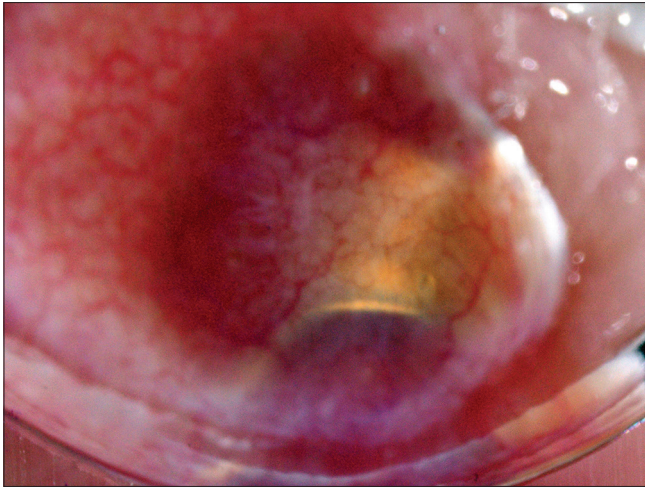


Figure 2: Dermatoscopic view of the nodule of left ear lobe

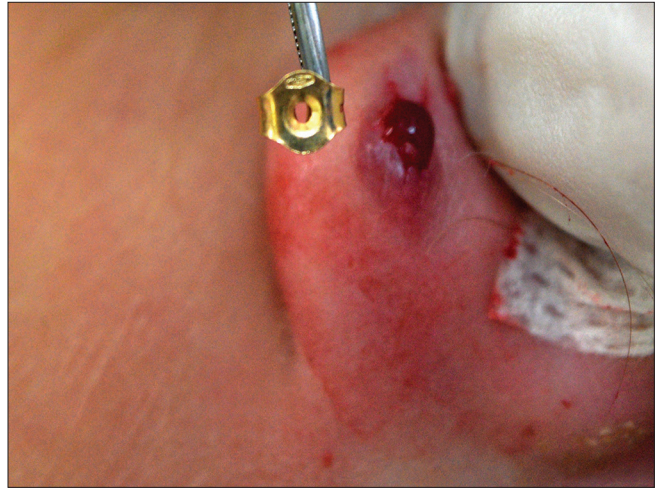


Figure 3: The removed back of a gold butterfly earring, that was completely embedded in the left ear lobe

Financial support and sponsorship

Nil.

Conflicts of interest

There are no conflicts of interest.

Vincenzo Greco, Maddalena Napolitano¹, Angelo Ruggiero, Wanda Lauro, Massimiliano Scalvenzi, Cataldo Patruno²

Department of Clinical Medicine and Surgery, Section of Dermatology, University of Naples Federico II, Naples, ¹Department of Medicine and Health Sciences Vincenzo Tiberio, University of Molise, Campobasso, ²Department of Health Sciences, University Magna Graecia of Catanzaro, Catanzaro, Italy

Corresponding author:

Dr. Angelo Ruggiero,
Department of Clinical Medicine and Surgery, Section of Dermatology, University of Naples Federico II, Naples, Italy.
angeloruggiero1993@libero.it