

NAEVUS COMEDONICUS ASSOCIATED WITH EPIDERMOID CYST

Deepak K Mathur, Puneet Bhargava, U S Agarwal, Sandeep K Mathur,
Ram Singh, Rishi Bhargava

Naevus comedonicus associated with epidermoid cyst is a rare association. Two such case reports are presented.

Key Words : Naevus comedonicus, Epidermoid cyst

Introduction

Naevus comedonicus is a developmental abnormality of the skin comprising of numerous keratin filled pits. It is generally assumed that they are of pilo-sebaceous origin though the presence of similar lesion on palm, soles and glans penis argues against this. Epidermoid cyst commonly affects young and middle aged person. It results either from inflammation of pilo-sebaceous follicles or from deep implantation of a fragment of epidermis by a blunt penetrating injury or due to developmental defect. Naevus comedonicus associated with epidermoid cyst is rare.

Case Reports

Case 1: A 21-year-old Hindu male presented with naevus comedonicus over the right anterior chest wall, right axillae, right arm and right forearm (Fig.1) He had multiple nodular swellings scattered within the area of naevus over right arm and forearm in which some were infected and showed pus discharge. Needle aspiration of one of the intact swelling revealed watery content but biopsy revealed it to be consistent with epidermoid cyst (Fig.2). No other systemic abnormality could be detected.

Case 2: A 19-year old student presented with naevus comedonicus over left

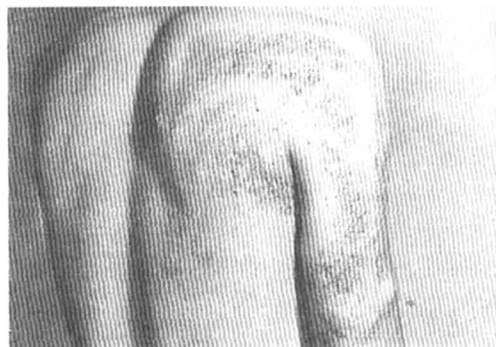


Fig. 1. Case 1.

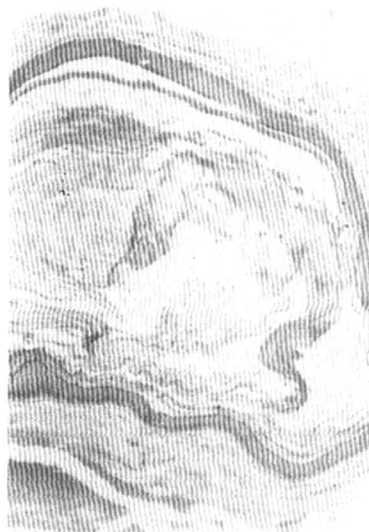

Fig. 2. Histopathology from one of the intact swellings showing epidermoid cyst.

From the Department of Dermatology, SMS
Medical College, Jaipur, India.

Address correspondence to : Dr Rishi Bhargava

side of the neck reaching upto the left sternoclavicular joint with swellings along with the naevus. Histopathological examination of the swellings confirmed them to be epidermoid cysts.

Discussion

There are reports of naevus comedonicus associated with other skin conditions like ichthyosis,¹ linear basal cell naevus,² cataract,³ absence of fifth finger⁴ and trichilemmal cyst.⁵ Association of naevus comedonicus with epidermoid cyst is quite rare and hence presented.

References

1. Piers F. Linear comedo naevus and ichthyosis. *Br J Dermatol* 1945; 57: 138-47.
 2. Carney RG. Linear unilateral basal cell nevus with comedones: report of a case. *Arch Dermatol Syphilol* 1952; 65: 471-6.
 3. Whyte HJ. Unilateral comedo nevus and cataract. *Arch Dermatol* 1968; 97: 533-5.
 4. Schneider C. Ein Bertaag zur Klinik des naevus-comedonicus. *Hautarzt* 1975; 26: 153-4.
 5. Leppard BJ. Trichilemmal cysts arising in an extensive comedo naevus. *Br J Dermatol* 1977; 96: 545-8.
-