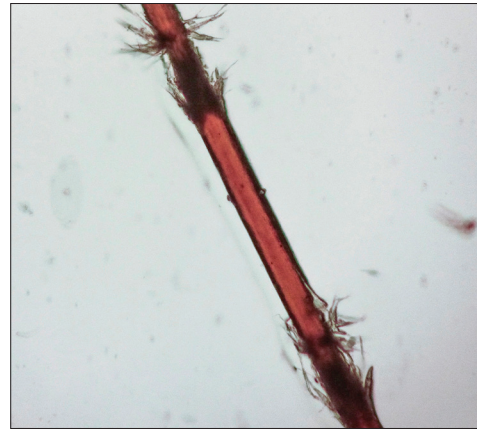


# Trichorrhexis nodosa due to repetitive trivial trauma



**Figure 1a:** Trichoscopy showing intermittent nodes along hair shaft (Mode – non polarised hand held, magnification – 10x, make – Heine Delta 20)



**Figure 1b:** Light microscopy showing fraying of cortical fibers giving the appearance of two paint brushes thrust together (400x)

Trichorrhexis nodosa is a hair shaft disorder which can be congenital or acquired. As seen in our case, repeated trivial trauma due to frequent combing can lead to the formation of trichorrhexis nodosa. Careful history taking and simple examination can avoid unnecessary tests and can diagnose this condition. Clinical examination revealed firmly attached, white nodular thickening on the distal part of the hair shaft. Trichoscopy showed glistening nodes along the length of hair shaft with whitish contours of the splitting fibers [Figure 1a]. Light microscopy showed fraying of cortical fibers giving the appearance of two paint brushes thrust together [Figure 1b].

### Financial support and sponsorship

Nil.

### Conflicts of interest

There are no conflicts of interest.

**Ameet L. Dandale, Sujit J. S. Shanshanwal, Prasad R. Wankhede, Rachita S. Dhurat**

Department of Dermatology, Lokmanya Tilak Municipal General Hospital, Sion Hospital, Mumbai, Maharashtra, India

**Correspondence:** Dr. Sujit J.S. Shanshanwal,

Department of Dermatology, OPD 16, 2<sup>nd</sup> Floor, New OPD Building, Lokmanya Tilak Municipal General Hospital, Sion Hospital, Mumbai, Maharashtra, India.

E-mail: shanshanwal.sujit@gmail.com

### Access this article online

#### Quick Response Code:



#### Website:

www.ijdvl.com

#### DOI:

10.4103/ijdvl.IJDVL\_45\_16

This is an open access article distributed under the terms of the Creative Commons Attribution-NonCommercial-ShareAlike 3.0 License, which allows others to remix, tweak, and build upon the work non-commercially, as long as the author is credited and the new creations are licensed under the identical terms.

**For reprints contact:** reprints@medknow.com

**How to cite this article:** Dandale AL, Shanshanwal SJ, Wankhede PR, Dhurat RS. Trichorrhexis nodosa due to repetitive trivial trauma. Indian J Dermatol Venereol Leprol 2017;83:683.

**Received:** February, 2016. **Accepted:** July, 2016.