

ANAL GIANT LICHENIFICATION SIMULATING SQUAMOUS CELL CARCINOMA

A 55-year-old male with chronic pruritus ani was found to have a cauliflower-like, irregular growth in the anal canal. Clinically, carcinoma of the anus was suspected but histopathological study of the biopsy taken from the growth revealed marked hyperkeratosis, parakeratosis, acanthosis with elongation of the rete ridges, slight spongiosis, elongation and broadening of the papillae and a dense perivascular inflammatory cell infiltrate in the dermis consisting of lymphocytes, histiocytes and fibroblasts. There was no vacuolation of the epidermal cells. The case was later seen by us and a detailed history revealed that the patient had been getting sudden explosive paroxysms of violent itching inside the anal canal since the last 3 years and he used to introduce the whole length of his right index finger into the anal canal 3 to 4 times daily and scratch the walls of the anal canal till he felt some pain locally. He denied history of homosexual or practice of sodomy. Examination of the perianal and genital areas was normal. There was no significant lymphadenopathy in the groin. Per rectal examination revealed a firm, irregular, non-tender mass on the posterior and the lateral walls of the anatomical anal canal. Prostate was felt normal. Proctoscopy (Fig. 1) revealed a whitish, firm, irregular growth with an excoriated surface on the posterior and lateral walls of the anal canal below the dentate line. The anal orifice, dentate line and the surgical anal canal appeared normal. Routine laboratory tests on blood, urine and stools were normal. Blood VDRL was negative. A psychiatric evaluation revealed sexual inadequacy in the patient and he used to get a form of sexual pleasure by introducing his right index finger and scratching the anal canal. He was treated with tranquillizers, Sitz bath with warm saline and topical corticosteroid ointment. After 3 months, the size of the lesion had diminished by about 50% and he was better.

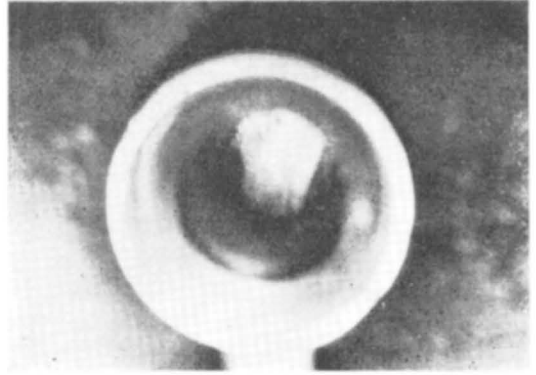


Fig. 1. Proctoscopy showing a whitish verrucous intra-anal growth.

Neurodermatitis (lichen simplex chronicus), usually presents as a pruritic circumscribed lichenified plaque. It has a predilection for the back and the sides of the neck and extremities especially the ankle and the wrist. Giant lichenification seen in elderly persons, appears as large, indurated, pruritic, tumour-like masses on the buttocks, groin and axilla. Neurodermatitis developing on the perianal skin, due to psychogenic causes is not uncommon. But development of giant lichenification inside the anal canal as observed in our patient is quite unusual. The hyperkeratotic mass that developed in the anal mucosa in our patient simulated a carcinomatous growth. The anal area is a site of eroticism. The wall of the anal canal below the dentate line is only a modified skin. Though it lacks cutaneous appendages, it is innervated by the spinal nerves thereby retaining the sensation of itch. This report is to stress the importance of taking a detailed case history and examining the inside of the anal canal in any patient with chronic pruritus ani.

K Pavithran,

Department of Dermatology and Venereology,
Medical College Hospital,
Kottayam-686 008, India.