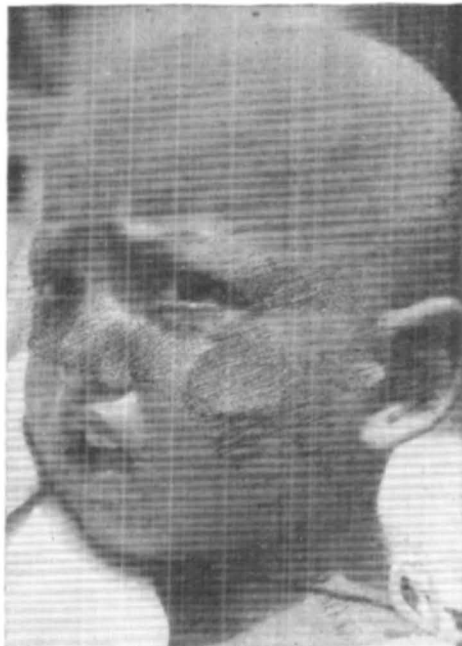


WHAT IS YOUR DIAGNOSIS ?

A three year old female child born to consanguinous parents was admitted with history of skin lesions and diarrhoea of one and a half years' duration. There were spontaneous exacerbations and remissions, the latter lasting for few weeks at a time. The skin lesions used to start as vesicles.



Differential diagnosis:

1. Epidermolysis bullosa simplex
2. Kwashiorkor dermatitis
3. Disseminated candidiasis
4. Acrodermatitis enteropathica

Examination revealed an irritable child stunted in growth with extensive scalp, eyebrow and eyelash alopecia. The dermatitis was present in all mucocutaneous areas. There were vesicles, extensive superficial peeling of skin and large ulcerated areas. Lesions were also present on hands and feet. The history of consanguinous parentage, age of onset, sites of involvement and morphological pattern of skin lesions were all suggestive of acrodermatitis enteropathica. Smear and culture for candida from skin lesions and rectal swab were negative. Child was started on Embequin 150 mg. twice a day with which she showed dramatic improvement.

Final diagnosis: Acrodermatitis enteropathica