

Asymptomatic conchal papules

A 42-year-old woman presented with multiple, asymptomatic, dark, raised lesions involving both her ears. The lesions appeared 1 year ago in her left ear and subsequently involved her right ear. There was no history of arthralgia, oral ulcers, photosensitivity, or alopecia. Review of the systems was unremarkable. On examination, the lesions were bilateral, discrete to confluent, monomorphic, 1-2 mm in diameter, firm, hyperpigmented, and papular involving the auricular conchae and the external auditory meatus. The helix and the crura of the antihelices were spared [Figure 1].

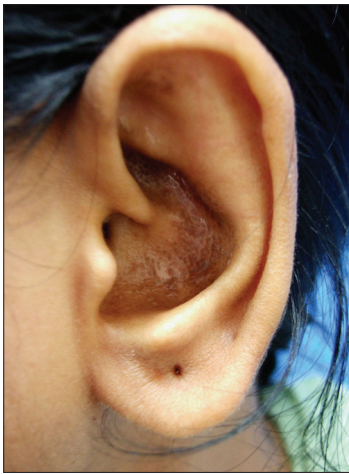

Figure 1: Monomorphic, papular lesions involving the auricular concha

There was no obstruction of the canals on otoscopic examination. Biopsy from the right ear revealed a hyperplastic epidermis and globular masses in the dermal papillae. No evidence of interface dermatitis was demonstrated [Figure 2]. Routine laboratory investigations including complete blood count, blood sugar levels, renal and hepatic and urinary analysis were within normal limits.

WHAT IS YOUR DIAGNOSIS?

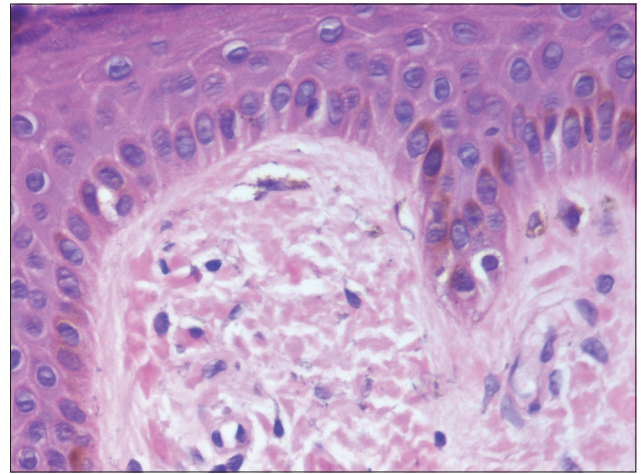


Figure 2: Eosinophilic globules lying in the dilated dermal papilla (H and E, x400)

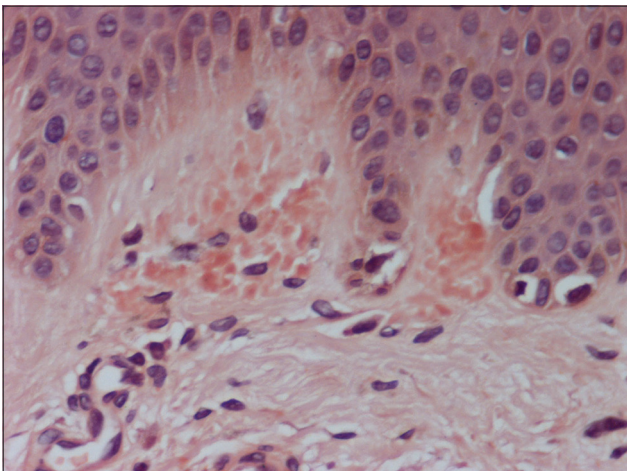


Figure 3: Papillary dermal deposits showing a positive staining with Congo red (CR, x400)

How to cite this article: Kandhari R, Ramesh V, Singh A. Asymptomatic conchal papules. *Indian J Dermatol Venereol Leprol* 2013;79: 445-7.

Received: October, 2012. **Accepted:** December, 2012. **Source of Support:** Nil. **Conflict of Interest:** None declared.

Answer: Lichen amyloidosis of the auricular concha

The histopathological examination was followed by Congo red staining that revealed amorphous, eosinophilic deposits in the papillary dermis [Figure 3].

DISCUSSION

Primary localised cutaneous amyloidosis (PLCA) of the auricular concha and external ear represents a rarely described variant. Lichen amyloidosis (LA) is a common subtype of PLCA, wherein there is deposition of amyloid in previously apparently normal skin with no evidence of deposits in internal organs.^[1] It is defined as a chronic pruritic disorder characterized by multiple, grouped, hyperkeratotic, brownish, papular lesions mainly located on the shins, back, forearms, or thighs. The papules at times may coalesce to form plaques and may localise to a single area or may involve various body sites. The most commonly affected area is the pre-tibial region.^[2] The calves, ankles, dorsa of the feet and thighs, and the extensor aspects of the arms and abdominal or chest wall may also be involved.^[1] Unusual areas of involvement include the auricular concha,^[3,4] the anosacral region,^[5] the scalp, and the interscapular region; in the latter, lichen amyloidosis occurs in association with MEN type 2a syndrome.^[6]

Sanchez *et al.*,^[7] in 1983 first reported papules of the aural conchae in 4 middle-aged women, who had their condition for 1-3 years. Immunostaining profile originally interpreted them as being collagenous in nature. Subsequently, Hicks *et al.*,^[4] in 1988 described 4 patients with papules of the auricle, which were acquired in adulthood and were not associated with lesions elsewhere. Similar findings were seen in our patient as well. They confirmed the diagnosis of amyloid via metachromatic staining with crystal violet and immunoperoxidase reactivity with an anti-keratin monoclonal antibody. Additional reports of similar findings^[3,8-11] have been reported not only in the English literature but also in French,^[12] and Spanish.^[13] Furthermore, cases of biphasic amyloidosis, wherein auricular papules that stained positive with Congo red and were associated with cutaneous amyloid deposition elsewhere have been reported.^[3,8] Isolated cases of amyloid deposits of the auricle have been reported in association with systemic amyloidosis,^[14-16] although most authors believe that primary cutaneous

amyloidosis of the auricular concha is not related with any systemic involvement.^[3,4,8] More recently, a clinicopathological and immunohistochemical study of PLCA of the external ear in 17 patients demonstrated that the amyloid deposits observed were generally positive for Congo red, crystal violet, and thioflavin T and also expressed cytokeratin 34βE12 via immunohistochemistry. The immunohistochemical results suggested that the amyloid deposits in these cases may be a result of basal keratinocyte degeneration and do not signify deposition from a systemic or generalized process.^[17]

The diagnosis of the condition requires a high index of suspicion and one should consider the diagnosis in middle-aged females presenting with long standing, hyperpigmented, multiple, hyperkeratotic, papules involving bilateral conchal bowls, crura of the antihelices, or external auditory canals. The papules range in size from 1-2 mm in diameter, are firm and discrete but may coalesce in areas to resemble plaques. Occasional scaling maybe present, although scarring is not a feature.

Most of the cases are asymptomatic, localised to the external ear, and have no systemic association, thereby warranting the use of modalities such as topical corticosteroids, topical retinoids, calcipotriol, and topical tacrolimus. For those who demand treatment for cosmetic purposes modalities such as curettage or excision maybe considered.^[4,11] Other more invasive treatments such as dermabrasion, CO₂ laser, and Q-switched Nd: YAG laser have been tried in individual cases of lichen amyloidosis with varying success and may be considered as useful options in these cases with localised amyloid deposition. Treatment is disappointing and recurrence seems to be the rule with most modalities. To our knowledge, no such case of lichen amyloidosis involving the auricle has been previously reported from India.

Rajat Kandhari, V. Ramesh, Avninder Singh¹


Department of Dermatology and STD, Vardhaman Mahavir Medical College and Safdarjung Hospital, and ¹Pathology, National Institute of Pathology, Indian Council of Medical Research, New Delhi, India

Address for correspondence: Dr. Rajat Kandhari,
11 Munirka Marg, Vasant Vihar, New Delhi - 110 057, India.
E-mail: rkandhari@gmail.com

REFERENCES

1. Black MM, Upjohn E, Albert S. Amyloidosis. In: Bologna JL, Jorizzo JL, Rapini RP, editors. *Dermatology*. 2nd ed. Missouri, USA: Mosby Elsevier Publishing; 2009. p. 623-31.

2. Habermann MC, Montenegro MR. Primary cutaneous amyloidosis: Clinical, laboratorial and histopathological study of 25 cases. Identification of gammaglobulins and C3 in the lesions by immunofluorescence. *Dermatologica* 1980;160:240-8.
3. Barnadas MA, Pérez M, Esquiús J, Curell R, de Moragas JM. Papules in the auricular concha: Lichen amyloidosus in a case of biphasic amyloidosis. *Dermatologica* 1990;181:149-51.
4. Hicks BC, Weber PJ, Hashimoto K, Ito K, Koreman DM. Primary cutaneous amyloidosis of the auricular concha. *J Am Acad Dermatol* 1988;18:19-25.
5. Wang WJ, Huang CY, Chang YT, Wong CK. Anosacral cutaneous amyloidosis: A study of 10 Chinese cases. *Br J Dermatol* 2000;143:1266-9.
6. Gagel RF, Levy ML, Donovan DT, Alford BR, Wheeler T, Tschen JA. Multiple endocrine neoplasia type 2a associated with cutaneous lichen amyloidosis. *Ann Intern Med* 1989;111:802-6.
7. Sanchez JL. Collagenous papules on the aural conchae. *Am J Dermatopathol* 1983;5:231-3.
8. Bakos L, Weissbluth ML, Pires AK, Müller LF. Primary amyloidosis of the concha. *J Am Acad Dermatol* 1989;20:524-5.
9. Errol C. Lichen amyloidosis of the auricular concha: Report of two cases and review of the literature. *Dermatol Online J* 2006;12:1.
10. Shimauchi T, Shin JH, Tokura Y. Primary cutaneous amyloidosis of the auricular concha: Case report and review of published work. *J Dermatol* 2006;33:128-31.
11. Aoki M, Kawana S. Lichen amyloidosis of the auricular concha: Successful treatment with electrodesiccation. *J Dermatol* 2009;36:116-7.
12. Dupré A, Lassère J, Bonafé JL, Viraben R, Gorguet B. Collagenous papules of the external ear. Micropapular hyalinosis of the external ear with transepithelial elimination. Relation to primary localized cutaneous amyloidosis. *Ann Dermatol Venereol* 1984;111:913-7.
13. Echevarria De MJ, Nanita de Esteve F. Liquen amiloide de pabellon auricular, reporte de ocho casos. *Rev Domin Dermatol* 1980;14:59-63.
14. Noojin RO, Arrington TS. Unusual cutaneous findings in primary systemic amyloidosis: Report of a case. *Arch Dermatol* 1965;92:157-9.
15. El-Sayed I, Busaba NY, Faquin WC. Otolgic manifestations of amyloidosis. *Otol Neurotol* 2002;23:158-9.
16. Ambrosone L, Mansi L, Salvatore T, Marino F, Orabona P, Rambaldi A, *et al.* An unusual case of primary systemic amyloidosis. *J Eur Acad Dermatol Venereol* 1998;10:53-7.
17. Wenson SF, Jessup CJ, Johnson MM, Cohen LM, Mahmoodi M. Primary cutaneous amyloidosis of the external ear: A clinicopathological and immunohistochemical study of 17 cases. *J Cutan Pathol* 2012;39:263-9.

Access this article online	
Quick Response Code:	Website: www.ijdvl.com
	DOI: 10.4103/0378-6323.110808

