

Response to topical halcinonide following fractional carbon dioxide laser pretreatment in a pretibial myxedema patient

Sir,

Pretibial myxedema is a characteristic manifestation of Graves' disease. The treatment of pretibial myxedema remains challenging. Here, we report the response to topical 0.025% halcinonide solution in combination with pretreatment with fractional carbon dioxide laser in a patient with pretibial myxedema.

A 73-year-old male Chinese patient was referred to our department for refractory localized pretibial myxedema on both feet. The patient was diagnosed with Graves' disease 11 years ago and radioactive iodine (^{131}I) was used 10 years ago. Four years before this presentation, he was diagnosed with hypothyroidism and prescribed levothyroxine sodium tablets for daily use. During the past year, pretibial myxedema developed gradually on both pretibia and feet, making it difficult for him to wear shoes and walk. Before our therapy, laboratory tests revealed that the level of thyroid function was in the normal range and the level of thyroid-stimulating hormone receptor antibody was very high (thyroid-stimulating hormone receptor antibody >40 IU/L). Subcutaneous injection of methylprednisolone every month resulted in improvements in the pretibial region after three treatments, but injection into the skin of the feet was difficult due to the obvious hyperplasia. Daily topical application of 0.025% halcinonide solution and wrapping with plastic film for 2 h for 1 month yielded no obvious improvement.

Therefore, we employed a fractional carbon dioxide laser to enhance the topical absorption of steroids. The patient's feet were divided into four parts as shown in Figure 1. Half of the right foot (area A) served as the control without any treatment. The other half of the right foot (area B) was treated with fractional carbon dioxide laser only. Half of the left foot (area C) was treated with a topical 0.025% halcinonide solution once a day while the other half of the left foot (area D) was treated with a fractional carbon dioxide laser every 2 weeks and 0.025% halcinonide solution once a day.

For area B and D, the skin was irradiated with a fractional carbon dioxide laser (AcuPulse[®], Lumenis Ltd., Santa Clara, CA, USA) with fluences ranging from 20 to 30 mJ/cm², the same spot density (10%) and no overlapping of spots during therapy. The variations in fluence were dependent on the thickness of the skin with thicker skin requiring higher fluence until the patient felt slight pain.

After a 6-week period of three treatments, the skin of area D showed obvious improvement compared to the other areas. Area D exhibited thinned skin, finer skin texture and fewer nodules and the boundary between area C and area D was very clear [Figure 2a]. Dermoscopy (DermLite[®] DL1, 3Gen Inc., San Juan Capistrano, CA, USA) revealed more scales and white clods on a pink background on the skin of area C [Figure 2b] which correspond to hyperkeratosis at the periphery of the papules and papillary dermal deposition of mucin, respectively, while more pink background with less scales and white clods were observed on the skin of area D [Figure 2c].¹

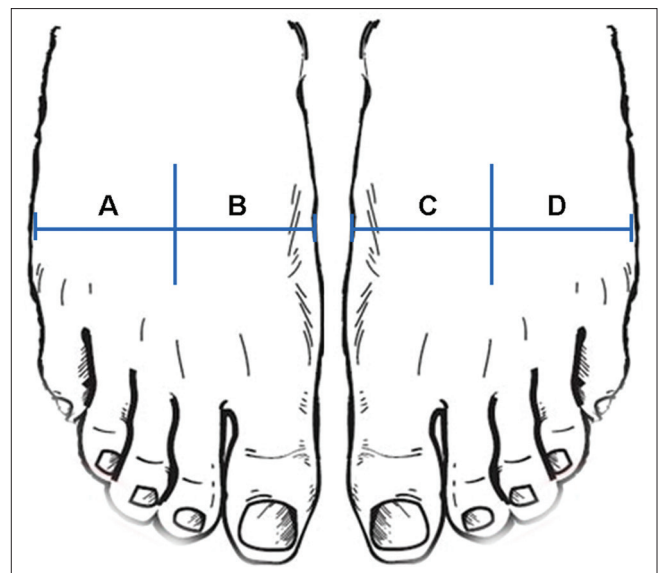


Figure 1: Clinical therapeutic protocol for this case. The patient's two feet were divided into four parts. Half of the right foot (area A) served as the negative control and did not receive any treatment; the other side of the right foot (area B) was treated with fractional carbon dioxide laser only. Half of the left foot (area C) was treated with topical 0.025% halcinonide solution once a day, while the other half of the left foot (area D) was treated with fractional carbon dioxide laser every 2 weeks in addition to the daily topical application of 0.025% halcinonide solution

This is an open access journal, and articles are distributed under the terms of the Creative Commons Attribution-NonCommercial-ShareAlike 4.0 License, which allows others to remix, tweak, and build upon the work non-commercially, as long as appropriate credit is given and the new creations are licensed under the identical terms.

For reprints contact: reprints@medknow.com

How to cite this article: Xu Y, Ma R, Cai Y, Zheng X. Response to topical halcinonide following fractional carbon dioxide laser pretreatment in a pretibial myxedema patient. *Indian J Dermatol Venereol Leprol* 0;0:0.

Received: September, 2016. **Accepted:** January, 2017.

Access this article online

Quick Response Code:



Website:

www.ijdvl.com

DOI:

10.4103/ijdvl.IJDVL_796_16

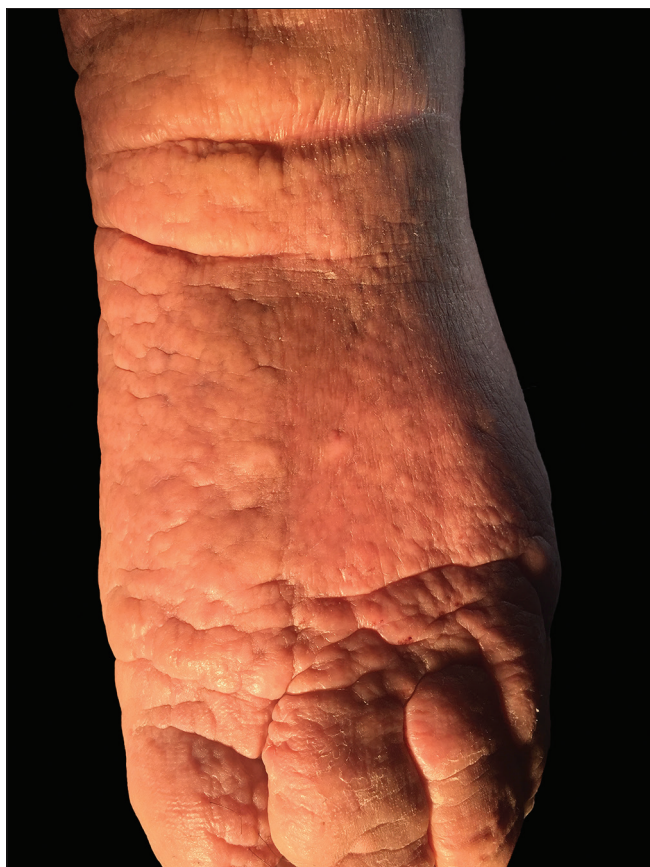


Figure 2a: Combined therapy with a fractional carbon dioxide laser and topical 0.025% halcinonide solution induced remarkable improvement compared to treatment with topical 0.025% halcinonide solution alone. The areas C and D were treated as described for Figure 1. After 6 weeks, the clinical picture was taken

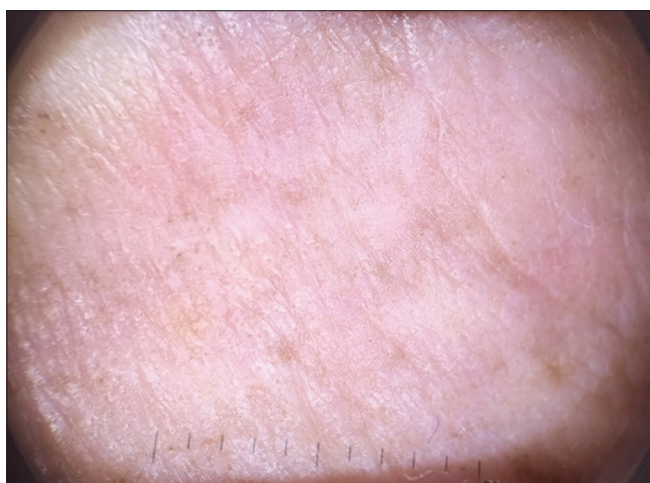

Figure 2c: The areas C and D were treated as described for Figure 1. After 6 weeks, the deamoscopic picture was taken: right side (area D)

Histological results confirmed these observations [Figure 2d-f]. On the right side (area D), less edema, less alcian blue-stained mucin and more collagen fibers were observed compared to the left side (area C), demonstrating improvement of pretibial myxedema. These observations were further confirmed by quantitative assessment of the percentage of collagen density (the pink-purple-stained area

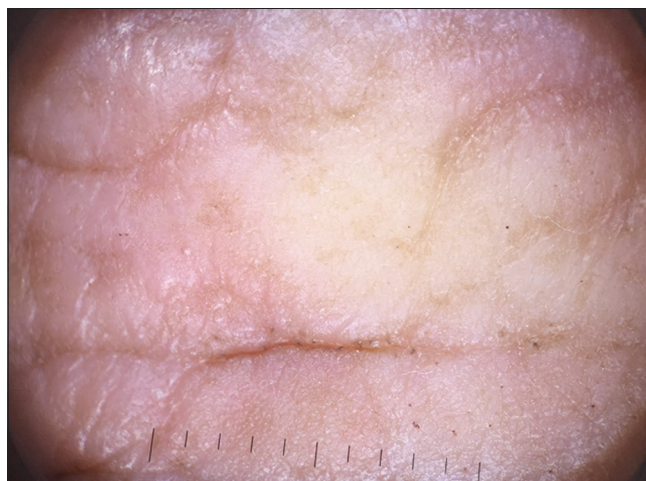


Figure 2b: The areas C and D were treated as described for Figure 1. After 6 weeks, the deamoscopic picture was taken: left side (area C)

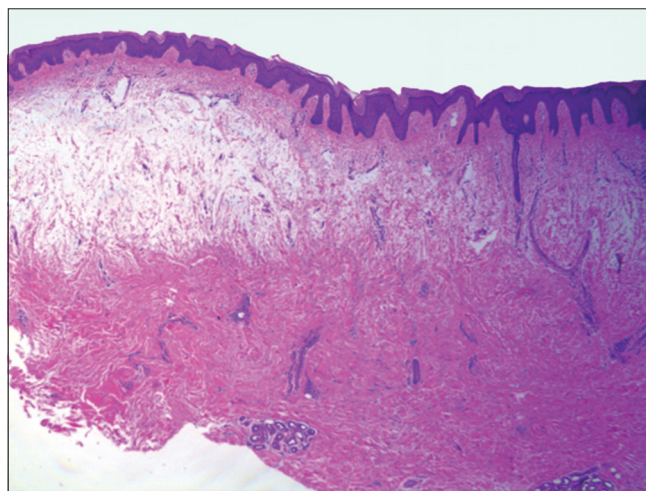


Figure 2d: After 6 weeks, a skin sample was taken from the middle of the foot and subjected to staining with H and E. The image was taken under $\times 100$ magnification. On the right side (area D), less edema and more collagen fibers were observed compared to the left side (area C)

in Figure 2d; area C: $30.9\% \pm 2.5\%$ vs. area D: $65.9\% \pm 0.4\%$, $*P = 0.0008$) and mucin deposition (the dark blue-stained area in Figure 2e; area C: $59.2\% \pm 7.0\%$ vs. area D: $26.9\% \pm 6.4\%$, $**P = 0.023$) using ImageJ software (<http://rsbweb.nih.gov/ij/>).

During the following 22 weeks, all four areas were treated with the combined therapy protocol as area D. The fluences of laser were gradually decreased to $12.5\text{--}15\text{ mJ/cm}^2$ to avoid pain. After a total of 28 weeks, the thickness and roughness of the skin were improved and specifically, the nodules and plaques around the ankles diminished [Figure 3a and 3b]. The patient was more comfortable wearing shoes and walking, and he refused further treatment.

Besides systemic management of Graves' disease, the most widely used treatments for pretibial myxedema are glucocorticoids. Topical glucocorticoids were reported to be useful in some cases but did not work in our patient.² Moreover, subcutaneous injection of steroids was too difficult due to the obvious hyperplasia. Hence, we chose fractional carbon dioxide laser to enhance transdermal delivery which had been reported to be effective

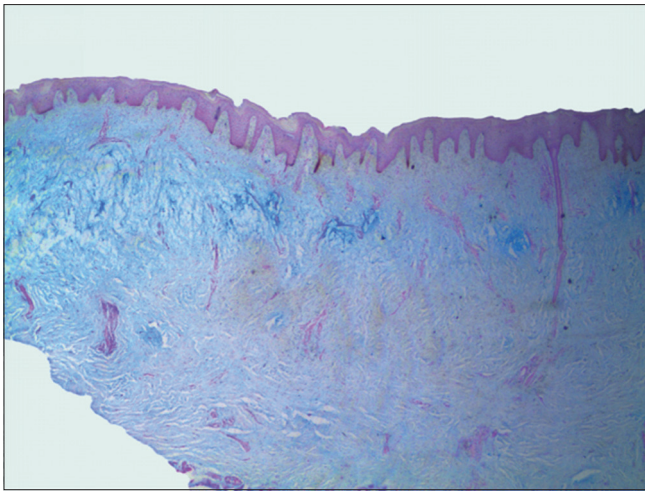


Figure 2e: The skin sample taken from the middle of Area C and Area D was stained by Alcian blue. The picture was taken under $\times 100$ magnification. Less alcian blue-stained mucin was observed on the right side (area D) than the left side (area C)

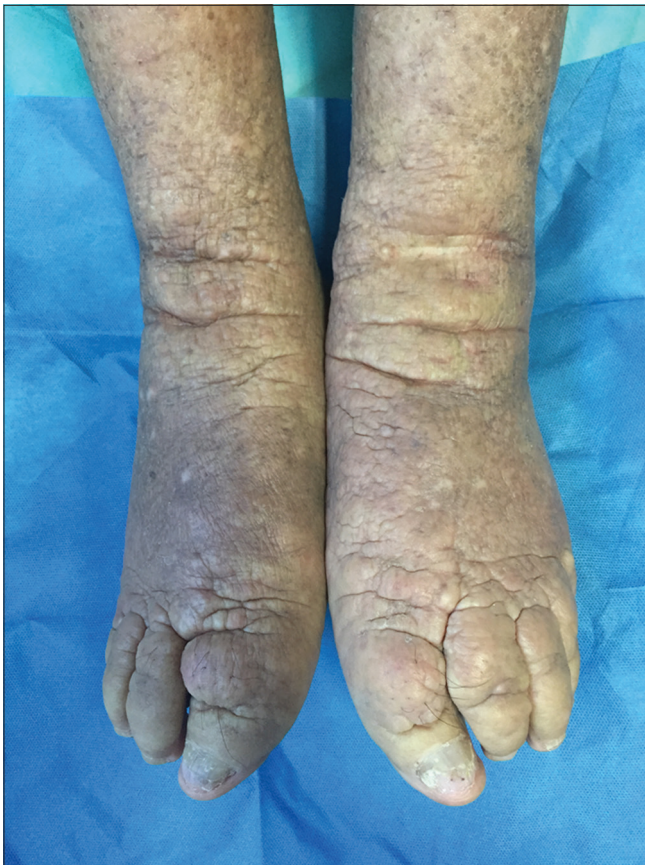

Figure 3a: Clinical manifestation before 11 sessions of combination treatment with fractional carbon dioxide laser and topical 0.025% halcinonide solution. After the first 6-week period, during which different protocols were used on the four areas of the patient's feet, combination therapy was used for all areas with fractional carbon dioxide laser therapy every 2 weeks and topical 0.025% halcinonide solution application daily

in enhancing absorption of lots of topical substances including glucocorticoids.³ As expected, the combined therapy was revealed

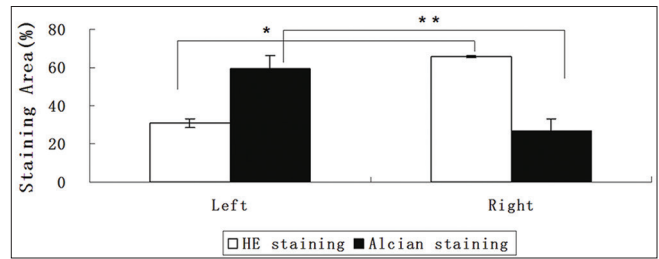


Figure 2f: The percentage of H and E and alcian-stained areas in the dermis (Figure 2d and Figure 2e) was determined using ImageJ. The data indicate means \pm standard deviation ($n = 3$). The right and left sides were compared ($*P < 0.05$ and $**P < 0.05$)

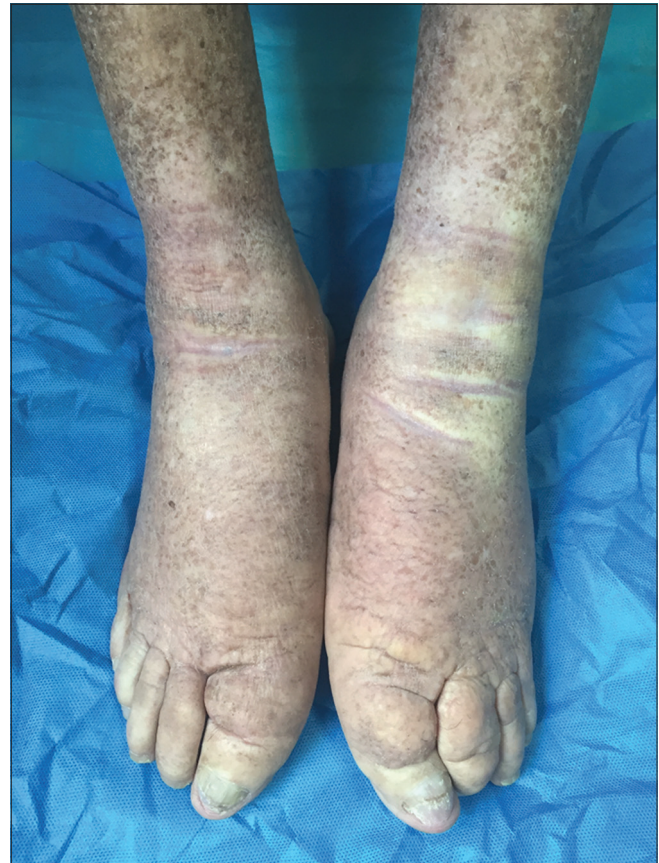

Figure 3b: Clinical improvement after 11 sessions of combination treatment with fractional carbon dioxide laser and topical 0.025% halcinonide solution. After another eleven sessions for a duration of 22 weeks, the clinical image shown here was acquired

as a promising treatment modality for pretibial myxedema. However, randomized, blinded, controlled clinical studies with more samples and a longer follow-up period are needed for further confirmation.

Financial support and sponsorship

This study was supported by the Chinese National Natural Science Foundation (81301384), Jiangsu Province Natural Science Foundation (BK20131029) and the Priority Academic Program Development of Jiangsu Higher Education Institutions (No. JX10231801).

Conflicts of interest

There are no conflicts of interest.

Medical University, Nanjing 210029, China.

E-mail: zqx5126@163.com

Yang Xu, Renyan Ma, Yun Cai¹, Xuqin Zheng¹

Departments of Dermatology and ¹Endocrinology, The First Affiliated Hospital of Nanjing Medical University, Nanjing, China

Correspondence: Dr. Xuqin Zheng,
Department of Endocrinology, The First Affiliated Hospital of Nanjing

References

1. Rojanametin K, Masaru T. Dermoscopy of pretibial myxedema. *J Am Acad Dermatol* 2015;73:e195-6.
2. Kriss JP, Pleshakov V, Rosenblum A, Sharp G. Therapy with occlusive dressings of pretibial myxedema with fluocinolone acetonide. *J Clin Endocrinol Metab* 1967;27:595-604.
3. Yu J, Bachhav YG, Summer S, Heinrich A, Bragagna T, Böhler C, *et al.* Using controlled laser-microporation to increase transdermal delivery of prednisone. *J Control Release* 2010;148:e71-3.