

Yellow urticaria in a patient with alcohol-related liver cirrhosis and jaundice

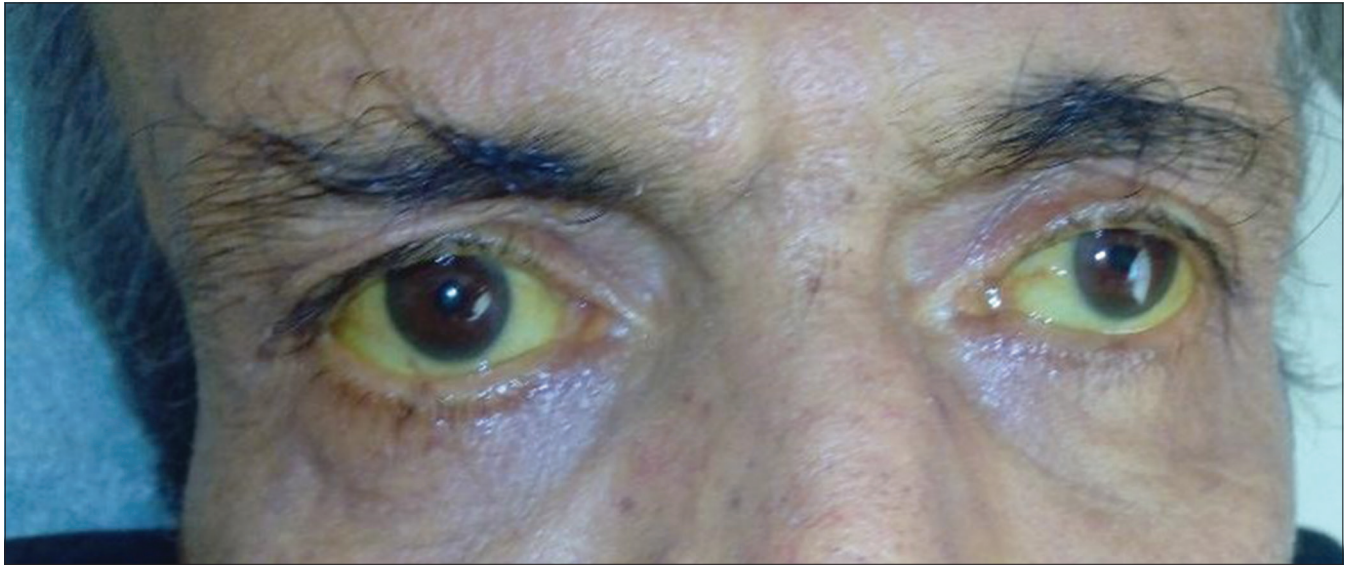


Figure 1: Evident conjunctival icterus of the patient

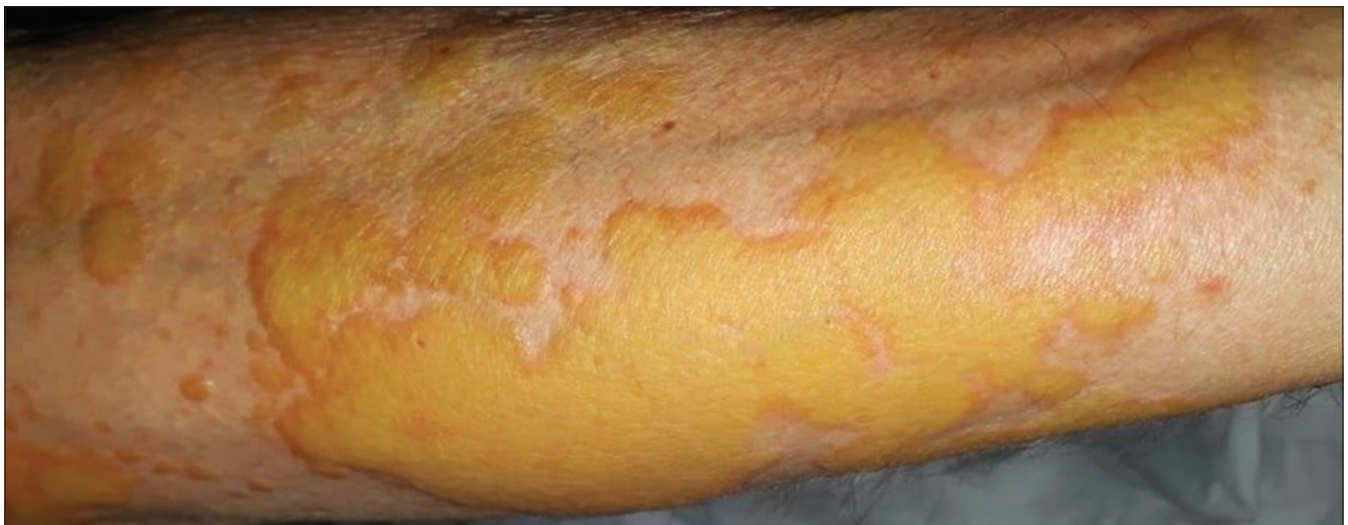

Figure 2: Multiple yellowish raised hives on the right arm

How to cite this article: Koumaki D, Demetriou G, Krasagakis K. Yellow urticaria in a patient with alcohol-related liver cirrhosis and jaundice. *Indian J Dermatol Venereol Leprol* 2021;87:676-7.

Received: September, 2019 **Accepted:** November, 2019 **EPub Ahead of Print:** February, 2021 **Published:** August, 2021

DOI: 10.4103/ijdv.IJDVL_616_19 **PMID:** 32108616

This is an open-access article distributed under the terms of the Creative Commons Attribution-Non Commercial-Share Alike 4.0 License, which allows others to remix, tweak, and build upon the work non-commercially, as long as the author is credited and the new creations are licensed under the identical terms.

A 61-year-old male patient, admitted at our gastroenterology department with acute cholecystitis, alcohol-related liver cirrhosis, and jaundice [Figure 1] developed several evanescent, oedematous yellowish wheals on his body [Figure 2] over the preceding 24 h. He had been administered intravenous (iv) piperacillin/tazobactam 4.5 g and rifaximin 200 mg thrice daily for last 48 hours. Blood tests revealed raised direct bilirubin (13.87 mg/dl) and SGOT (78 U/L). His antibiotics were switched to iv ciprofloxacin and daptomycin. He received chlorphenamine 4 mg/4 ml iv twice daily for 7 days and his urticaria subsided within 24 h. We made a diagnosis of drug-induced urticaria.

Yellow urticaria is associated with elevated level of serum bilirubin resulting in its excess deposition in various tissues like conjunctiva and skin.¹ Other causes of yellow skin discoloration include carotenemia, several drugs, and inherited disorders including Gilbert syndrome.¹

Declaration of patient consent

The authors certify that they have obtained all appropriate patient consent forms. In the form, the patient has given his consent for his images and other clinical information to be reported in the journal. The patient understands that name and initials will not be published and due efforts will be made to conceal identity, but anonymity cannot be guaranteed.

Financial support and sponsorship

Nil.

Conflicts of interest

There are no conflicts of interest.

Dimitra Koumaki, George Demetriou¹, Konstantinos Krasagakis

Departments of Dermatology and ¹Gastroenterology, University Hospital of Heraklion, Crete, Greece

Corresponding author:

Dr. Dimitra Koumaki,

Department of Dermatology, University Hospital of Heraklion, Voutes, Heraklion, 71 110, Crete, Greece.

dkoumaki@yahoo.gr

Reference

1. Combalia A, Fustà X, Guilabert A, Mascaró JM Jr, Estrach T. Yellow urticaria: Report of two cases and review of the literature. *J Eur Acad Dermatol Venereol* 2017;31:e204-6.