

## Successful treatment of early-onset hidradenitis suppurativa with acitretin in an infant with a novel mutation in *PSENE* gene

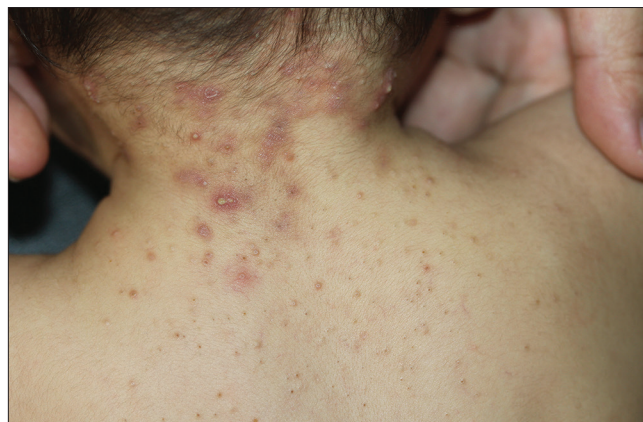Sir,

Hidradenitis suppurativa (HS), is a chronic inflammatory disease of follicular occlusion, leading to recurrent nodules, abscesses, draining sinuses and scar formation in the apocrine gland areas. The etiology of the condition is unclear; more than one-third of patients have a family history. To date, thirty-four mutations have been reported in three genes encoding the  $\gamma$ -secretase complex: presenilin (*PSENI*), presenilin enhancer 2 (*PSENE*) and nicastrin (*NCSTN*). Here we report a Chinese infant with an early-onset hidradenitis suppurativa who bears a novel mutation in *PSENE* gene and his response to the treatment with acitretin.

A boy born to a non-consanguineous family was referred to our department at the age of 17 months. The rash first appeared on the occipital area when he was 11-month-old and then gradually spread on the face and chest without pruritus. Physical examination showed a large number of follicle-based inflammatory papules, pustules and closed comedones in the posterior neck, face and anterior chest [Figure 1]. The general health of the boy was otherwise normal. His mother had developed 2-4 mm sized open comedones and pitted scars on her face and neck, at puberty. No significant pigmentation was found in the flexures.

Genetic tests were conducted after obtaining informed consent. Whole-exome sequencing was done, that found a novel splice site deletion of *PSENE* gene in the proband and his mother: c.62-1 (IVS2)delG, this mutation was absent in his unaffected father [Figure 2a]. We then performed Sanger sequencing of cDNA identified that the proband and his mother were both heterozygous for the c.60\_66. del G variant [Figure 2b], that caused a frame-shift and premature end of the stop codon at exon 3 (P.F23LfsX10).

The treatment we gave the patient initially was cefixime (2.5 mg/kg per day) and topical application of fusidic acid cream and adapalene gel for one month, but the response to treatment was poor. After obtaining parental informed



**Figure 1:** The skin lesions of the proband on posterior neck before treatment: A large number of red papules, pustules and closed comedones could be seen.

consent, oral acitretin in an initial dose of 0.5 mg/kg per day was conducted under regular monitoring of liver and kidney function and serum lipid level monthly, X-ray for bones semiannually. After four months of treatment with acitretin, the rashes almost disappeared [Figure 3]. A follow-up of laboratory tests showed no abnormalities, except for the symptoms of dry mouth after six months of use.

Hidradenitis suppurativa usually occurs after puberty, prepubertal onset is thought to be rare, it is reported only in six (2%) of patients before the age of 11 years.<sup>1</sup> Some reports stated that the low number of children diagnosed with this condition may be due to the apocrine glands in infants and children that have not been fully developed. This may lead to misdiagnosis such as bacterial folliculitis.<sup>2</sup>

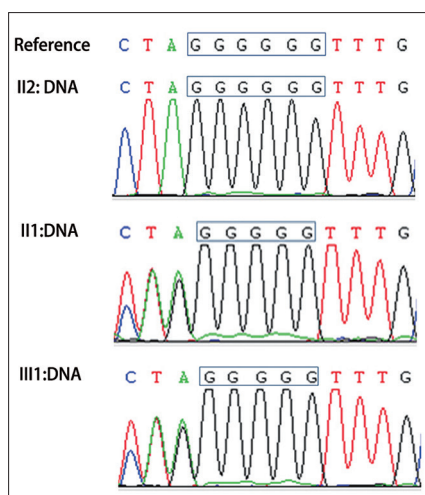
*PSENE* gene (NM\_172341) is located on chromosome 19 containing four exons which are required for the function of  $\gamma$ -secretase. Till now, fourteen different *PSENE* mutations have been reported, five of which are from China

**How to cite this article:** Chen A, Chen Z, Bai X, Luo X, Wang H. Successful treatment of early-onset hidradenitis suppurativa with acitretin in an infant with a novel mutation in *PSENE* gene. *Indian J Dermatol Venereol Leprol* 2022;88:445.

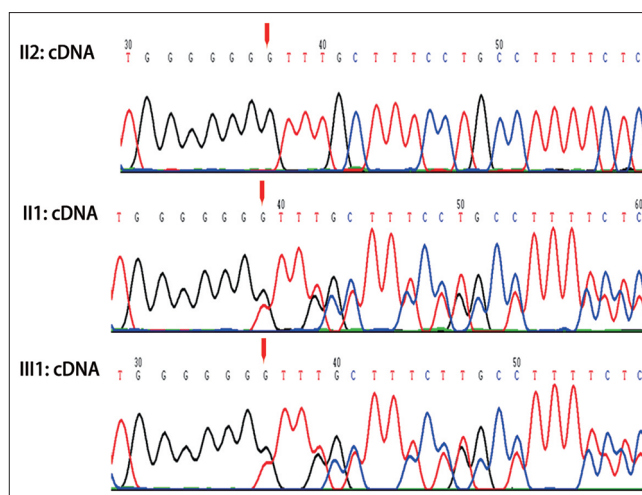
**Received:** September, 2019 **Accepted:** August, 2020 **Epub ahead of Print:** February, 2022 **Published:** April, 2022

**DOI:** 10.25259/IJDVL\_471\_19 **PMID:** 35146980

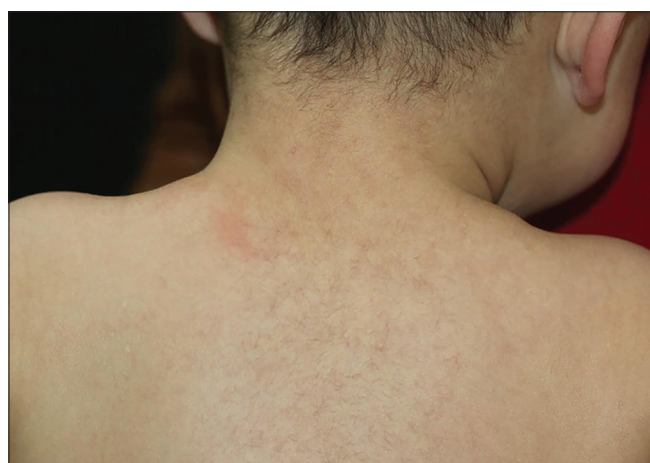This is an open-access article distributed under the terms of the Creative Commons Attribution-Non Commercial-Share Alike 4.0 License, which allows others to remix, tweak, and build upon the work non-commercially, as long as the author is credited and the new creations are licensed under the identical terms.



**Figure 2a:** Sequence of genomic DNA, showing c.62-1 (IVS2) delG in proband (III: 1) and his mother (II: 1)



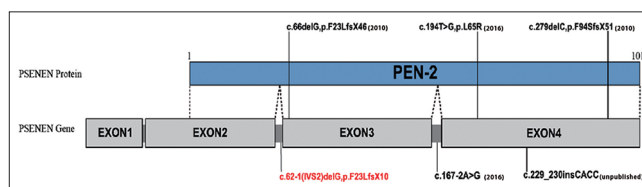
**Figure 2b:** Sequence of genomic cDNA, showing c.60\_66.del G variant in proband (III: 1) and his mother (II: 1)



**Figure 3:** The improved skin lesions in the proband after treatment with oral acitretin for 4 months

c.66delG and c.279delC were found in 2010, Wang *et al.*<sup>3</sup>; c.194T>G and c.167-2A>G were found in 2016, Zhou *et al.*<sup>4</sup>; c.229\_230insCACC was from unpublished data, Zhang *et al.*<sup>5</sup> [Figure 4]. In our study, premature stop codon at exon 3 altered the *PSENEN* protein, affected the protease activity of  $\gamma$ -secretase, and disrupted the  $\gamma$ -secretase Notch signaling pathway, that lead to epidermal and follicular hyperkeratosis and epidermal cyst formation.

Treatment of hidradenitis suppurativa is challenging. Acitretin is indicated in the early stage. But the use of acitretin has been limited in children due to its potential side-effects. Recently, a retrospective study including three Chinese children on continuous acitretin monotherapy for more than ten years revealed long-term safety and efficacy.<sup>4</sup> The good response and relative lack of adverse events in our patient following oral acitretin lends proof to consider that acitretin can be a promising agent in children with hidradenitis suppurativa.



**Figure 4:** Summary of mutations in *PSENEN* gene reported in China, the novel mutation found in this study was highlighted in red

**Acknowledgment**

We thank the patient and her parents, who really cooperated in this study.

**Declaration of patient consent**

The authors certify that they have obtained all appropriate patient consent.

**Financial support and sponsorship**

This study was supported by the Natural Science Foundation of China (8170120529).

**Conflicts of interest**

There are no conflicts of interest.

**An-Wei Chen, Zhi Chen, Xiao-Ming Bai<sup>1</sup>,  
Xiao-Yan Luo<sup>2</sup>, Hua Wang<sup>3</sup>**

Chongqing Key Laboratory of Child Infection and Immunity, <sup>1</sup>Ministry of Education Key Laboratory of Child Development and Disorders, <sup>2</sup>China International Science and Technology Cooperation Base of Child Development and Critical Disorders, <sup>3</sup>Department of Dermatology, Children's Hospital of Chongqing Medical University, Chongqing, China.

**Corresponding author:**

Dr. Hua Wang,  
Department of Dermatology, Children's Hospital of Chongqing Medical University, No. 136, Zhongshan 2<sup>nd</sup> Rd., Liang Lu Kou, Yuzhong District, Chongqing, 400014, China.  
huawang@hospital.cqmu.edu.cn

## References

1. Palmer RA, Keefe M. Early-onset hidradenitis suppurativa. *Clin Exp Dermatol* 2001;26:501-3.
2. Bettoli V, Ricci M, Zauli S, Virgili A. Hidradenitis suppurativa-acne inversa: A relevant dermatosis in paediatric patients. *Br J Dermatol* 2015;173:1328-30.
3. Wang B, Yang W, Wen W, Sun J, Su B, Liu B, *et al.* Gamma-secretase gene mutations in familial acne inversa. *Science* 2010;330:1065.
4. Zhou C, Wen GD, Soe LM, Xu HJ, Du J, Zhang JZ. Novel mutations in PSENEN gene in two Chinese acne inversa families manifested as familial multiple comedones and Dowling-Degos disease. *Chin Med J (Engl)* 2016;129:2834-9.
5. Li W, Xu H, He Y, Lin L, Li C. Comorbidities or different entities? Phenotype variability associated with PSENEN mutations. *Br J Dermatol* 2019;180:221-2.
6. Liang J, Chen P, Chen H, Tian X, Wu Z, Zhang S, *et al.* Long-term safety and efficacy of continuous acitretin monotherapy for three children with different severe hyperkeratotic disorders in China. *J Dermatol* 2018;45:1003-8.