

# Ultraviolet reflectance dermoscopy

Feroze Kaliyadan, Puravoor Jayasree,<sup>1</sup> Karalikkattil T Ashique<sup>2</sup>

Department of Dermatology, Sree Narayana Institute of Medical Sciences, Kochi, <sup>1</sup>Department of Dermatology, Medical Trust Hospital, Cochin, <sup>2</sup>Department of Dermatology, Amanza Skin Clinic, Perinthalmanna, Kerala, India

## Introduction

Ultraviolet (UV) light has been an integral part of the dermatological examination, primarily in the form of the Wood's lamp, which uses 'black light' having a peak output wavelength of 365 nm and aids in the diagnosis of conditions like pigmentary disorders (vitiligo, melasma, naevus depigmentosus) and superficial (fungal and corynebacterial) infections. Some other indications for which the Wood's lamp can be used include – evaluation of *Cutibacterium acnes*, which can produce an orange-red colour in pilosebaceous follicles, pseudomonas infections which can produce a green fluorescence, and also porphyrias.<sup>1</sup> The Wood's lamp can also be used in the evaluation of premature canities and compliance regarding the use of sunscreens.<sup>2,3</sup>

## UV dermoscopy

UV reflectance dermoscopy (UVRD) is a relatively new innovation, combining dermoscopy with UV light evaluation. Like the Wood's lamp, UV dermoscopy can be useful in pigmentary disorders such as vitiligo and melasma. Lesional margins, perifollicular pigmentation, and depigmentation can be better appreciated under UV dermoscopy as compared to normal dermoscopy.<sup>2</sup> Dermoscopy with near-UV light can highlight demarcation of the distribution of melanin in cutaneous melanoma.<sup>4</sup>


Sebaceous gland openings can show fluorescence under UVRD – ranging from bright blue/green to yellow, orange, or red. This could possibly be useful in the diagnosis and follow-up of acne vulgaris [Figure 1]. The same principle has been used to differentiate Fordyce's spots from its mimickers. On normal polarised dermoscopy, Fordyce's spots present as whitish-yellow clods, clustered together. Under UVRD, the fluorescence at the tip of the sebaceous opening can be seen over the less prominent, ill-defined yellow-green clods.<sup>5</sup>

UVRD has been shown to be useful in the diagnosis of scabies too. UVRD of scabietic burrows highlights the blue fluorescence of the burrow and can also visualise a bright green fluorescence from the female mite's body.<sup>6</sup>

UVRD showing prominent yellowish-green fluorescence has been reported in trichomycosis axillaris.<sup>7</sup> Pink glow on UV dermoscopy has been identified as a helpful sign for the diagnosis of subungual glomus tumour.<sup>8</sup>

## Other applications of UVRD

Some other indications in which we found UVRD useful include:



**Figure 1:** Orange fluorescence due to porphyrins produced by *cutibacterium acnes* (Dermlite™ DL5 UV mode).

**How to cite this article:** Kaliyadan F, Jayasree P, Ashique KT. Ultraviolet reflectance dermoscopy. Indian J Dermatol Venereol Leprol. 2024;90:838-41. doi: 10.25259/IJDVL\_1308\_2023

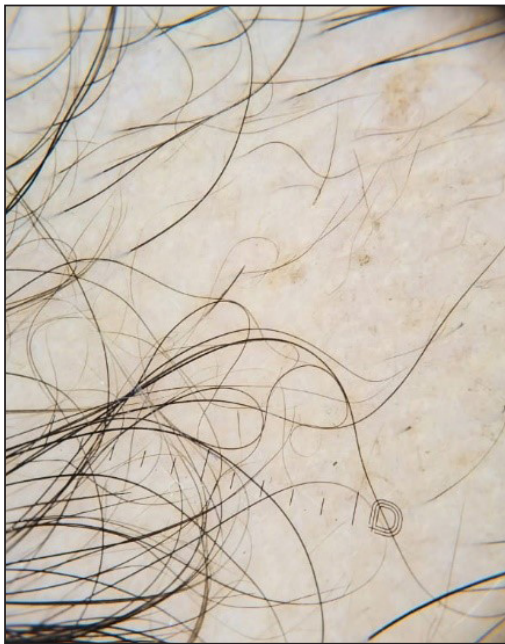**Corresponding author:** Dr. Feroze Kaliyadan, Department of Dermatology, Sree Narayana Institute of Medical Sciences, Kochi, Kerala, India. ferozkal@gmail.com

**Received:** December, 2023 **Accepted:** January, 2024 **Epub Ahead of Print:** April, 2024 **Published:** October, 2024

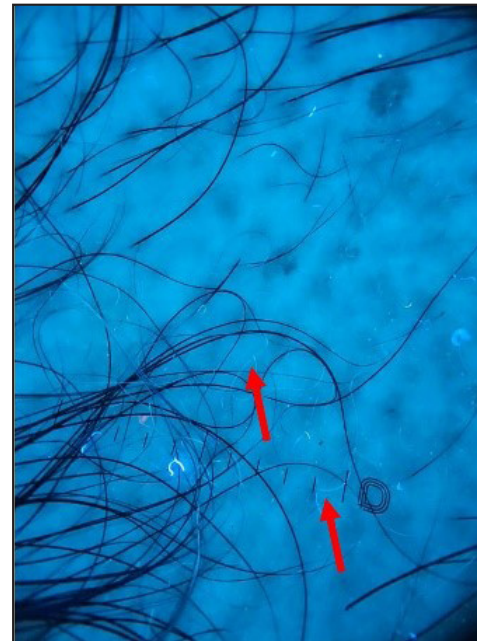
**DOI:** 10.25259/IJDVL\_1308\_2023 **PMID:** 38841957

This is an open-access article distributed under the terms of the Creative Commons Attribution-Non Commercial-Share Alike 4.0 License, which allows others to remix, transform, and build upon the work non-commercially, as long as the author is credited and the new creations are licensed under the identical terms.

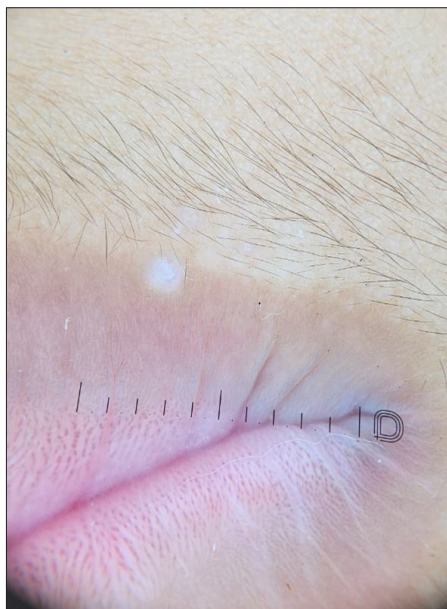- Evaluation of premature canities - like the Wood's lamp examination, UVRD can highlight the grey hairs better. Similarly, it can help in the evaluation of fine regrowing hairs in alopecia areata (AA). Fine, regrowing hairs in AA can be devoid of pigment. UVRD picks up these hairs better as compared to standard dermoscopy [Figures 2a and 2b].
- Molluscum contagiosum – central umbilicated area shows bright white fluorescence [Figures 3a and 3b].
- Scaling tends to be generally more prominently seen under UV dermoscopy. For example, in pityriasis versicolor – the fine scales are visible more clearly using UVRD and can be enhanced by grattage test [Figures 4a and 4b].
- The UV blink sign - The dermoscopic ‘blink sign’ describes the blinking appearance of certain dermoscopic patterns when the device is toggled between polarised and non-polarised modes. For example, the comedo-like



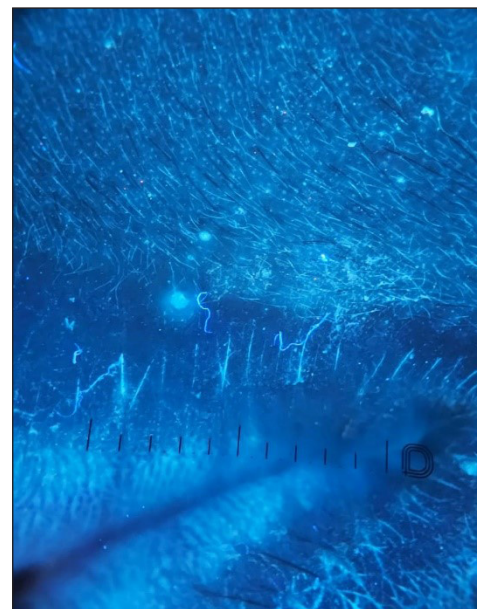
**Figure 2a:** Alopecia areata showing regrowing hairs (Dermlite™ DL5 polarised mode).



**Figure 2b:** White hairs are seen more clearly under UV dermoscopy (red arrows) (Dermlite™ DL5 UV mode).



**Figure 3a:** Dermoscopy of molluscum contagiosum (Dermlite™ DL5 polarised mode).



**Figure 3b:** Dermoscopy of molluscum contagiosum – central umbilicated area shows bright white fluorescence (Dermlite™ DL5 UV mode).


openings in seborrheic keratosis are visualised more clearly on non-polarised dermoscopy, as compared to polarised dermoscopy, and hence these structures appear to blink when the dermoscope is toggled between polarised and non-polarised modes.<sup>9</sup> The comedo-like openings and milia-like cysts seen in seborrheic keratosis tend to be clearer under UV and these structures show a

blinking effect when the dermoscope is toggled between UV and non-UV modes. We would like to label this as the ‘dermoscopic UV blink sign’ (personal observation) [Figures 5a and 5b].

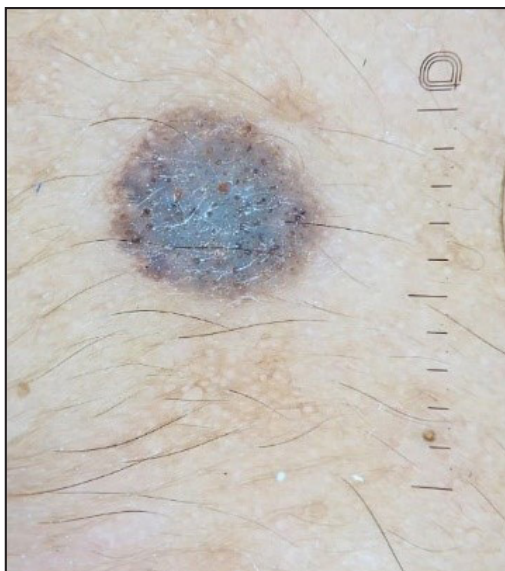- The pigmentary patterns in conditions like vitiligo tend to be generally clearer under UV dermoscopy [Figures 6a and 6b].



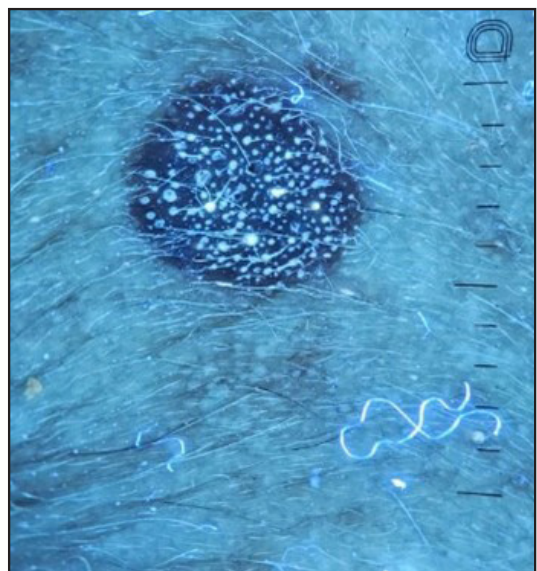
**Figure 4a:** Dermoscopy of hypopigmented pityriasis versicolor (Dermlite™ DL5 polarised mode).



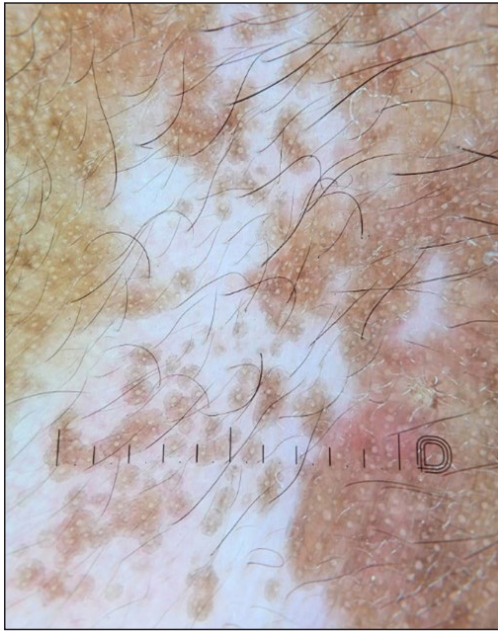**Figure 4b:** Dermoscopy of hypopigmented pityriasis versicolor – fines scales are visible more clearly (Dermlite™ DL5 UV mode).



**Figure 5a:** The UV dermoscopic blink sign in seborrheic keratosis (Dermlite™ DL5 polarised mode).



**Figure 5b:** The UV dermoscopic blink sign in seborrheic keratosis (Dermlite™ DL5 UV mode).



**Figure 6a:** Dermoscopy of vitiligo (Dermlite™ DL5 polarised mode).



**Figure 6b:** Dermoscopy of vitiligo – white glow seen more clearly (Dermlite™ DL5 UV mode).

## Conclusion

The combination of dermoscopy with UV light is a relatively recent introduction and can be useful in diagnostic dermatology. Most dermoscopes that incorporate UV light use a non-polarised form of UV light and hence it is basically like an examination under magnification using UV light. However, using a contact fluid along with the UV light mode will convert this into true UV dermoscopy

**Declaration of patient consent:** The authors certify that they have obtained all appropriate patient consent.

**Financial support and sponsorship:** Nil.

**Conflicts of interest:** There are no conflicts of interest.

**Use of artificial intelligence (AI)-assisted technology for manuscript preparation:** The authors confirm that there was no use of artificial intelligence (AI)-assisted technology for assisting in the writing or editing of the manuscript and no images were manipulated using AI.

## References

1. Dyer JM, Foy VM. Revealing the unseen: A review of wood's lamp in dermatology. *J Clin Aesthet Dermatol* 2022;15:25–30.
2. Yuan M, Xie Y, Zheng Y, Zhang Z, Yang C, Li J. Novel ultraviolet-dermoscopy: Early diagnosis and activity evaluation of vitiligo. *Skin Res Technol* 2023;29:e13249.
3. Kaliyadan F, Jayasree P, Ashique KT. Looking for a grey needle in a 'hair' stack! Using a wood's lamp for evaluating canities. *Indian J Dermatol Venereol Leprol* 2023;89:636–7.
4. Sano T, Minagawa A, Suzuki R, Koga H, Okuyama R. Dermoscopy with near-ultraviolet light highlights the demarcation of melanin distribution in cutaneous melanoma. *J Am Acad Dermatol* 2021;84:e23–e24.
5. Pietkiewicz P, Navarrete-Dechent C, Goldust M, Korecka K, Todorovska V, Errichetti E. Differentiating fordyce spots from their common simulators using ultraviolet-induced fluorescence dermoscopy-retrospective study. *Diagnostics (Basel)* 2023;13:985.
6. Pietkiewicz P, Navarrete-Dechent C. Scabies mite is bright green under uv dermoscopy. *Dermatol Pract Concept* 2023;13:e2023135.
7. Al-Nasiri M, Navarrete-Dechent C, Korecka K, Salwowska N, Goldust M, Pietkiewicz P. Ultraviolet reflectance dermoscopy of trichobacteriosis axillaris reveals peripilar yellow-green luminescent concretions. *Dermatol Pract Concept* 2023;13:e2023169.
8. Thatte SS, Chikhalkar SB, Khopkar US. "Pink glow": A new sign for the diagnosis of glomus tumor on ultraviolet light dermoscopy. *Indian Dermatol Online J* 2015;6:S21–3.
9. Braun RP, Scope A, Marghoob AA. The "blink sign" in dermoscopy. *Arch Dermatol* 2011;147:520.