

## CYSTICERCUS CELLULOSAE CUTIS

M Jayaraman, K V Sampath Kumar, V R Janaki, Patrick Yesudian

A case of cysticercus cellulosae is reported with its unique histopathological features.

**Key Words :** Cysticercus cellulosae, Cysticercosis

### Introduction

Cysticercosis occurs due to the lodgement of the larvae of *Taenia solium*, the pork tapeworm in various organs. These manifest as one to several firm, asymptomatic nodules in the skin, skeletal muscles, heart, eyes and brain.<sup>1</sup> They measure 1 to 2 cm in size.<sup>2</sup> They persist for many years and may be calcified.

### Case Report

A 28-year-old man presented with multiple, asymptomatic firm nodules over the trunk and limbs of 1 year duration. On examination the nodules were slightly mobile. Patient gave history of taking pork meat 18 months back. There was no history of any epilepsy. One of the nodules was excised and on histopathological examination showed a cystic cavity containing a white irregular shaped membranous structure, the cysticercus cellulosae (Fig. 1). The cyst was surrounded by a thick fibrous capsule.

### Comments

*Cysticercus cellulosae* is a term referring to the cross section of the larvae of

*T. solium*.<sup>3</sup> This is seen as a cystic cavity containing a clear fluid and lined by a white membranous structure. Our case is reported for its unique histopathological features and to entertain cysticercosis as one of the differential diagnosis in any subcutaneous swelling.

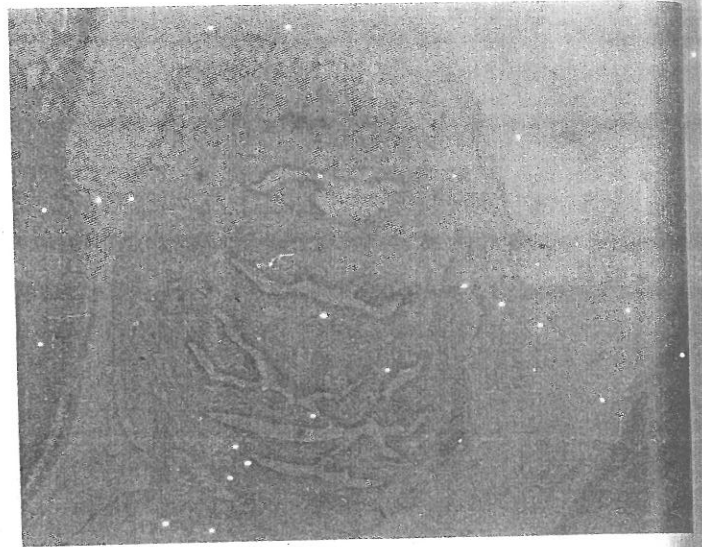


Fig. 1. Photomicrograph showing cross section of cystic cavity lined by a membranous structure. (H&E x 50)

### References

1. Raimer S, Wolf JE Jr. Subcutaneous cysticercosis. Arch Dermatol 1979; 115 : 236.
2. Tschen EH, Smith EB. Cutaneous cysticercosis treated with metrifonate. Arch Dermatol 1978; 114 : 107-8.
3. King DT, Gilbert DJ, Gurevitch AW, et al. Subcutaneous cysticercosis. Arch Dermatol 1979; 115 : 236.

From the Department of Dermatology, Madras Medical College, Madras - 600 003, India.

Address correspondence to : Dr M Jayaraman  
222 R K Mutt Road, Mylapore, Madras - 600 004,  
India.