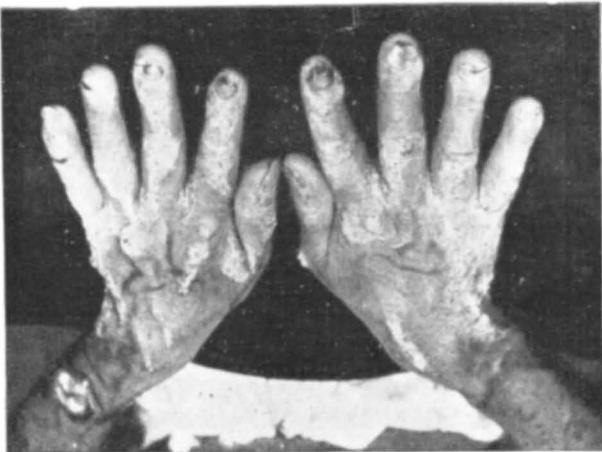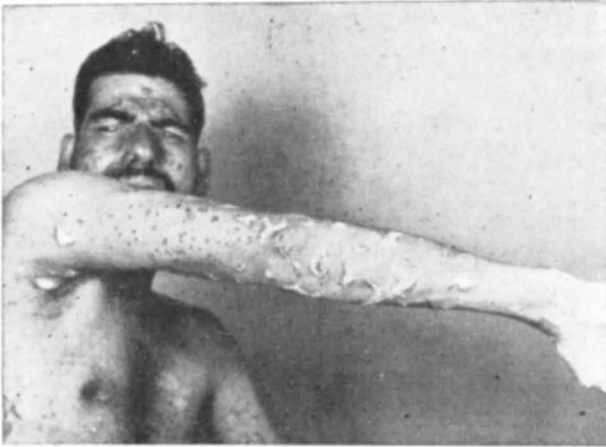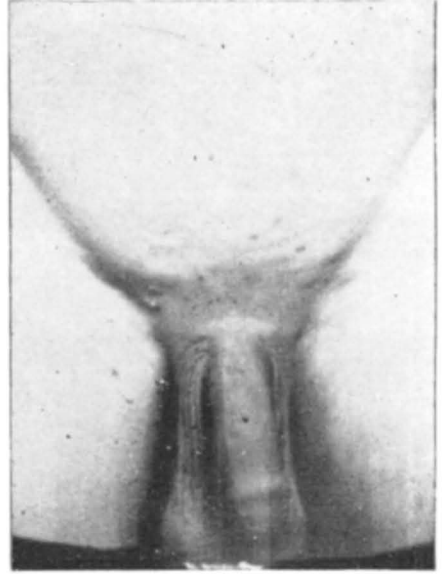


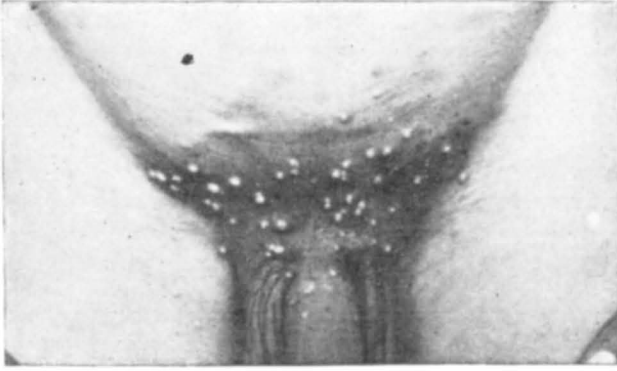GRISEOFULVIN THERAPY IN MOLLUSCUM
CONTAGIOSUM—T. R. Kapur



**WHAT IS YOUR
DIAGNOSIS ?**

Forty year old male patient had skin lesions of 19 years' duration. They started on the eye-brows and within an year involved most of the face and other parts of the body. Lesions were itchy.

Differential diagnosis :

1. Chronic Disseminate Discoid Lupus Erythematosus
2. Lichen Planus
3. Chronic Disseminate DLE with Onychomycosis

(Answer Page No. 79)