

A case of inflammatory breast carcinoma: Carcinoma erysipeloïdes

Sir,

Carcinoma erysipeloïdes (CE), which clinically resembles erysipelas, is an uncommon, but distinctive form of cutaneous metastasis. It has been termed inflammatory metastatic carcinoma. It classically presents as a rapidly evolving unilateral chest wall erythema, which may extend to the back, proximal part of the arm and even across the midline.^[1]

A 44-year-old woman was referred to our outpatient clinic with a one-month history of an asymptomatic erythematous plaque. Two years ago the patient had undergone a radical mastectomy for an infiltrating ductal carcinoma of the left breast. The patient was treated with radiotherapy and six cycles of intravenous chemotherapy comprising of cyclophosphamide, methotrexate and 5-fluorouracil (CMF regimen). Following the final cycle of chemotherapy, examination revealed the evidence of an erythematous plaque on the left chest wall. On physical examination, she was afebrile and had a large, ill-defined, indurated erythematous plaque affecting the skin of the left side of the chest wall extending to the back [Figure 1].

She was treated with intravenous antibiotic with the diagnosis of cellulitis, but after two different antibiotic regimens with no relief, other diagnostic entities were considered. A skin biopsy demonstrated an invasion of the dermal lymphatics by tumor cells accompanied

by edema and slight perivascular lymphoid infiltrate [Figure 2]. The histopathological findings supported the clinical diagnosis of CE. The patient did not respond to the current chemotherapeutical treatment (CMF regimen) and died eight months after diagnosis.

CE constitutes about one per cent of metastasis from breast cancer and is often considered a marker of tumor recurrence.^[2] Most of these patients have intraductal breast cancer, as in our case. The average life expectancy is two years from the time of diagnosis. The most common features of inflammatory breast carcinoma are erythema (51%), and a palpable breast mass (51%).^[3] The median duration of onset of inflammatory skin changes before the diagnosis of malignancy was 10 weeks.^[3] Dissemination is most likely to have occurred via a direct spread from the affected lymph nodes to the cutaneous lymphatics.^[3]

CE may rarely be the first sign of 'silent' tumor. Cox *et al.* described a case in which CE was the first sign of prostate carcinoma.^[3] This pattern is rarely seen with other organs such as lungs, thyroid, colon, rectum, prostate, larynx, gastric adenocarcinoma and malignant melanoma.

The other distinctive clinical patterns of metastasis almost exclusive to breast cancer include telangiectatic carcinoma and carcinoma en cuirasse. Carcinoma telangiectoides is manifested by red papules

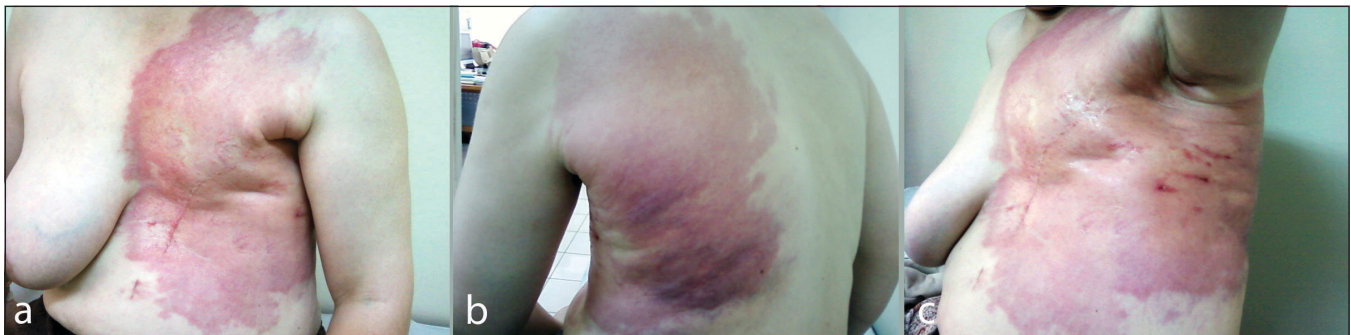

Figure 1: (a-c) Carcinoma erysipeloïdes caused by recurrent intraductal breast carcinoma. Erythematous plaque over the anterior chest wall extending to the back

How to cite this article: Canpolat F, Akpınar H, Eskiöğlü F, Genel N, Oktay M. A case of inflammatory breast carcinoma: Carcinoma erysipeloïdes. *Indian J Dermatol Venereol Leprol* 2010;76:215.

Received: April, 2009. **Accepted:** July, 2009. **Source of Support:** Nil. **Conflict of Interest:** None declared.

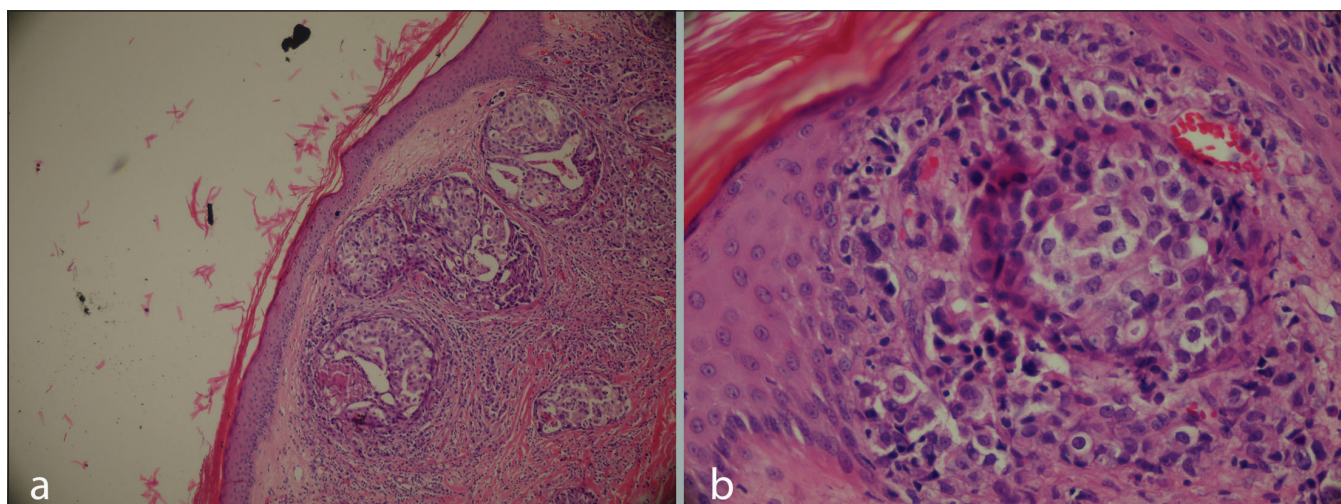


Figure 2: (a-b) Dermal lymphatics containing malignant cells (H and E, x40, x100)

and telangiectasias and carcinoma en cuirasse is manifested by dusky, translucent skin with an orange peel appearance which mimics morphea due to the associated induration.^[3]

The pathology of inflammatory carcinoma is distinctive with the deposition of tightly packed malignant cells within the superficial and deep lymphatics without the pathologic evidence of acute inflammation, such as neutrophils, although the lesions look clinically red and inflamed. Dermal lymphatic invasion is considered to be the hallmark of CE.^[4] Immunohistochemistry may prove invaluable in establishing the tissue of origin in inflammatory breast carcinoma. Ormsby *et al.* showed that gross cystic disease fluid protein-15 (GCDFFP-15) and estrogen receptor protein (ERP) are valuable markers for cutaneous metastatic breast carcinoma and they suggested that they should be used in combination.^[5]

Primary inflammatory carcinoma of the breast represents a diagnostic challenge, and delay in diagnosis is common. Erysipelas, cellulitis and radiation dermatitis are the differential diagnoses which should be considered.^[2] Our case also illustrates that CE could be misdiagnosed as cellulitis. There is no specific treatment for CE but, clinically, regression may be seen with anticancer therapy.

In conclusion, our case shows that CE, which is a marker of tumor recurrence in a patient with breast

carcinoma, suggests that immediate check-up is needed for early detection of recurrence of malignancy even if the patient has undergone chemotherapy. Awareness of the distinctive inflammatory manifestation of CE is essential for the dermatologists to establish an early diagnosis for the appropriate treatment.

**Filiz Canpolat, Hatice Akpınar, Fatma Eskioğlu,
Nebiye Genel, Murat Oktay**

Department of Dermatology, Ministry of Health Diskapi Yildirim
Beyazit Education and Research Hospital, Ankara, Turkey

Address for correspondence:

Dr. Filiz Canpolat, Salkim Söğüt Sokak 18-9 Dikmen,
06540 Çankaya, Ankara Turkey.
E-mail: filizcanpolat@hotmail.com

DOI: 10.4103/0378-6323.60543 - |

REFERENCES

1. Vega Gutiérrez J, Rodríguez MA. Carcinoma erysipeloides associated with breast carcinoma. *Int J Dermatol* 2007;46:613-614.
2. Gugle A, Malpathak V, Zawar V, Deshmukh M, Kote R. Carcinoma erysipeloides: an unusual presentation mimicking radiation dermatitis. *Dermatol Online J* 2008;14:26.
3. Cox SE, Cruz PD. A spectrum of inflammatory metastasis to skin via lymphatics: three cases of carcinoma erysipeloides. *J Am Acad Dermatol* 1994;30:304-7.
4. Nambi R, Tharakaram S. Carcinoma erysipeloides as a presenting feature of breast carcinoma. *Int J Dermatol* 1999;38:367-8.
5. Ormsby AH, Snow JL, Su WP, Goellner JR. Diagnostic immunohistochemistry of cutaneous metastatic breast carcinoma: a statistical analysis of the utility of gross cystic disease fluid protein-15 and estrogen receptor protein. *J Am Acad Dermatol* 1995;32:711-6.