

**Corresponding author:**

Dr. Kamar Belhareth,  
Department of Dermatology, Fattouma Bourguiba Hospital Monastir,  
Tunisia.  
kmar.belhareth@gmail.com

**References**

1. Topaloğlu Demir F, Karadag AS. Are dermatophytid reactions in patients with kerion celsi much more common than previously thought? A prospective study. *Pediatr Dermatol* 2015;32:635-40.
2. Ronjat L, Fermeiny M, Hadj-Rabia S, Boccara O, Bodemer C.

Generalized exanthematous pustular dermatophytid, a rare clinical presentation of dermatophytid reaction. *Ann Dermatol Venerol* 2015;142:270-5.

3. Liu ZH, Shen H, Xu AE. Severe kerion with dermatophytid reaction presenting with diffuse erythema and pustules. *Mycoses* 2011;54:e650-2.
4. Castriota M, Ricci F, Paradisi A, Fossati B, de Simone C, Capizzi R, *et al.* Erythema nodosum induced by kerion celsi of the scalp in a child: A case report and mini-review of literature. *Mycoses* 2013;56:200-3.
5. Cheng N, Rucker Wright D, Cohen BA. Dermatophytid in tinea capitis: Rarely reported common phenomenon with clinical implications. *Pediatrics* 2011;128:e453-7.

# Scrotal plaques as a predominant presentation in a case of secondary syphilis

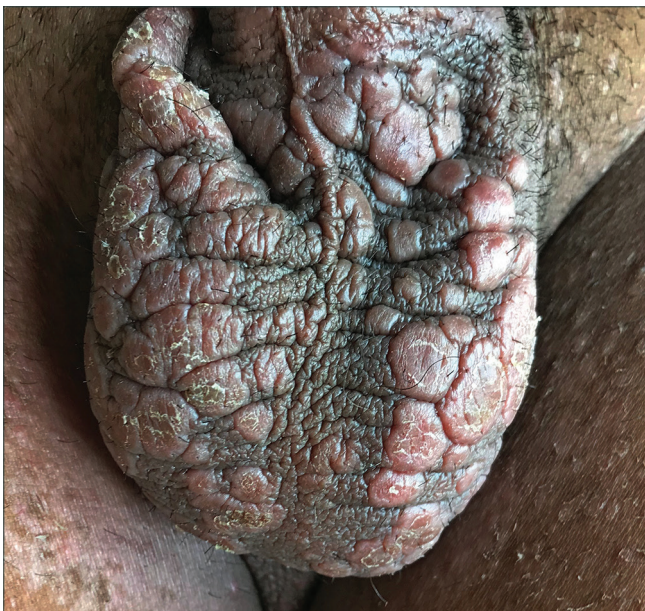Received: March, 2020  
Accepted: April, 2020  
Published: March, 2021

DOI:  
10.25259/IJDVL\_234\_20

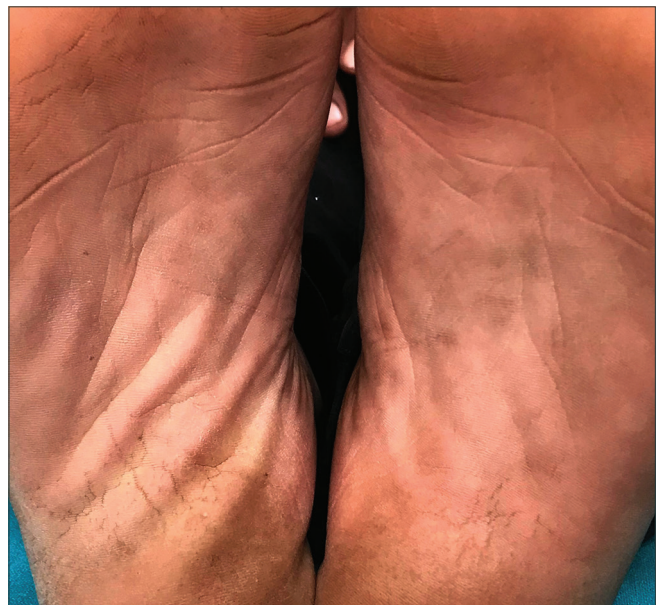PMID:  
\*\*\*\*\*

Sir,  
A 28-year-old male presented to the dermatology out-patient department with a 20-day history of multiple, mildly pruritic, erythematous lesions over the scrotum. There was a history of unprotected sexual exposure with a commercial sex worker in the 3 months back. General physical examination

and systemic examination revealed no significant abnormalities. Cutaneous examination showed multiple, erythematous, flat-topped, round to oval, firm, non-tender plaques distributed over the scrotum [Figure 1a]. A few pigmented macules were seen over the soles [Figure 1b]. Mucosal examination revealed no abnormal findings. A skin



**Figure 1a:** Multiple erythematous, flat-topped, round to oval plaques over the scrotum

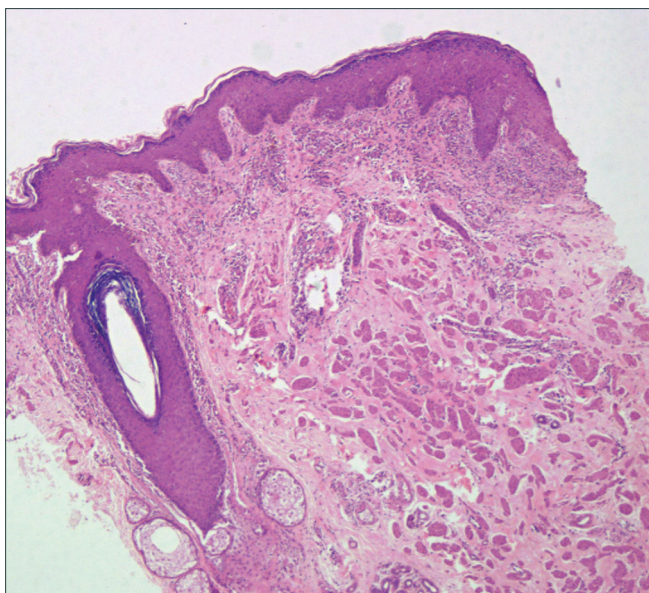


**Figure 1b:** A few pigmented macules over instep of soles

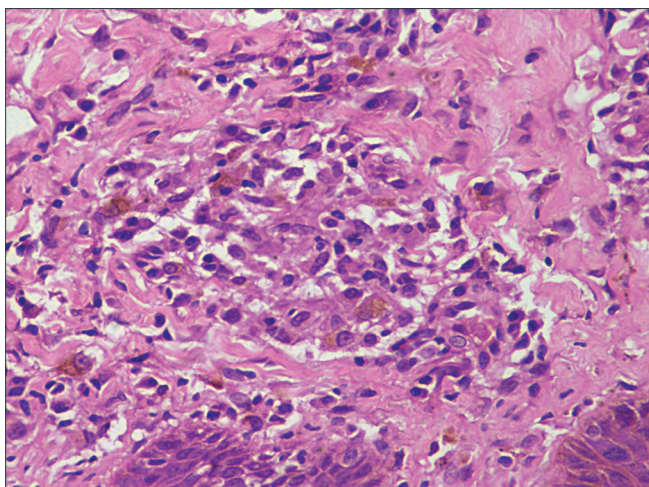
**How to cite this article:** Bains A, Tyagi N. Scrotal plaques as a predominant presentation in a case of secondary syphilis. *Indian J Dermatol Venereol Leprol* 2021;87:252-4.

This is an open-access article distributed under the terms of the Creative Commons Attribution-Non Commercial-Share Alike 4.0 License, which allows others to remix, tweak, and build upon the work non-commercially, as long as the author is credited and the new creations are licensed under the identical terms.





**Figure 2a:** Histopathology shows acanthosis along with perivascular chronic mononuclear inflammatory cells. (H&E, 4×)



**Figure 2b:** Higher magnification shows loose collection of histiocytes admixed with plasma cells in the dermis (H&E, 40×)

biopsy specimen from a lesion over the scrotum revealed perivascular lymphohistiocytic inflammation admixed with numerous plasma cells [Figure 2a and b]. A serology test revealed a reactive Venereal Disease Research Laboratory test with a titer of 1:32 and a positive *Treponema pallidum* hemagglutinin assay. Patient was treated with benzathine penicillin 2.4 million units IM which led to complete resolution of lesions at 4 weeks [Figure 2c].

Secondary syphilis is often called the “great imitator” as it can have a variety of clinical presentations. Lichenoid plaques on the scrotum and scrotal dermatitis have been rarely described in literature.<sup>1-6</sup> This case was interesting as he had no generalized rash, mucosal lesions or other systemic manifestations of secondary syphilis. Cases described with scrotal lesions had predominantly lichenoid morphology



**Figure 2c:** Resolution of scrotal lesions after treatment

along with the presence of other features of secondary syphilis.<sup>1,5</sup> A few patients had erythematous scaly plaques which were confused with eczema. Onset of the scrotal lesions preceded condyloma lata by several months in another patient.<sup>3</sup> In our case too, the scrotal lesions were the chief complaints and could be an early manifestation of secondary syphilis. However, further studies are required to conclude this finding. A few slightly pigmented asymptomatic macules over the palms and soles may remain unnoticed by the patient, especially in Indian skin. Hence, syphilis should be considered as an important differential diagnosis in patients presenting with scrotal lesions alone as it can mimic other dermatoses like lichen planus, psoriasis and eczema.

#### Declaration of patient consent

The authors certify that they have obtained all appropriate patient consent.

#### Financial support and sponsorship

Nil.

#### Conflicts of interest

There are no conflicts of interest.

**Anupama Bains, Neha Tyagi**

Department of Dermatology, Venereology and Leprology, AIIMS, Jodhpur, Rajasthan, India

#### Corresponding author:

Dr. Anupama Bains,  
Department of Dermatology, AIIMS, First Floor, OPD Building, Basni  
Phase 2, Jodhpur, Rajasthan, India.  
whiteangel2387@gmail.com

**References**

1. Singh PY, Radhakrishnan S, Neema S, Sinha A. Penile edema and lichenoid plaques on scrotum: An unusual presentation of secondary syphilis. *Indian Dermatol Online J* 2019;10:585-6.
2. Kumar P, Das A, Mondal A. Secondary syphilis: An unusual presentation. *Indian J Sex Transm Dis AIDS* 2017;38:98-9.
3. Jeong E, Oh ST, Lee JY, Cho BK. Secondary syphilis presenting as scrotal eczema. *J Am Acad Dermatol* 2007;57:1099-101.
4. Miguel-Gomez L, Vano-Galvan S, Segurado-Miravalles G, Garcia Del RC. Flesh-colored plaques on the scrotum. *J Am Acad Dermatol* 2015;72:e75-6.
5. Narang T, De D, Dogra S, Kanwar AJ, Saikia UN. Secondary syphilis presenting as annular lichenoid plaques on the scrotum. *J Cutan Med Surg* 2008;12:114-6.
6. Armijo D, Valenzuela F, Stevens J, Morales C. Lichenoid skin lesions: A rare manifestation in secondary syphilis. *Indian J Dermatol Venereol Leprol* 2020;86:105.

# Langerhans cell histiocytosis in an adult female with atypical swellings

Received: August, 2019  
 Accepted: April, 2020  
 Published: March, 2021

**DOI:**  
 10.25259/IJDVL\_651\_19

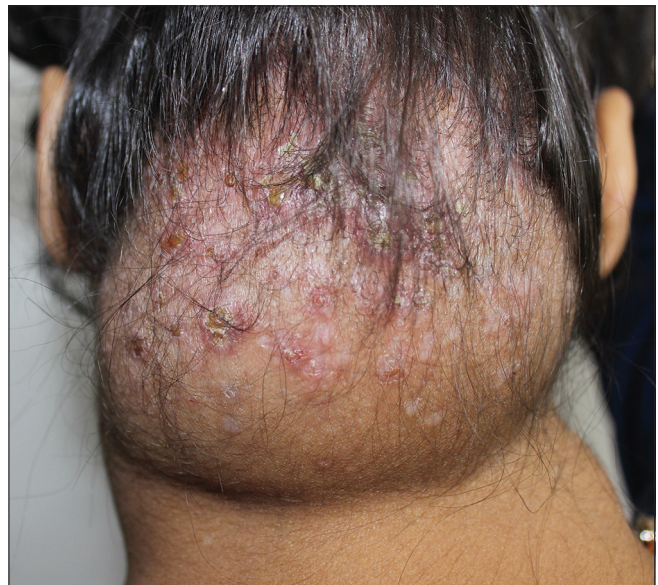**PMID:**  
 \*\*\*\*\*

Sir,  
 Langerhans cell histiocytosis rarely affects adults and is a diagnostic challenge owing to its varied clinical presentations. Treatment and prognosis depend on the organs involved. Cutaneous involvement is one of the common presentations and sometimes the first symptom to appear, giving the dermatologists a pivotal role to play in early diagnosis and management.<sup>1</sup> We hereby present the case of a young female with atypical swellings and crusted papules in seborrheic distribution.

A 25-year-old female presented to the dermatology out-patient department with a gradually progressive 8 × 8 cm soft swelling on nape of the neck, studded with papules and pustules, many covered with thin crust, for past 18–20 months [Figure 1]. Similar, but smaller, swellings were present on the axillae [Figures 2 and 3]. Papulopustules were also distributed on seborrheic areas of head and neck and a few lesions showed umbilication. She gave a history of similar swelling on the back 5 years ago that resolved spontaneously in 2 years. Loss of appetite and weight loss were present. The patient had received treatment for the same under the diagnosis of eczema, hidradenitis suppurativa, candidiasis and recurrent furuncles from multiple hospitals but was never relieved. There were no complaints of fever or any other systemic illnesses.

Differential diagnoses considered were lymphoma, Langerhans cell histiocytosis, hidradenitis suppurativa,

Rosai–Dorfmann disease, tuberculosis and histoplasmosis. The lesion on trunk was subjected to histopathology. Fine-needle aspiration cytology was done from swelling on the neck. Dense infiltrate in papillary dermis comprising of Langerhans cells having eosinophilic cytoplasm with coffee bean nuclei having vesicular chromatin and prominent nucleoli was found on histopathology which were positive for CD1a on immunohistochemistry [Figures 4-6]. Fine-needle aspiration cytology also showed similar picture of Langerhans cells [Figure 7].



**Figure 1:** Soft swelling on nape of neck studded with erythematous papules, many of them covered with yellowish crust

**How to cite this article:** Shukla P, Verma P, Kushwaha R, Verma S, Yadav G, Nazar AH. Langerhans cell histiocytosis in an adult female with atypical swellings. *Indian J Dermatol Venereol Leprol* 2021;87:254-9.

This is an open-access article distributed under the terms of the Creative Commons Attribution-Non Commercial-Share Alike 4.0 License, which allows others to remix, tweak, and build upon the work non-commercially, as long as the author is credited and the new creations are licensed under the identical terms.