

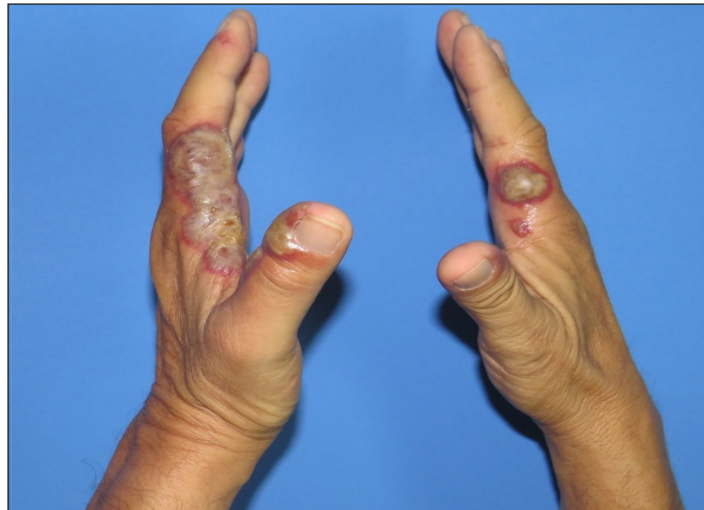## Acute erythematous pustular plaques on the hands triggered by driving

A 67-year-old taxi driver with type 2 diabetes and systemic hypertension, presented with a 2-week history of symmetrical edematous dusky erythematous plaques with overlying bullae on both hands [Figure 1]. The patient denied any personal history of medications, recent infections, weight loss, or other relevant skin manifestations. Further questioning revealed

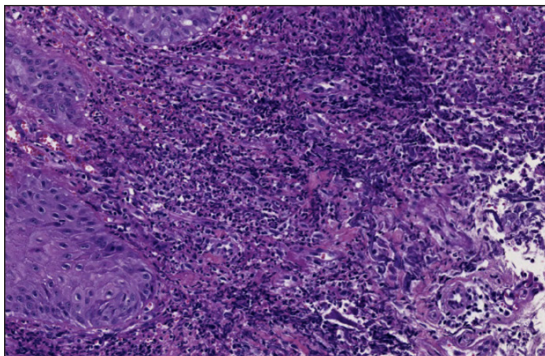
that he spent a significant amount of his time driving, applying constant pressure in the areas of the lesions. A skin biopsy was taken for histopathological examination [Figure 2].

### Question

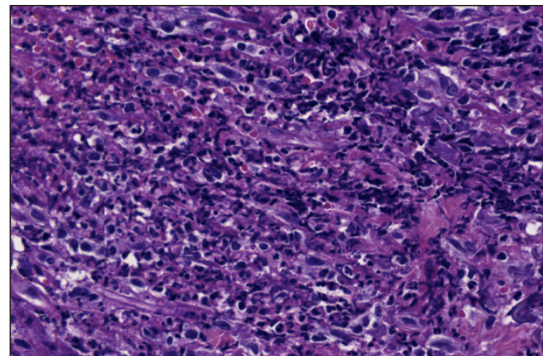
What is your diagnosis?



**Figure 1:** Symmetrical edematous violaceous plaques and bullae on both hands.



**Figure 2a:** Dense dermal neutrophilic infiltrate (Haematoxylin and eosin stain, x40).



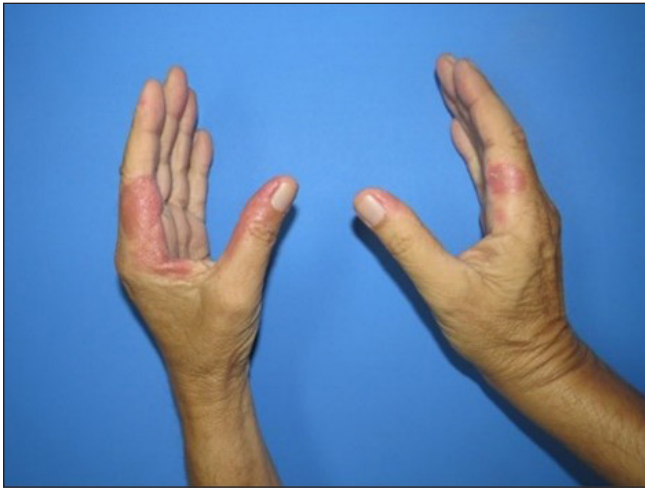**Figure 2b:** Dense dermal neutrophilic infiltrate (Haematoxylin and eosin stain, x100).

**How to cite this article:** Luna-Garza DK, Aguilar-Calderón PE, Rodríguez-Tamez G, Brown-Herrera A, Brussolo-Marroquin E, Ocampo-Candiani J, *et al.* Acute erythematous pustular plaques on the hands triggered by driving. *Indian J Dermatol Venereol Leprol.* doi: 10.25259/IJDVL\_1143\_2023

**Received:** October, 2023 **Accepted:** December, 2023 **Epub Ahead of Print:** May, 2024

**DOI:** 10.25259/IJDVL\_1143\_2023

This is an open-access article distributed under the terms of the Creative Commons Attribution-Non Commercial-Share Alike 4.0 License, which allows others to remix, tweak, and build upon the work non-commercially, as long as the author is credited and the new creations are licensed under the identical terms.



**Figure 3:** Improvement of neutrophilic dermatosis of dorsal hands after treatment.

### Answer

Diagnosis: Neutrophilic dermatosis of the dorsal hands (NDDH)

### Investigations and follow-up

Histopathology revealed slight spongiosis in the epidermis, and dense neutrophilic infiltrate with focal leukocytoclasia in the reticular dermis [Figure 2]. A diagnosis of neutrophilic dermatosis of the dorsal hands (NDDH) was established. Blood tests revealed a borderline elevated C reactive protein (CRP) (6.35 mg/L; normal range 1–3) with remaining parameters within normal ranges. Malignancy screening revealed the absence of any neoplastic processes. Treatment with prednisone, 40 mg daily, was started in a tapering regimen for 4 weeks, resulting in complete resolution at the 2-month follow-up [Figure 3].

### Discussion

Neutrophilic dermatosis of the dorsal hands (NDDH) was categorised as a localised variant of Sweet syndrome by Galaria *et al.*<sup>1</sup> in the year 2000. It was first described as ‘pustular vasculitis’ by Strutton *et al.* in 1995, who presented six patients with similar Sweet syndrome-like histopathological and clinical features limited to the dorsa of hands.<sup>2</sup>

Neutrophilic dermatosis comprises a group of skin disorders characterised by a dense dermal, epidermal, and/or subcutaneous neutrophilic infiltrate. Lesions are mostly located on the dorsum of the hands, nonetheless, they may present in other locations.<sup>1</sup> They manifest as papules, nodules, plaques, bullae, and pustules, and may be associated with necrosis and ulceration giving an infectious appearance.<sup>2</sup> Hence, being a relatively new entity, it may be mistreated with antibiotics or unnecessary procedures.

When assessing a patient exhibiting cutaneous manifestations resembling NDDH, it is essential to explore a spectrum

of differential diagnoses due to the overlapping clinical features. The differential diagnosis ranges from herpetiform dermatitis, erysipelas, erythema elevatum diutinum, contact dermatitis, pyoderma gangrenosum, dyshidrotic eczema, infections, or palmoplantar pustulosis.<sup>3,4</sup> In the present case, our differentials were contact dermatitis or neutrophilic dermatosis.

The diagnosis is established on histopathology characterised by the presence of a dense neutrophilic infiltrate in the dermis. Moreover, it is pathologically classified as a variant of Sweet syndrome with indistinguishable histological findings.<sup>3</sup>

Most patients have a history of triggering traumas, such as gardening injuries, cooking burns, intravenous line insertions, and intravenous drug use, which present within 7–10 days after the event. Furthermore, it is crucial to intentionally interrogate for a history of trauma, as the pathergy phenomenon is described in other neutrophilic disorders.<sup>5</sup>

Some haematological disorders, recent infections, solid organ tumours, and inflammatory bowel disease have been associated with NDDH. Therefore, a thorough systematic evaluation with full blood count and serum protein electrophoresis is recommended to exclude any associated diseases. The first-line treatment is systemic steroids. However, many cases have been successfully treated with topical steroids.<sup>3</sup>

### Declaration of patient consent

The authors certify that they have obtained all appropriate patient consent.

### Financial support and sponsorship

Nil.

### Conflicts of interest

There are no conflicts of interest.

### Use of artificial intelligence (AI)-assisted technology for manuscript preparation

The authors confirm that there was no use of artificial intelligence (AI)-assisted technology for assisting in the writing or editing of the manuscript and no images were manipulated using AI.

**Debanhi K. Luna-Garza,  
Patrizia E. Aguilar-Calderón,  
Giselle Rodriguez-Tamez, Alejandra Brown-Herrera,  
Elizabeth Brussolo-Marroquin,  
Jorge Ocampo-Candiani, Erika L. Alba-Rojas**

Department of Dermatology, Hospital Universitario Dr. José Eleuterio González, Universidad Autónoma de Nuevo León, Av. Madero and Gonzalitos Mitras Centro, Monterrey, Mexico

**Corresponding author:**

Dr. Erika L Alba-Rojas,

Department of Dermatology, Hospital Universitario Dr. José Eleuterio González, Universidad Autónoma de Nuevo León, Av. Madero and Gonzalitos Mitras Centro, Monterrey-64460, Mexico.  
eri9ar@yahoo.com

**References**

1. Galaria NA, Junkins-Hopkins JM, Kligman D, James WD. Neutrophilic dermatosis of the dorsal hands: Pustular vasculitis revisited. *J Am Acad Dermatol* 2000;43:870–4.
2. Strutton G, Weedon D, Robertson I. Pustular vasculitis of the hands. *J Am Acad Dermatol*. 1995;32:192–8.
3. Micallef D, Bonnici M, Pisani D, Boffa MJ. Neutrophilic dermatosis of the dorsal hands: A review of 123 cases. *J Am Acad Dermatol* 2023;88:1338–44.
4. Byun JW, Hong WK, Song HJ, Han SH, Lee HS, Choi GS, *et al.* A case of neutrophilic dermatosis of the dorsal hands with concomitant involvement of the lips. *Ann Dermatol* 2010;22:106–9.
5. Gloor AD, Feldmeyer L, Borradori L. Neutrophilic dermatosis of the dorsal hands triggered by mechanical trauma. *J Eur Acad Dermatol Venereol* 2021;35:20–1.