

Efficacy of red light alone and methylaminolaevulinate-photodynamic therapy for the treatment of mild and moderate facial acne

Cristian Pinto, Fabiola Schafer, Juan Jose Orellana¹, Sergio Gonzalez², Ariel Hasson³

Department of Medical Specialties, Facultad de Medicina, Universidad de La Frontera, Temuco, Chile,
¹Department of Public Health, Facultad de Medicina, Universidad de La Frontera, Temuco, Chile, Clinical Epidemiology Research and Training Center (CERTC), Public Health Doctoral Student, Universidad de Chile, Santiago, Chile, ²Department of Anatomic Pathology, ³Dermatology, Facultad de Medicina, Pontificia Universidad Católica de Chile, Santiago, Chile

Address for correspondence:

Dr. Fabiola Schafer,
 Department of Medical Specialties, Facultad de Medicina, Universidad de La Frontera, Claro Solar St, Temuco, Chile.
 E-mail: fdschafe@gmail.com

ABSTRACT

Background: Photodynamic therapy (PDT) has been shown to be an effective alternative for acne. However, there is little information comparing the efficacy of red light alone and methyl aminolaevulinate (MAL)-PDT. **Aims:** To compare the efficacy and tolerability of red light alone and MAL-PDT in patients with mild to moderate facial acne. **Methods:** Thirty six patients with mild to moderate acne were enrolled. Eighteen patients received MAL-PDT and 18 received red light alone in two sessions, 2 weeks apart. Acne grade and lesion counts were assessed by blinded evaluators at baseline, 2, 4 and 10 weeks. **Results:** At week 2, clinical improvement from acne grade II-IV to 0-I was observed in 82.3% of MAL-PDT group and 14.2% of red light alone group. Red light alone group had a gradual clinical improvement over time with a 77% response at week 10. In contrast, MAL-PDT group had a rapid clinical improvement with total response at week 10. Both treatments were significantly effective for improving acne lesions. However, MAL-PDT group had a greater response ($P < 0.001$). Histologically, decreased amounts of sebocytes and lipids along with atrophic sebaceous glands were observed after MAL-PDT. **Conclusion:** MAL-PDT has a quicker onset of action with a higher response than red light alone. MAL-PDT may induce a reduction in the size of the sebaceous glands and then long-term acne remission.

Key words: Acne vulgaris, methyl aminolevulinate, photodynamic therapy, red light

INTRODUCTION

Acne vulgaris is a common, chronic inflammatory skin disease that affects mainly adolescents and young adults.^[1] There is a wide variety of acne treatments, which reflects the complex and multifactorial pathogenesis of acne. Conventional therapies such as retinoids, benzoyl peroxide and antibiotics are

the cornerstone for acne treatment. However, these therapies may not be effective in some cases, leading to refractory acne. In addition, propionibacterial resistance to antibiotics has been increasing over the last years, leading to the constant changing of the guidelines for acne management.^[2] Furthermore, cutaneous and systemic side effects including birth defects are important issues stemming from the use of oral isotretinoin. Therefore, alternative treatments are being studied.

Light therapies such as photodynamic therapy (PDT) have been taking an important place in dermatological practices. These procedures may offer alternatives to people who seek topical treatments, quicker onset of action, non-serious side effects and decreased

Access this article online	
Quick Response Code:	Website: www.ijdvl.com
	DOI: 10.4103/0378-6323.104673

How to cite this article: Pinto C, Schafer F, Orellana JJ, Gonzalez S, Hasson A. Efficacy of red light alone and methyl-aminolaevulinate-photodynamic therapy for the treatment of mild and moderate facial acne. Indian J Dermatol Venereol Leprol 2013;79:77-82.

Received: May, 2012. **Accepted:** August, 2012. **Source of Support:** Nil. **Conflict of Interest:** None declared.

antibiotic resistance rates.

The use of light therapy comes from the fact that *Propionibacterium acnes*, anaerobic and commensal bacteria on human skin produce endogenous porphyrins, particularly coproporphyrin III (CPIII). Porphyrins may contribute to the inflammatory reaction by producing cytotoxic effects in the sebaceous glands.^[3,4] On the other hand, benefits from the photosensitizing effect of endogenous porphyrins have been described with exposures to blue and/or red light sources. These studies have been shown to reduce 49-75% of inflammatory lesions in treated patients versus 10-25% in untreated patients.^[5-7] Also, acne can respond well to photodynamic therapy using topical porphyrin precursors such as 5-aminolaevulinic acid (ALA) or methyl aminolevulinate (MAL). Photoactivated porphyrins produce the formation of singlet oxygen and other potent oxidizers that induce transient antimicrobial and anti-inflammatory effects.^[8] Moreover, red light ALA-PDT has been proven to cause a direct photodynamic destruction of sebaceous glands and then long-term remission of acne.^[9] Even though MAL-PDT has been shown to be as effective as antibiotics with a 68% reduction in the number of inflammatory lesions,^[10] there is little information comparing the efficacy of red light alone and MAL-PDT treatment.

Therefore, our aim was to compare the efficacy and tolerability of red light alone and MAL-PDT in patients with mild to moderate facial acne. In addition, we investigated the pattern of treatment response for each treatment.

METHODS

Patients

Thirty-six patients participated in the study. The protocol was approved by the local ethics committee of the Pontificia Universidad Catolica de Chile and patients signed an informed consent. Patients were recruited from the Department of Dermatology, at the Pontificia Universidad Catolica de Chile from August 2009 to January 2010. An interview was conducted with each patient to determine age, gender, acne grade and medical prescriptions. All patients were older than 15 years of age and had a total of at least 10 inflammatory facial acne lesions. Acne severity grade was classified into mild or moderate facial acne. Patients did not have a history of topical and oral acne

treatment within 3 and 6 months of the initiation of the study, respectively. However, all patients had previously been treated with topical retinoids and oral/topical antibiotics. They had relapses and did not respond to this therapy. Also, some women did not want to take oral isotretinoin due to the risk of birth defects.

Treatment

Patients participated in a controlled, investigator-blinded trial. Patients were assigned to MAL-PDT or red light alone group. Dermatologists blinded to treatment evaluated the patients in every follow-up visit. We used a commercial MAL cream 160 mg g⁻¹ ((Metvix[®], Laboratory Galderma S.A.) plus red light on one group (18 patients) and red light alone on the other group (18 patients). MAL cream was applied in a 1-mm-thick layer on the whole face (excluding the nose and a 1-cm periocular area). MAL cream was covered with a light impermeable dressing for 90 min and then, both groups were illuminated with non-coherent red light from a Waldman[®] PDT 1200 lamp (average wavelength 635 nm, light dose 37 J/cm² and a fluence rate of approximately 70 mW/cm²) for 9 min. Both treatments were repeated two times, 2 weeks apart.

Evaluation

Patients received either red light alone or MAL-PDT treatment at baseline (0 day) and week 2. They were evaluated at baseline and week 2, 4 and 10. Acne severity grade, inflammatory and non-inflammatory lesions were measured at baseline and at every follow-up visit.

Acne severity grade was evaluated using a six-point rating scale. According to the grading scale,^[11] treatment was considered successful when patients achieved grade 0 or I and unsuccessful treatment with grade II to V. In addition, a skin biopsy was performed on one patient in order to analyze morphologic changes of the sebaceous glands.

Furthermore, patients were asked to evaluate their pain during illumination and after treatment. Pain was assessed by means of a numeric scale ranging from 0 to 10 in which 0 is no pain and 10 is the worst imaginable pain. Any other side effects were assessed. Clinical photographs were taken before and after treatment and at every follow-up visit. Patients were also contacted by telephone and e-mail in order to

avoid withdrawal from the study.

Statistical Analysis

The sample size was calculated assuming a reported efficacy in reducing acne lesions at the end of the treatment of 75% and 30% for MAL-PDT and red light alone, respectively.^[10-15] With regard to a statistical significant level of 0.05 and a statistical power of 80%, 18 patients on each group were needed.

Statistical summaries using frequency tables, graphs and statistics such as ranks, percentiles, averages and standard deviation were used to describe the study groups.

Inferential analyses were carried out by means of non-parametric tests (Wilcoxon rank-sum and Fisher's exact test). The statistical model used was GEE for repeated measurements using as a link function the logarithmic function, the family distribution of the dependent variables (number of inflammatory and non-inflammatory lesions was the Poisson distribution) and as a correlation matrix the unstructured matrix. For the dichotomized variable level of acne 0-1/2-4, the family distribution was binomial and the link function was the Inverse Gaussian Cumulative instead of logarithmic because with this function the convergence was not achieved.

RESULTS

Baseline Characteristics

Baseline characteristics for each group are shown in [Table 1]. Both groups had no statistical differences

Table 1: Baseline characteristics of patients

Variable		Red light alone	MAL-PAD	P-value
Gender	Male %	44.4	27.8	0.489
Age	Mean	20.7	22.1	0.763
	SD	3.79	5.76	
Previous treatment	%	58.8	72.2	0.489
Acne severity grade	GI%	22.2	5.6	0.001
	GII%	55.6	11.1	
	GIII%	16.7	72.2	
	GIV%	5.6	11.1	
Number of non-inflammatory lesions	min-max	7-45	15-65	0.0379
	p25-p25	17-32	23-44	
	Median	24	33	
Number of inflammatory lesions	min-max	5-55	4-70	0.0003
	p25-p25	5-20	50-60	
	Median	15	52	

in age distribution, gender and history of previous treatment ($P > 0.05$). The average of age was 20.7 (± 3.8) and 22.1 (± 5.8) in the red light alone and MAL-PDT group, respectively. 16.7% and 72.2% of the patients had moderate facial acne (grade III) in the red light alone and MAL-PDT group, respectively ($P = 0.001$). The median of inflammatory lesion counts was 15 and 52 for the red light alone and MAL-PDT group, respectively ($P = 0.0003$). The median of non-inflammatory lesion counts was 24 and 33 for the red light alone and MAL-PDT group, respectively ($P = 0.038$).

Efficacy

Observed efficacy

Clinical improvement was seen 2 weeks after the first MAL-PDT treatment; 82.3% of the patients who had grade II-IV achieved grade 0-I. The median and median percent reduction (%) of inflammatory lesion counts decreased from 52 to 5 (91.3%), 4 (94%) and 0.5 (99.3%) at week 2, 4 and 10, respectively [Figure 1]. The median and median percent reduction (%) of non-inflammatory lesion counts decreased from 33 to 30 (12.8%), 21.5 (39.4%) and 13.5 (64.5%) at week 2, 4, and 10, respectively [Figure 2]. At week 10, 100% of the patients achieved grade 0-I [Figure 3].

In the red light alone group, 14.2% of the patients who had grade II-IV achieved grade 0-I at week 2. The median and median percent reduction (%) of inflammatory lesion counts decreased from 15 to 11.5 (0%), 5.5 (21.4%) and 5.0 (64.1%) at week 2, 4 and 10, respectively [Figure 1]. The median and median percent reduction (%) of non-inflammatory lesions decreased from 24 to 22.5 (11.3%), 18.5 (25.9%) and 15 (35.1%) at week 2, 4, and 10, respectively [Figure 2]. At week 10, 77.7% of the patients achieved grade 0-I [Figure 4].

Inference analysis

According to GEE analysis, both treatments showed a significant response by reducing the number of inflammatory and non-inflammatory lesions at every follow-up visit from baseline. However, MAL-PDT group had a greater response than the red light alone group ($P < 0.001$; GEE model). For each treatment, the expected probability to achieve acne grade 0 or I, and the number of expected inflammatory and non-inflammatory lesions (SD) at week 2, 4 and 10 are shown in Table 2.

Adverse effects

Side effects were pain, erythema and epithelial exfoliation. After the first treatment, the median pain

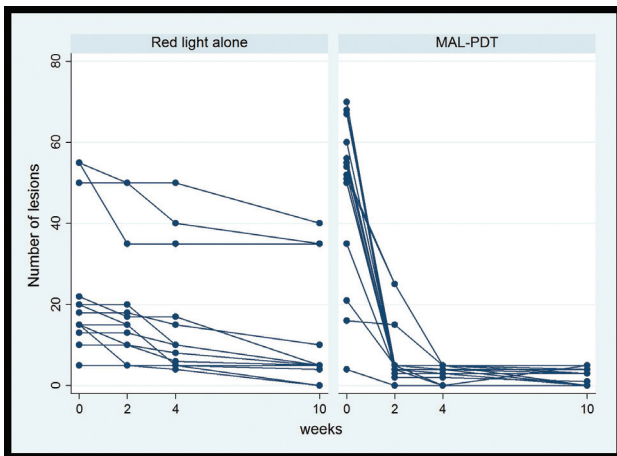


Figure 1: Variation of the number of inflammatory lesions at baseline and follow-up visits after each treatment

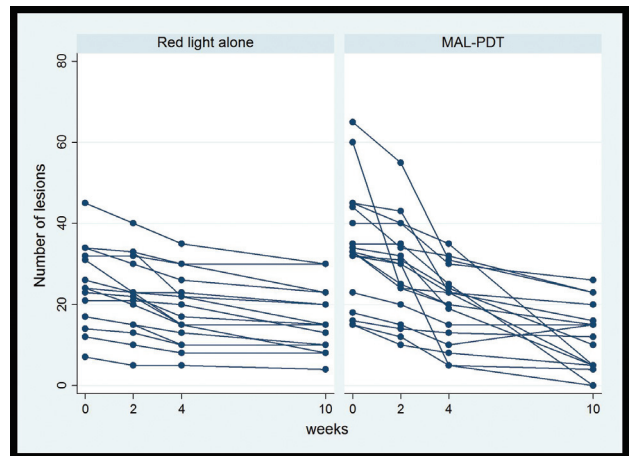


Figure 2: Variation of the number of non-inflammatory lesions at baseline and follow-up visits after each treatment

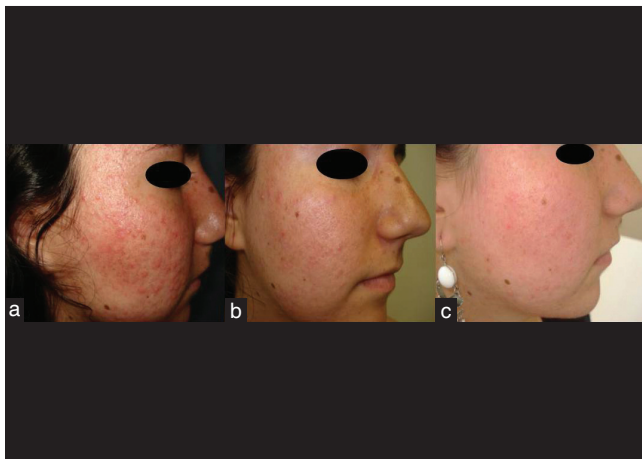


Figure 3: Clinical photographs of a patient with acne grade III, treated with methyl-aminolevulinat-photodynamic therapy at (a) baseline, (b) week 4 and (c) week 10

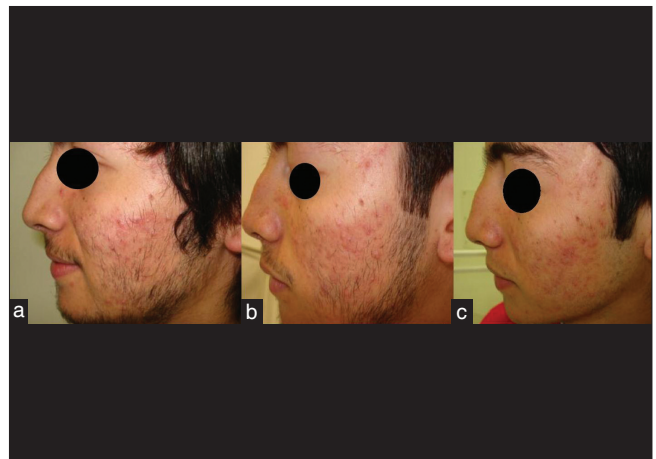

Figure 4: Clinical photographs of a patient with multiple acne scars and inflammatory lesions corresponding to acne grade III, treated with red light alone at (a) baseline, (b) week 4 and (c) week 10

Table 2: Distribution of the expected number of inflammatory and non-inflammatory lesions and the expected percentage of acne severity grade at week 2, 4 and 10

Type of lesions	Treatment	0	2	4	10
Inflammatory	Red light alone	19.3 [17.4-21.5]	16 [13.2-19.4]	13.1 [10.9-15.7]	9.9 [8.2-12]
	MAL-PDT	48.8 [38.8-61.4]	7 [4.3-11.4]	3.1 [1.8-5.3]	1.8 [1-3.3]
Non-inflammatory	Red light alone	24.7 [22.5-27.1]	22.4 [19.6-25.6]	18.8 [16.1-22]	16.1 [13.3-19.5]
	MAL-PDT	34.3 [27.7-42.6]	28.6 [21-38.9]	20.1 [14-28.8]	11.9 [7.5-18.9]
Acne grade II-IV	Red light alone	77.7%	66.9%	50.3%	22.2%
	MAL-PDT	95%	18.6%	0.1%	0%
Acne grade 0-I	Red light alone	22.3%	33.1%	49.7%	77.8%
	MAL-PDT	5%	81.4%	99.9%	100%

score was 2 (inter-quartile range 1-3) and 3 (IQR 2-7) for red light alone and MAL-PDT group, respectively ($P = 0.0002$). After the second treatment, the median pain score was 1 (IQR 1-3) and 5 (IQR 0-7) for red light

alone and MAL-PDT group, respectively ($P < 0.001$). There were no statistical differences in erythema after the first treatment in both groups, however; MAL-PDT patient group had more moderate and severe

erythema after the second treatment ($P = 0.012$).

A skin biopsy was performed on one patient with moderate inflammatory acne treated with MAL-PDT. In order to analyze morphologic changes of the sebaceous glands, the skin biopsy was taken at baseline (0 day) and seven days after the last MAL-PDT treatment. Both biopsies were taken from her right cheek. At baseline, the sebaceous gland morphology had a conserved structural pattern and its sebum concentration was normal [Figure 5a]. After MAL-PDT treatment, histopathological findings revealed decreased amounts of sebocytes, reduced amounts of lipids (green color), and atrophic sebaceous glands [Figure 5b].

DISCUSSION

This study shows that red light MAL-PDT treatment has a rapid onset of action. At week 2, 82.3% of the patients with grade II-IV achieved grade 0-I. Also, the median of inflammatory lesions decreased from 52 to 5 with a median percent reduction of 91.3%. In contrast, only 14.2% of the patients with grade II-IV achieved grade 0-I in the red light alone group. However, both treatments were significantly effective for improving inflammatory and non-inflammatory lesions. Interestingly, patients from the red light alone group had a gradual clinical improvement over time. In contrast, patients from MAL-PDT group had a rapid

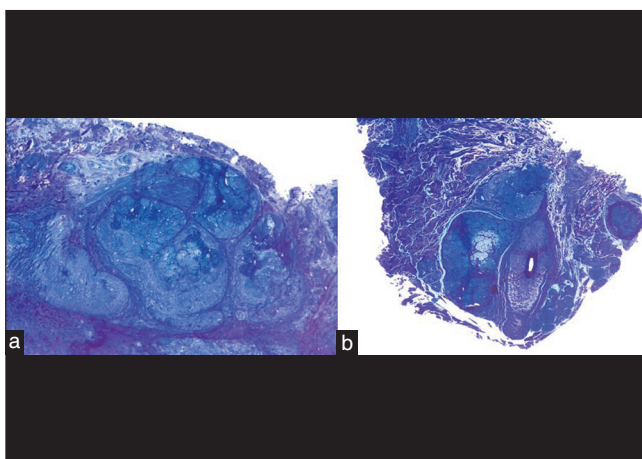


Figure 5: Evaluation of sebaceous gland morphology and its sebum concentration before and after MAL-PDT treatment. (a) Normal architectural pattern of sebaceous glands and follicles with a normal amount of lipids (green color) (toluidine blue staining, original magnification $\times 200$). (b) A smaller size of the sebaceous glands with a reduced number of sebocytes in their central area along with a reduced amount of lipids (green color) (toluidine blue staining, $\times 200$)

clinical improvement with total response at week 10.

This study shows that both treatments significantly reduce acne severity at 10 weeks of follow-up visits, but MAL-PDT has a quicker onset of action with a higher response than red light alone. Hence, red light plus topical porphyrin precursors enhance the phototherapeutic effects with an earlier clinical improvement.

Also of interest, the red light alone group showed a significant reduction in inflammatory and non-inflammatory lesions. Interestingly, Na *et al.* assessed the efficacy of red light phototherapy using a portable device in facial acne.^[12] Eight weeks after treatment, the percent reduction of total lesions was significantly higher in the treated side (55% reduction) compared to the control side (19% increase). This study also showed the beneficial effect of red light on inflammatory acne, which has been attributed to greater skin penetration and greater sensitivity of *P. acnes* and sebaceous glands to photodestruction.^[13] This mechanism may explain the significant clinical response of the red light alone group of our study.

Even though the MAL-PDT group had more patients with severe acne, it showed a better response than the red light alone group. This better response is supported by other studies. As such, a study of MAL-PDT and placebo-PDT using red light (37 J/cm^2) showed a median percent reduction in inflammatory lesions of 54% and 20% at 12 weeks after treatment, respectively.^[11] Other reports from red light MAL-PDT studies have been shown to reduce 59% to 68% of inflammatory lesions at 12 weeks after treatment.^[10-14] In addition, Riddle *et al.* showed an analysis of 8 trials and 13 case series related to PDT and acne. All reported reduction in inflammatory lesions of 25-88%, with consistent superiority of PDT over light alone.^[15] However, these studies used different light dosimetry and irradiance, skin preparation and drug incubation time. To date, non-uniform parameters are being used for wavelength, light dosimetry, skin preparation, type of precursor and concentration and time of incubation. Therefore, there is no consensus on how to perform PDT for acne treatment. Surely, the modification of these variables may affect the efficacy and side effects. Thus, guidelines for PDT in acne therapy are warranted.

Histological changes such as reduced numbers of sebocytes, reduced amounts of lipids (green color)

and a smaller size of sebaceous glands were found in a patient with moderate acne treated with MAL-PDT. For PDT activation, high intensity red light sources have a deeper penetration than blue light sources (Tyndall effect), and are more likely to reach and activate porphyrins in sebaceous glands.^[13] This mechanism can produce sebaceous gland destruction and probably a longer remission of acne. Also, red light PDT can induce a reduction in the size and/or function of the sebaceous glands. Theoretically, this effect can be reversible or more permanent depending on the number of treatment sessions. As such, Hongcharu *et al.* conducted a study of acne patients treated with red light ALA-PDT.^[9] The authors reported that sebum excretion was eliminated clinically, and this effect lasted for at least 20 weeks after multiple treatment sessions and 10 weeks after a single treatment. Also, histological findings such as vacuolization of sebocytes and sustained atrophic glands were observed. However, due to the fact that our histopathological findings are based on only one biopsy taken from one patient, we cannot generalize this information to the other patients.

It seems that red light sources in repeated treatment sessions may produce a higher and longer efficacy along with suppression of sebaceous gland functions. As such, this approach would be as efficient as oral retinoids in targeting the sebaceous glands. This theory will be unraveled when PDT is optimized with long-term clinical trials.

In addition, side effects such as pain, erythema and epithelial exfoliation were reported in our study. MAL-PDT treatment was associated with more pain and erythema than red light alone treatment. Intra-group analyses showed that MAL-PDT patients had more severe pain after the second treatment. This situation may be explained by the fact that after illumination there is a superficial burn on the skin surface. Inflammation and epidermal turnover are presented in the damaged skin, so when the second treatment is applied, the skin is thinner and signs of inflammation and epidermal exfoliation can be seen. As such, the skin is more sensitive to illumination, which increases pain and erythema. These side effects have also been reported in other studies.^[16,17] On the other hand, sterile pustular eruption was not seen in any patients.

Taking into account that non-uniform parameters are being used for PDT treatment, there is a need to optimize

the treatment protocol to ensure a better result with a long-term acne remission. The results from our study indicate that red light MAL-PDT and red light alone are significantly effective for improving inflammatory and non-inflammatory lesions. Nevertheless, red light MAL-PDT has a quicker onset of action and a higher response than red light alone.

REFERENCES

1. Webster GF. Acne vulgaris. *BMJ* 2002;325:475-9.
2. Williams HC, Dellavalle RP, Garner S. Acne vulgaris. *Lancet* 2012;379:361-72.
3. Issa MC, Manela-Azulay M. Photodynamic therapy: A review of the literature and image documentation. *An Bras Dermatol* 2010;85:501-11.
4. Lee Y, Baron ED. Photodynamic Therapy: Current Evidence and Applications in Dermatology. *Semin Cutan Med Surg* 2011;30:199-209.
5. Kawada A, Aragane Y, Kameyama H, Sangen Y, Tezuka T. Acne phototherapy with a high-intensity, enhanced, narrow-band, blue light source: An open study and *in vitro* investigation. *J Dermatol Sci* 2002;30:129-35.
6. Elman M, Slatkine M, Harth Y. The effective treatment of acne vulgaris by a high-intensity, narrow band 405-420 nm light source. *J Cosmet Laser Ther* 2003;5:111-7.
7. Smith EV, Grindlay DJ, Williams HC. What's new in acne? An analysis of systematic reviews published in 2009–2010. *Clin Exp Dermatol* 2010;36:119-23.
8. Sakamoto FH, Lopes JD, Anderson RR. Photodynamic therapy for acne vulgaris: A critical review from basics to clinical practice. Part I. Acne vulgaris: When and why consider photodynamic therapy? *J Am Acad Dermatol* 2010;63:183-93.
9. Hongcharu W, Taylor CR, Chang Y, Aghassi D, Suthamjariya K, Anderson RR. Topical ALA-photodynamic therapy for the treatment of acne vulgaris. *J Invest Dermatol* 2000;115:183-92.
10. Wiegell SR, Wulf HC. Photodynamic therapy of acne vulgaris using methyl aminolaevulinate: A blinded, randomized, controlled trial. *Br J Dermatol* 2006;154:969-76.
11. Hörfelt C, Funk J, Frohm-Nilsson M, Wiegell Edström D, Wennberg AM. Topical methyl aminolaevulinate photodynamic therapy for treatment of facial acne vulgaris: Results of a randomized controlled study. *Br J Dermatol* 2006;155:608-13.
12. Na JI, Suh DH. Red light phototherapy alone is effective for acne vulgaris: randomized, single-blinded clinical trial. *Dermatol Surg* 2007;33:1228-33.
13. Sakamoto FH, Torezan L, Anderson RR. Photodynamic therapy for acne vulgaris: A critical review from basics to clinical practice. Part II. Understanding parameters for acne treatment with photodynamic therapy. *J Am Acad Dermatol* 2010;63:195-211.
14. Wiegell SR, Wulf HC. Photodynamic therapy of acne vulgaris using 5-aminolevulinic acid versus methyl aminolaevulinate. *J Am Acad Dermatol* 2006;54:647-51.
15. Riddle CC, Terrell SN, Menser MB, Aires DJ, Schweiger ES. A review of photodynamic therapy (PDT) for the treatment of acne vulgaris. *J Drugs Dermatol* 2009;8:1010-19.
16. Pollock B, Turner D, Stringer MR, Bojar RA, Goulden V, Stables GI, *et al.* Topical aminolaevulinic acid photodynamic therapy for the treatment of acne vulgaris: A study of clinical efficacy and mechanism of action. *Br J Dermatol* 2004;151:616-22.
17. Itoh Y, Ninomiya Y, Tajima S, Ishibashi A. Photodynamic therapy of acne vulgaris with topical delta-aminolaevulinic acid and incoherent light in Japanese patients. *Br J Dermatol* 2001;144:575-9.