

Asymptomatic angiomatous lesions on the face and limbs of an adult woman

A 73-year-old woman presented with an acute-onset, asymptomatic eruption for 2 days. There was no history of fever or other prodromal symptoms. There was no relevant medical history other than a hepatitis C positivity detected 10 years back for which no treatment was taken. Physical examination revealed erythematous, bright red maculopapular lesions measuring 3–4 mm in diameter on her face [Figure 1] and limbs. The lesions were blanchable and those on the arms and legs [Figure 2] were surrounded by pale haloes. Routine laboratory tests including liver function tests were normal. A skin biopsy showed dilated capillaries with plump endothelial cells and a mild lymphocytic infiltrate surrounding the affected vessels in the dermis. The epidermis was unaffected and there was no vascular proliferation [Figure 3a and b].

WHAT IS YOUR DIAGNOSIS

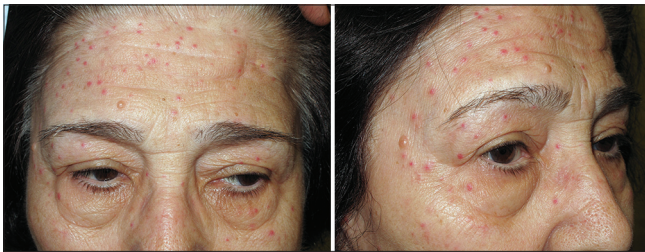

Figure 1: Angiomatous lesions measuring 3–4 mm in diameter on the face

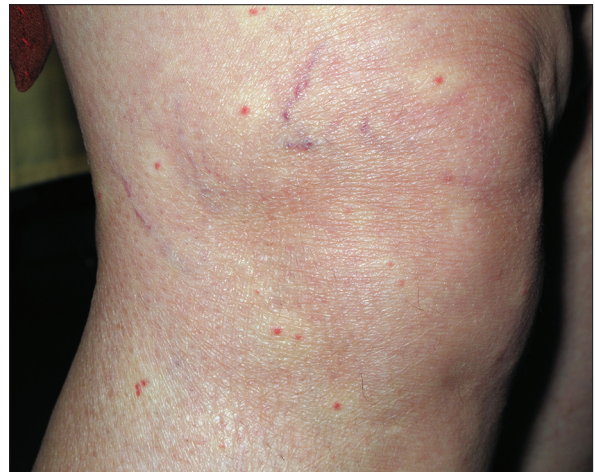


Figure 2: Bright red maculopapular lesions surrounded by a peripheral blanching halo on the leg

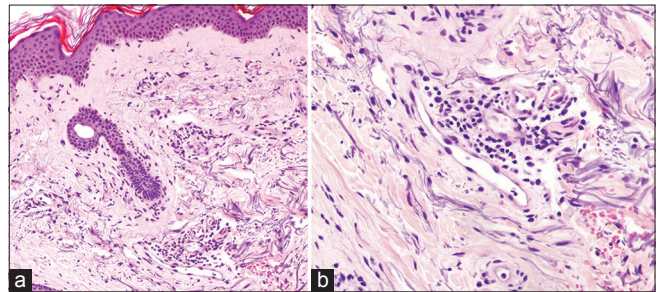


Figure 3: (a) (H and E, ×200) and (b) (H and E, ×400): Dilated dermal blood vessels with plump endothelial cells surrounded by a mild lymphocytic infiltrate

Access this article online	
Quick Response Code:	Website: www.ijdvl.com
	DOI: 10.4103/0378-6323.179093

This is an open access article distributed under the terms of the Creative Commons Attribution-NonCommercial-ShareAlike 3.0 License, which allows others to remix, tweak, and build upon the work non-commercially, as long as the author is credited and the new creations are licensed under the identical terms.

For reprints contact: reprints@medknow.com

How to cite this article: Alcántara-Reifs CM, Salido-Vallejo R, Garnacho-Saucedo G, Rizo-Barrios A, García-Nieto AV. Asymptomatic angiomatous lesions on the face and limbs of an adult woman. *Indian J Dermatol Venereol Leprol* 2016;82:356-7.

Received: September, 2015. **Accepted:** December, 2015.

ANSWER

Eruptive pseudoangiomatosis.

DISCUSSION

Eruptive pseudoangiomatosis is a rare, benign, cutaneous disorder which often overlaps with an entity first described by Higuchi in 1943, termed erythema punctatum.^[1] Although eruptive pseudoangiomatosis was initially reported as a type of viral exanthem exclusively seen in children, cases with onset in adulthood were reported later. This disorder is characterized by the sudden onset of distinctive, erythematous, angiomatous macules and papules varying from 2- 5 mm in diameter, usually distributed on the exposed skin. The lesions are generally blanchable on pressure and surrounded by an anemic halo, particularly on the arms and legs.^[2] Interestingly, the halo may not be seen around spots on the face.^[3] The eruption in adults is usually asymptomatic, without prodromal symptoms or fever and fades spontaneously without residual scarring in 1–3 months.

The etiology of this entity is still unknown. Some authors suggest an association with insect bites. Oka *et al.* reproduced the disease in two subjects experimentally bitten by *Culex pipiens* and *Aedes albopictus* mosquitoes.^[3] Others associate the disease with vector-transmitted infectious agents and viremia, especially in patients in whom eruptive pseudoangiomatosis occurred on both exposed and non-exposed areas, or after prodromal symptoms.^[4,5] Some patients demonstrated serological positivity for enteric cytopathic human orphan (ECHO) virus. In fact, unlike in adults, eruptive pseudoangiomatosis in children usually presents with prodromal symptoms of malaise and resolves more quickly in a period of 2–18 days.^[2] It is likely that insect bites were associated with the development of eruption in our patient since it occurred in summer and she gave a history of sleeping outdoors in the preceding nights. In addition, she was completely asymptomatic and had no co-morbidities other than hepatitis C infection.

The histological findings in our patient were consistent with those reported previously. Biopsies of eruptive pseudoangiomatosis lesions, although non-specific, show dilated dermal blood vessels with

plump endothelial cells protruding into the lumen and mild to moderate perivascular lymphohistiocytic infiltrates.^[2,4] The epidermis is generally unaffected and there is no evidence of vascular proliferation. These histological findings justify the term “eruptive pseudoangiomatosis,” although they resemble angiomas clinically. No treatment is needed for eruptive pseudoangiomatosis. Oral antihistamines and topical steroids may be indicated in symptomatic cases, although they do not affect the disease duration.^[4]

Declaration of patient consent

The authors certify that they have obtained all appropriate patient consent forms. In the form the patient(s) has/have given his/her/their consent for his/her/their images and other clinical information to be reported in the journal. The patients understand that their names and initials will not be published and due efforts will be made to conceal their identity, but anonymity cannot be guaranteed.

Financial support and sponsorship

Nil.

Conflicts of interest

There are no conflicts of interest.

**Carmen María Alcántara-Reifs,
Rafael Salido-Vallejo, Gloria Gamacho-Saucedo,
Antonio Rizo-Barríos¹,
Antonio Vélez García-Nieto**

Departments of Dermatology and ¹Pathology, Reina Sofía University Hospital, Córdoba, Spain

Address for correspondence: Dr. Carmen María Alcántara-Reifs, Department of Dermatology, Reina Sofía University Hospital, Av. Menéndez Pidal, s/n, 14004 Córdoba, Spain. E-mail: ayla88_@hotmail.com

REFERENCES

1. Higuchi K. About a kind of erythema punctatum. *Dermatol Urol* 1943;11:171-2.
2. Pérez-Barrio S, Gardeazábal J, Acebo E, Martínez de Lagrán Z, Díaz-Pérez JL. Eruptive pseudoangiomatosis: Study of 7 cases. *Actas Dermosifiliogr* 2007;98:178-82.
3. Oka K, Ohtaki N, Kasai S, Takayama K, Yokozeki H. Two cases of eruptive pseudoangiomatosis induced by mosquito bites. *J Dermatol* 2012;39:301-5.
4. Kim JE, Kim BJ, Park HJ, Park YM, Park CJ, Cho SH, *et al.* Clinicopathologic review of eruptive pseudoangiomatosis in Korean adults: Report of 32 cases. *Int J Dermatol* 2013;52:41-5.
5. Ban M, Ichiki Y, Kitajima Y. An outbreak of eruptive pseudoangiomatosis-like lesions due to mosquito bites: Erythema punctatum Higuchi. *Dermatology* 2004;208:356-9.