

BATTERED CHILD SYNDROME

B Ranganayakulu, GP Ravikumar, A Vijaya Bhaskar

Primary genital herpes in a girl of 12 years age is reported as the condition is rare in this age group and sexual abuse was the direct cause for the Battered child syndrome.

Key words : Battered child syndrome, Primary genital herpes, Tzanck test, Acyclovir

Introduction

Sex abuse¹ is the forced interaction between a child and an adult, wherein the child is used for the sexual gratification of the adult. In sex abuse the culprit is usually a young male and the victim is a girl under 12 years of age. The exact incidence of sex abuse is not known. It is estimated that at least one in four girls will be molested before age 16. There are many taboos and ignorance around sexual abuse. Some of the sexually misused children are affected by STD and the actual affair comes to light when they are brought to the STD clinic for treatment. The condition affects the child's general health, social behaviour and emotional well being.

Case Report

A 12-year-old girl was brought to the STD

department by her parents for painful lesions over genitalia for the last 5 days. The child herself was in an indrawn mood, not answering to questions. She was not dressed well, irritable, anxious and uncooperative. On gentle probing and patient persuasion by the staff nurse it was revealed that the child's maternal uncle was responsible for the sex abuse. That person, on verification of case records, had already attended this OPD with recurrent genital herpes. He was a promiscuous individual. The exact period of sexual contact could not be made out. There was no history of anal or oral sex.

On general examination the child was thin built, small statured and appeared aged about 10 years. She was ill nourished, her hair was greyish and she was anemic. There was no generalised lymphadenopathy.

Genital examination revealed multiple superficial erosions on both labia majora. There was history of vesicles which ruptured and

From the Department of STD,
Kurnool Medical College,
Kurnool - 518002, Andhra Pradesh.
Address correspondence to :
Dr. Ranganayakulu

formed erosions. All the erosions were circular in shape, 0.5 cm in diameter and dull red in colour (Fig.1). The hymen was found ruptured. The anal and perianal areas were normal. The inguinal lymph nodes were enlarged, discrete, firm and tender on both sides.

Blood VDRL was non-reactive. Routine laboratory tests on blood and urine were normal except a low blood Hb (8 g%). Tzanck test of the smear from erosions revealed large balloon cells with cytoplasmic degeneration. A diagnosis of primary genital herpes was made.

The child was treated with acyclovir tablets 200 mg. four times a day along with topical acyclovir for one week and the lesions subsided completely. The child was advised psychoanalysis. The parents promised to return after one week but they failed to revisit in spite of our best efforts.

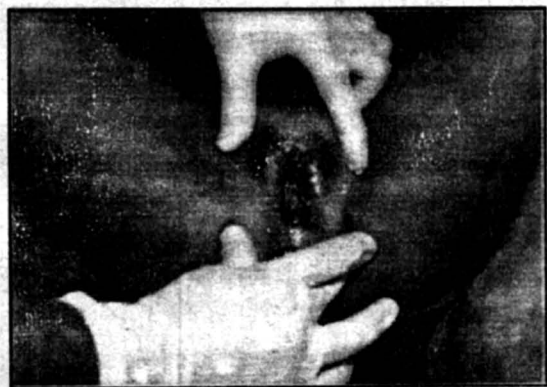


Fig. 1. Herpetic erosions of the vulva

Discussion

Acute primary genital herpes in a 12-year-old girl occurring because of sex abuse made an interesting report. The sexual abuse

has led the victim in to a state of confusion, anxiety, uncooperativeness and irritability resulting in the classical "battered child syndrome".¹ This sort of sexual exploitation sometimes results in developmental problems in the girl in all the spheres of her life. Majority of the victims are girls with an average age of 8 to 10 years.² In them the sexual interaction may continue for some time before seeking medical attention. This concealment may be due to ignorance or fear of retaliation from the abuser on the part of the child and social embarrassment and medico legal problems on the part of the parents. A high percentage of abused children has been found to be abused by their family members.³

If the child sex abuse is not noticed early and brought to medical aid in time the child is at high risk for repeated sex misuse. This will predispose her to develop sexual dysfunctions such as promiscuity and the resultant STDs or frigidity, refusal of marriage and other psychosexual problems. So in all such child sex abuse cases psychoanalysis, proper counselling and follow up are necessary to put them back in harmonious social life.

References

1. Kemp CH. Child abuse: The pediatrician's role in child advocacy and preventive pediatrics. *Am J Dis Child* 1978; 132: 255-257.
2. Brant RST, Tisza VB. The sexually misused child. *Am J Orthopsychiatry* 1977; 47: 80-82.
3. Jenny C. Child abuse and sexually transmitted disease. In: *Sexually Transmitted Disease*, 2nd edn, Edited by Homes KK, Mardh PA, Sparling PF, et al, MC Graw Hill Book Company, New York, 1990; 895-900.