

# A novel indication for non-cultured epidermal suspension: Post-inflammatory depigmentation in atopic dermatitis

Dear Editor,

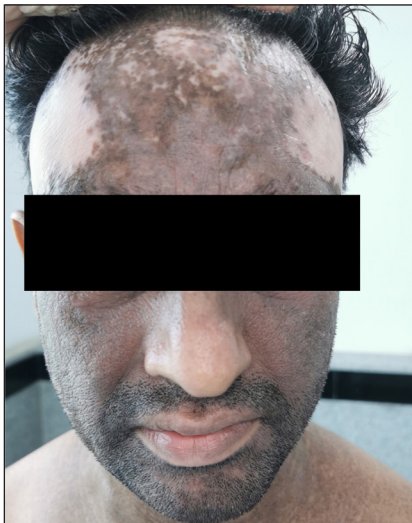Atopic dermatitis is a chronic pruritic dermatosis with a huge psychosocial burden.<sup>1</sup> Constant scratching, particularly in patients with skin of colour, often causes dyspigmentation, both hyperpigmentation and sometimes depigmentation, especially in lichenified skin.<sup>2</sup> This further negatively impacts the quality of life.

A 36-year-old man, with childhood-onset atopic dermatitis presented with involvement of the face, neck, and upper trunk in the form of hyperpigmented lichenified plaques, linear excoriations, and pronounced fissuring [Figure 1a]. Notably, conspicuous depigmented plaques were present bilaterally on the sides of the forehead, accompanied by smaller macules centrally, encroaching upon the anterior hairline. Prior to the development of these, the patient reported similar hyperpigmented lichenified plaques, and no depigmented macules were noted elsewhere on the body. Dennie-morgan folds, dirty neck, and palmar hyperlinearity

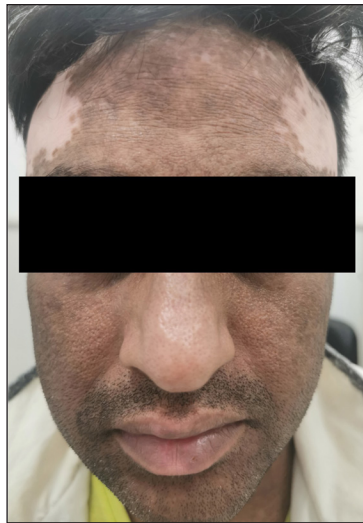were also present. The patient reported transient symptomatic amelioration with oral corticosteroids; nonetheless, disease relapse promptly followed treatment cessation. No history of hair dye usage was elicited, eliminating it as a potential causative agent for the depigmentation.

We started the patient on oral tofacitinib 5 mg twice daily, oral steroid minipulse therapy (5 mg betamethasone) two days/week, antihistamines, tacrolimus ointment (for face), topical mometasone cream and liberal application of paraffin-based moisturiser.

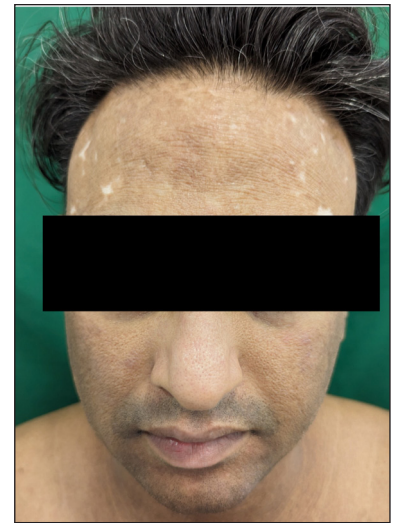
At the subsequent visit, there was a marked reduction in pruritus and excoriations had healed. A gradual tapering of betamethasone allowed its complete discontinuation over 6 months. He was then maintained on tofacitinib for another three months, which led to a notable improvement in the lichenified plaques on the face. Nonetheless, the depigmentation persisted [Figure 1b].



**Figure 1a:** Baseline clinical photograph showing lichenified plaques on the face with depigmented areas.



**Figure 1b:** Improvement in the lichenified plaques after oral mini pulse and tofacitinib. Note the persistence of depigmentation.



**Figure 1c:** Sustained near-complete repigmentation at nine months follow-up after non-cultured epidermal suspension.

**How to cite this article:** Ahuja R, Pragma P, Gupta S. A novel indication for non-cultured epidermal suspension: Post-inflammatory depigmentation in atopic dermatitis. *Indian J Dermatol Venereol Leprol*. doi: 10.25259/IJDVL\_43\_2024

Received: January, 2024 Accepted: April, 2024 Epub Ahead of Print: July, 2024

DOI: 10.25259/IJDVL\_43\_2024

This is an open-access article distributed under the terms of the Creative Commons Attribution-Non Commercial-Share Alike 4.0 License, which allows others to remix, tweak, and build upon the work non-commercially, as long as the author is credited and the new creations are licensed under the identical terms.

We planned a non-cultured epidermal suspension (NCES) for these depigmented areas. A thin epidermal graft was harvested from the uninvolved left lateral thigh (donor site) and subjected to warm trypsinisation (0.25% trypsin). The dermis was separated from the epidermis followed by teasing out of the pigmented cells. The recipient area was prepared by gentle dermabrasion, extending just beyond the depigmented margin. Post-centrifugation of the melanocyte-rich cell suspension, the pellet was re-suspended in phosphate-buffered saline and transferred to the recipient site.

Following the procedure, the patient was instructed to continue the application of topical tacrolimus on the face. Approximately a month later, we observed islands of normally pigmented skin emerging within the previously depigmented areas. Subsequently, there was a near-complete repigmentation at three months, and this outcome was sustained even at the nine-month follow-up [Figure 1c]. The patient was also highly satisfied with the treatment.

Alteration in neurotrophic polypeptides, such as nerve growth factor (NGF) is a feature of many chronic inflammatory dermatoses, including atopic dermatitis.<sup>3</sup> NGF plays a pivotal role in both neuronal differentiation and also in influencing the survival of melanocytes through its interaction with tyrosine kinase receptors.<sup>4,5</sup> In lichenified lesions, there is a reduced NGF production by keratinocytes and also a reduction in length and number of peripheral nerve fibres in the leukoderma areas compared to non-leukoderma areas.<sup>2</sup> The decreased NGF production, in turn, triggers a reduction in melanocytes. A similar depigmentation has been reported in lichen simplex chronicus and also in severe atopic dermatitis ('vitiligo achromias').<sup>2,6</sup> The presence of depigmented macules localised to sites initially affected by severe eczema and did not show further progression, differentiating it from vitiligo.<sup>6</sup>

The present case showed remarkable repigmentation with NCES, which relies on the principle of transfer of autologous melanocytes from normal pigmented donor skin. NCES has shown to be effective in various non-vitiligo causes of leukoderma like naevus depigmentosus, piebaldism, chemical leukoderma, and halo naevus, with results comparable to vitiligo (>75% repigmentation in 27%–100% of patients). Segmental vitiligo and piebaldism had the highest repigmentation rates.<sup>7</sup>

While vitiligo may co-exist with atopic dermatitis, however, the localisation of the depigmentation only on the forehead does not conform with any known patterns of non-segmental vitiligo. Moreover, these depigmented areas had been preceded by hyperpigmented lichenified plaques.

We cannot dismiss the potential immunomodulatory effects of tofacitinib and oral steroids in atopic dermatitis; however, it is essential to note that there was no repigmentation observed during the six-month period when both modalities were used concurrently before implementing NCES.

### Declaration of patient consent

The authors certify that they have obtained all appropriate patient consent.

### Financial support and sponsorship

Nil.

### Conflicts of interest

There are no conflicts of interest.

### Use of artificial intelligence (AI)-assisted technology for manuscript preparation

The authors confirm that there was no use of AI-assisted technology for assisting in the writing or editing of the manuscript and no images were manipulated using AI.

**Rhea Ahuja, Purn Pragma, Somesh Gupta**

Department of Dermatology and Venereology,  
All India Institute of Medical Sciences, New Delhi, India.

### Corresponding author:

Prof. Somesh Gupta,  
Department of Dermatology and Venereology,  
All India Institute of Medical Sciences, New Delhi, India.  
someshgupta@aiims.edu

### References

1. Eckert L, Gupta S, Amand C, Gadkari A, Mahajan P, Gelfand JM, *et al.* Impact of atopic dermatitis on health-related quality of life and productivity in adults in the United States: An analysis using the national health and wellness survey. *J Am Acad Dermatol* 2017;77:274–79.e3
2. Ichiki T, Sugita K, Furue M, Yamamoto O. An intimate relationship between intralesional depigmentation and peripheral nervous system in lichen simplex chronicus. *Acta Derm Venereol* 2020;100:adv00042
3. Papoiu AD, Wang H, Nattkemper L, Tey HL, Ishiui Y, Chan YH, *et al.* A study of serum concentrations and dermal levels of NGF in atopic dermatitis and healthy subjects. *Neuropeptides* 2011;45:417–22
4. Yaar M, Eller MS, Dibenederro P, Reenstra WR, Zhai S, McQuaid T, *et al.* The trk family of receptors mediators nerve growth factor and neurotrophin-3 effects in melanocytes. *J Clin Invest* 1994;94:1550–62.
5. Yuan XH, Jin ZH. Paracrine regulation of melanogenesis. *Br J Dermatol* 2018;178:632–9.
6. Larrègue M, Martin J, Bressieux JM, Canuel C, De Giacomoni P, Ramdenée P *et al.* Achromies vitiligoïdes et dermatite atopique grave. A propos de quatre cas [Vitiligo achromias and severe atopic dermatitis. A propos of 4 cases]. *Ann Dermatol Venereol* 1985;112:589–600.
7. van Geel N, Goh BK, Wallaeyns E, De Keyser S, Lambert J. A review of non-cultured epidermal cellular grafting in vitiligo. *J Cutan Aesthet Surg* 2011;4:17–22.