

Pautrier's microabscess: An eponym by mistake

Ramesh M. Bhat^{1,2,3}, Monisha Madhumita¹

The French are well known for their cheese, wine, sense of humor and particularly, their pivotal role in the advancement of dermatology. Ferdinand-Jean Darier (1856-1938) [Figure 1] was a renowned leader in French Dermatology—a clinician and pathologist par excellence.¹ He was considered as the last surviving member of the “Big Five”—Besnier, Brocq, Darier, Sabouraud and Fournier.² Darier described several dermatoses such as dermatofibrosarcoma (Darier and Ferrand), acanthosis nigricans, follicular keratosis, erythema annularis, pseudoxanthoma elasticum, hypodermic sarcoids (Darier and Roussy) and Darier's sign in mastocytosis, to name a few.² Primarily, Darier studied the histopathologic features of mycosis fungoides, particularly, the premycotic stage for several decades and described its highly characteristic histological features.¹ This histopathological finding was put in perspective and popularised by another stalwart of French dermatology, Lucien Marie Pautrier (1876-1959) [Figure 2]. These two dermatologists were illustrious colleagues at “Hôpital Saint Louis.” In present times, they are connected by an eponym which is in equal parts, ironical and erroneous.³

The term “mycosis fungoides” was coined by Jean Louis Alibert (1768-1837).⁴ It is an indolent form of cutaneous T-cell lymphoma.⁵ One of its defining histopathological features is the presence of intraepidermal nests/collections of atypical lymphocytes [Figure 3]. The histology of mycosis fungoides was extensively studied and many dermatologists have also detailed the presence of vesicles or cellular nests in

the epidermis. However, its diagnostic importance was not realized under decades later. Following this, although the importance of this finding was later understood, the feature was given an erroneous eponym, quite simply ‘by mistake’, one that has perpetuated till date.




Figure 1: Jean Ferdinand Darier (1856–1938)

¹Department of Dermatology, Venereology and Leprosy, Father Muller Medical College, Mangalore Karnataka, India, ²ILDS, ³IADVL

Correspondence: Dr. Monisha Madhumita,
Department of Dermatology, Father Muller Medical College, Father Muller Road, Kankanady Post, Mangalore - 575 002, Karnataka, India.
E-mail: drmonisha.m@yahoo.com

Access this article online	
Quick Response Code:	Website: www.ijdvl.com
	DOI: 10.4103/ijdvl.IJDVL_1100_19

This is an open access article distributed under the terms of the Creative Commons Attribution-NonCommercial-ShareAlike 4.0 License, which allows others to remix, tweak, and build upon the work non-commercially, as long as the author is credited and the new creations are licensed under the identical terms.

For reprints contact: reprints@medknow.com

How to cite this article: Bhat RM, Madhumita M. Pautrier's microabscess: An eponym by mistake. Indian J Dermatol Venereol Leprol 2020;86:747-9.

Received: January, 2020. **Accepted:** June, 2020.

The intraepidermal nest of atypical lymphocytes is commonly known as “Pautrier’s microabscess” in the majority of our textbooks. It is noteworthy that this finding has very little to do with Pautrier, a fact that he himself has acknowledged.⁶

The credit of the original description of this feature, in fact, belongs to Darier [Figure 4]. Pautrier carried a great interest in the study of mycosis fungoides. In his numerous lectures, he drew attention to the presence of “Darier’s nests” as an important tool to diagnose mycosis fungoides.

Despite his eminent publishing history (1903-1957) and innumerable contributions to dermatology and dermatopathology, how did Pautrier come to be known most famously for a finding he didn’t describe? History holds the answer.⁶

In 1887, Darier analyzed a cutaneous biopsy specimen of a case of mycosis fungoides. He gave it the original description of “minute cellular nests of lymphocytes” in the rete ridges.⁷ Since then, he re-emphasised the diagnostic value of “Les nids intraepidermiques de lymphocytes qui sont pathognomonique” in mycosis fungoides.

In his textbook of dermatology, he included a drawing [Figure 4] of the histology of premycotic erythroderma.³ In it, he described little lodges filled with cells (“les logettes remplies de cellules”) in the rete ridges, in a case called “The red man” (“L’homme rouge”).⁶ This case was presented as a case report at the First World Congress of Dermatology and Syphilology at Paris in 1889 by F. Henri Hallopeau (1842-1919) and published in 1890. The publication notably did not include Darier as an author. However, he was mentioned in the textual content.⁷ In 1910, Darier wrote in the “Unna Festschrift-Dermatologische

Studien” an extensive review of premycotic eruptions with special reference to premycotic erythroderma.⁸

The mention of the term “Darier’s nest” can be sparsely found in the records of New York Dermatology Society in 1926.⁹ French dermatological literature pertaining to mycosis fungoides continues to rightly credit Darier for his discovery of the intraepidermal nests. They refer to it as “thèque” (capsule/nest/sac) and not “petit nid cellulaire” (as described by Pautrier).¹⁰

To find the origins of the term “Pautrier’s microabscess,” we must move to another continent— North America. The earliest mention of “Pautrier’s microabscess” as a hallmark of mycosis fungoides was in the year 1932 exclusively in American dermatological literature, sans citation.⁷

In 1946, Louis Winer (Dermatologist, Beverly Hills) gave a lecture on mycosis fungoides where he mentioned “Intraepidermal microabscess of Pautrier in the pre-mycotic stage” at the 66th Annual meeting of the American Dermatology Association.¹¹




Figure 2: Lucien-Marie Pautrier (1876–1959)

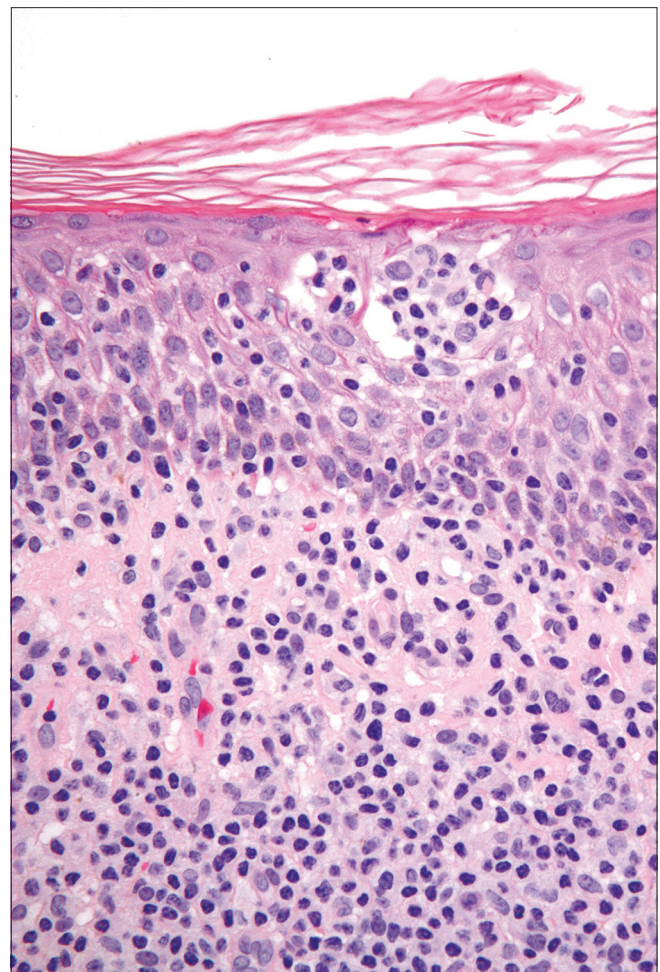


Figure 3: Darier’s epidermal nest (H and E, ×40)

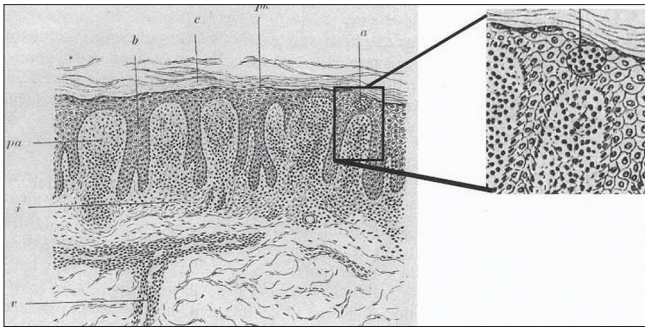


Figure 4: The original diagrammatic representation of intraepidermal cell nests in Darier's 1909 *Précis de dermatologie* (Paris: Masson). (The authors acknowledge that Figure 4 is reproduced with permission from the article published in *J Am Acad Dermatology*, Vol 46, Wallach D, In reply, p321, Copyright Elsevier [2002].)

In 1954, Allen described the finding as “Darier's/Pautrier's abscess.” This was in the context of describing it as “merely a collection of several cells of dermal infiltrate in the epidermis” to distinguish it from purulent abscess.¹²

In 1975, Walter F. Lever (1909-1992), in his textbook, described the histopathology of mycosis fungoides to have two cell types—“mycosis cells” (with characteristic cerebriform nuclei) and inflammatory cells. He also described the presence of atypical cell nests in the epidermis.¹³

In 1978, A. Bernard Ackerman (1936-2008) categorically mentioned the presence of “Pautrier's abscess”—a collection of three or more atypical lymphocytes in the epidermis as a specific finding in mycosis fungoides in his textbook.¹⁴ This firmly established the presence of this inaccurate eponym in our texts in the years that followed.

This calls to question as to what happened in the intervening years (1920-1940). During these years, the credit for the identification of the pathognomonic microabscess in mycosis fungoides imperceptibly changed from Darier to Pautrier, across continents.

It is suggested that the intercontinental visits of Pautrier may hold the key to this mystery. Between the years 1922 and 1927, Pautrier was invited several times to various universities in the United States of America to deliver lectures.¹⁵

In May 1927, he delivered a lecture at the New York Dermatology Society, where he talked about “Darier's nests” as an important feature to diagnose mycosis fungoides. The lecture was attended by his French colleagues—Paul Bouin and Georges Masson in addition to American dermatologists including Jay Shamberg, Sigmund Pollitzer, Udo, J. Wile, McBride and Fred Wise. It is speculated that it is at this visit that someone in the audience wrongly accredited the fatherhood of the description to Pautrier.⁷ Thus began the confusion of a decade.⁸

This misattribution went unnoticed by Pautrier. On his return to France, he presented an impressive histological picture of “little nests of lymphocytes,” (“petits nids cellulaire a lymphocytes”) at a special meeting of the “Reunion Dermatologie de Strasbourg.” Here, he acknowledged Darier's original description.⁶

The origin of one of the most well-known eponyms in dermatology is certainly a curious and circuitous one. The French have remained steadfast in rightly attributing the intraepidermal cell nests in mycosis fungoides to Ferdinand-Jean Darier.¹⁰ In order to give credit where its due, we must follow suit “à la française.” We also insist that there is a need to correct this mistake by changing the eponym to “Darier's epidermal nests.”

Footnote: The authors acknowledge with thanks that Figure 4 is reproduced from the article published in *J Am Acad Dermatology*, 46, Wallach D, In reply, p321, Copyright Elsevier (2002).

Financial support and sponsorship

Nil.

Conflicts of interest

There are no conflicts of interest.

References

1. Ségal A. Ferdinand-Jean Darier (1856-1938) dermatologist of world renown. *Hist Sci Med* 2009;43:389-94.
2. Wilkinson DS. Glossary of Dermatological Terms. In: Champion RH, Burton JL, Burns DA, Breathnach SM, editors. *Textbook of Dermatology*. 6th ed.. Oxford: Blackwell Science; 1998. p. 3651.
3. Omura GA. Darier, Pautrier, and the “microabscesses” of mycosis fungoides. *J Am Acad Dermatol* 2002;46:320-21.
4. Alibert JL. *Monographie des Dermatoses ou Précis Théorique et Pratique des Maladies de la Peau*. Vol. 2. G. Baillieure Paris: Chez le Docteur Daynac; 1832. p. 414-27.
5. Korgavkar K, Xiong M, Weinstock M. Changing incidence trends of cutaneous T-cell lymphoma. *JAMA Dermatol* 2013;149:1295-9.
6. Schmidt-Skrabs CC. Pautrier microabscesses (PA): A historical note. *Am J Dermatopathol* 2000;22:555.
7. Cribier BJ. The myth of Pautrier's microabscesses. *J Am Acad Dermatol* 2003;48:796-7.
8. Pollack KE, Noland MM. Darier Nests or Pautrier microabscesses: Highlighting the confusion of a decade. *Dermatol Online J* 2018;24 (7):8.
9. Wallach D. In reply. *J Am Acad Dermatol* 2002;46:321.
10. Cribier BJ. Lucien marie pautrier (1876-1959): The man and the myth of the microabscesses. *Dermatopathol* 2001;7:135-47.
11. Winer LH. Mycosis fungoides. *Arch Dermat Syph* 1947;56:480-98.
12. Allen AC. *The Skin: A Clinicopathologic Treatise*. 2nd ed.. St Louis: CV Mosby; 1954.
13. Lever WF, Schaumburg-Lever G. *Histopathology of the Skin*. 5th ed.. Philadelphia: Lippincott; 1975.
14. Ackerman AB. *Histologic Diagnosis of Inflammatory Skin Diseases: A Method by Pattern Analysis*. 3rd ed.. Philadelphia: Lea & Febiger; 1978.
15. Steffen C. The man behind the eponym: Lucien Marie Pautrier—Pautrier's microabscess. *Am J Dermatopathol* 2003;25:155-8.