

Cutaneous metastases from ovarian clear cell carcinoma

A 47-year-old woman presented with a two-month history of skin lesions on the lower abdomen and thighs. Physical examination revealed multiple, erythematous, painful nodules with a hard consistency, poor mobility, partial surface erosions, and marginal red infiltrating patches [Figure 1]. A biopsy of the nodule from the patient's right thigh showed

polygonal and cuboidal cells of varying sizes with clear cytoplasm in the dermis [Figure 2]. Immunohistochemistry results were positive for hepatocyte nuclear factor (HNF)-1 β , Napsin A, paired box (PAX)-8, and Wilm's tumour gene (WT)-1, while negative for estrogen receptor (ER). She was undergoing treatment for stage IIIC ovarian clear cell carcinoma and was diagnosed with cutaneous metastases from the carcinoma.

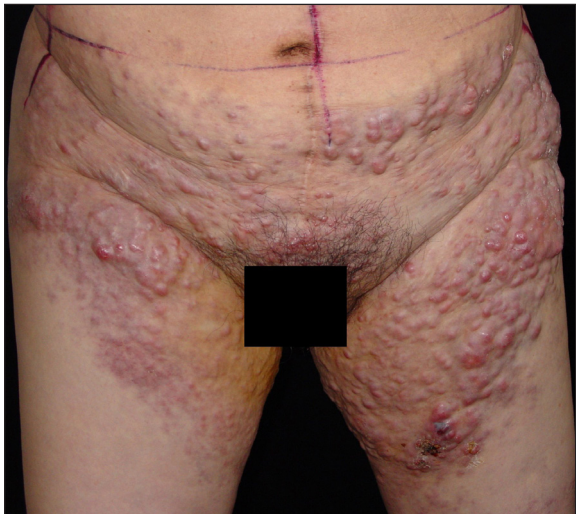


Figure 1: Multiple, erythematous nodules on the lower abdomen and thighs with partial surface erosions and marginal red infiltrating patches.

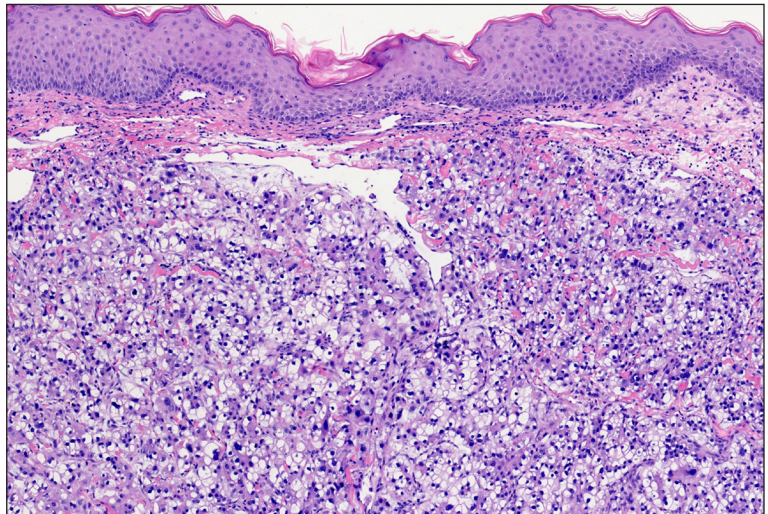


Figure 2: Histopathology showing polygonal and cuboidal cells of varying sizes in the dermis with clear cytoplasm (Haematoxylin-eosin; 20x).

Declaration of patient consent: The authors certify that they have obtained all appropriate patient consent.

Financial support and sponsorship: Nil.

Conflicts of interest: There are no conflicts of interest.

Use of artificial intelligence (AI)-assisted technology for manuscript preparation: The authors confirm that there was no use of artificial intelligence (AI)-assisted technology for assisting in the writing or editing of the manuscript, and no images were manipulated using AI.

Teng Liu¹, Jianmin Chang¹

¹Department of Dermatology, Beijing Hospital, National Centre of Gerontology, Institute of Geriatric Medicine,

Chinese Academy of Medical Sciences & Peking Union Medical College, Beijing, China.

Corresponding author:

Dr. Jianmin Chang,

Department of Dermatology,

Beijing Hospital, National Centre of Gerontology, Institute of

Geriatric Medicine, Chinese Academy of Medical Sciences &

Peking Union Medical College, Beijing, China.

changjm0417@126.com

How to cite this article: Liu T, Chang J. Cutaneous metastases from ovarian clear cell carcinoma. Indian J Dermatol Venereol Leprol. doi: 10.25259/IJDVL_1886_2024

Received: December, 2024 **Accepted:** January, 2025 **Epub Ahead of Print:** January, 2025

DOI: 10.25259/IJDVL_1886_2024

This is an open-access article distributed under the terms of the Creative Commons Attribution-Non Commercial-Share Alike 4.0 License, which allows others to remix, transform, and build upon the work non-commercially, as long as the author is credited and the new creations are licensed under the identical terms.