

Scurvy– Once a common condition likely to be missed in the uncommon times!

Dear Editor,

Scurvy, a Vitamin C deficiency disorder, has been documented since antiquity. An uncommon disease today, from a dermatological perspective, it can be missed due to subtle clinical signs. Thus one must correlate the characteristic clinico-radiologic findings and etiologic risk-factors for diagnosing scurvy.

A seven-year-old boy was admitted to the paediatric intensive care unit for seizures. The boy was diagnosed with West Syndrome at birth. Within seven days of admission, he developed fever, joint pain, abdominal pain, haematuria and

ecchymotic patches. Treatment with systemic antibiotics, anticonvulsants, muscle relaxants and multivitamins were initiated by the paediatrician and he was referred to the dermatology department for ecchymotic patches. He was poorly built, lethargic with delayed milestones and spasticity in all four limbs. He had pallor and painful edema of the knee joints. Cutaneous examination revealed multiple ecchymotic patches over the knee joints and a few follicular and non-follicular palpable purpura on the lower limbs [Figure 1a]. We also noted sparse follicular keratotic papules and xerosis of the upper and lower limbs [Figure 1b]. We considered Henoch-Schönlein purpura and meningococemia as differentials. Investigations revealed haemoglobin of

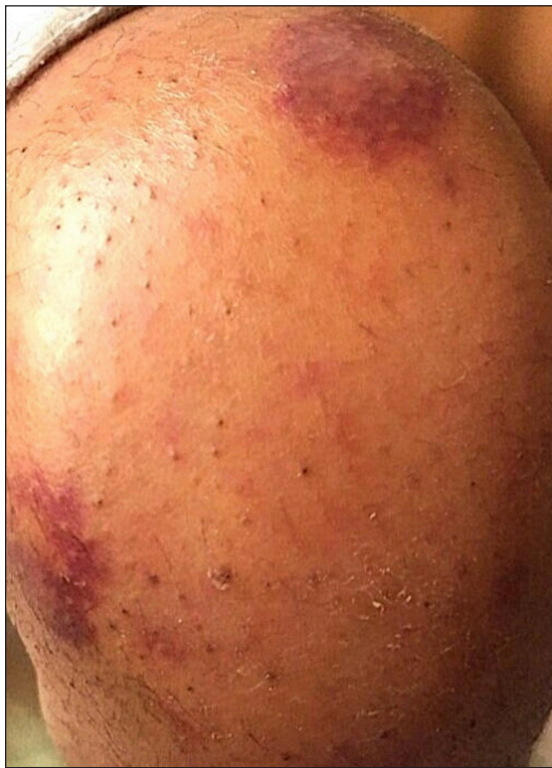

Figure 1a: Ecchymosis over knee joint

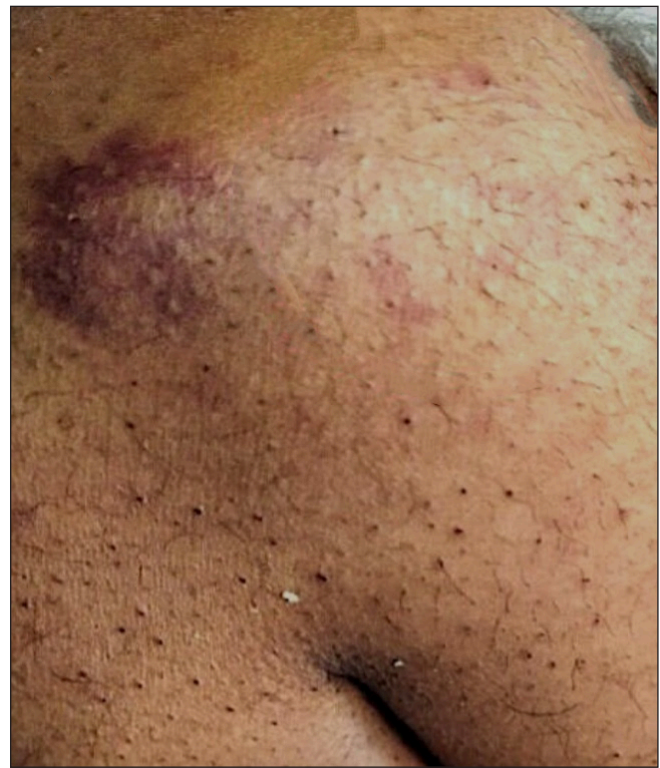

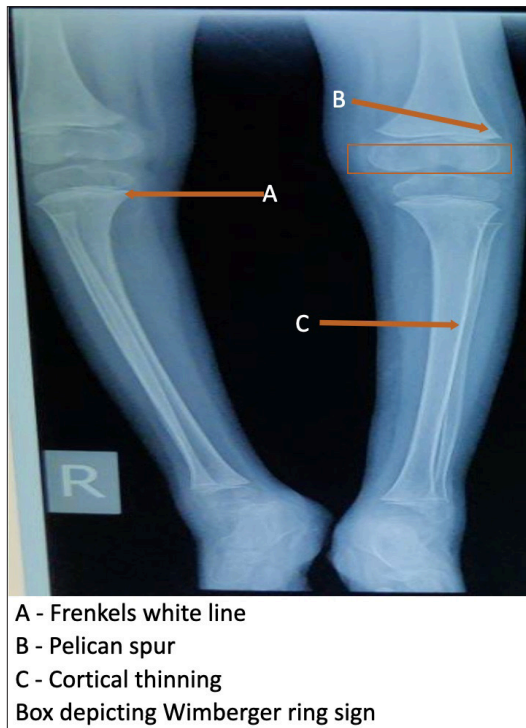
Figure 1b: Xerosis with keratotic plugs over the knee joint

How to cite this article: Dhurat RS, Sharma R, Pai SU, Zatakia SM. Scurvy-Once a common condition likely to be missed in these uncommon times! Indian J Dermatol Venereol Leprol doi: 10.25259/IJDVL_400_2023

Received: April, 2023 **Accepted:** July, 2023 **Epub Ahead of Print:** October, 2023

DOI: 10.25259/IJDVL_400_2023

This is an open-access article distributed under the terms of the Creative Commons Attribution-Non Commercial-Share Alike 4.0 License, which allows others to remix, tweak, and build upon the work non-commercially, as long as the author is credited and the new creations are licensed under the identical terms.



A - Frenkels white line
 B - Pelican spur
 C - Cortical thinning
 Box depicting Wimberger ring sign

Figure 2: Radiograph of knee joint

6.5g/dL, reticulocyte count of 3.5%, white blood cell count of $8.3 \times 10^9/L$ with a normal differential count, and a platelet count of $233 \times 10^9/L$. His C-reactive protein level was 20 mg/L (normal <10 mg/L). Serum vitamin C level was 1.29 mg/dl (0.6–2 mg/dL). Blood cultures, coagulation profiles, electrolyte levels and liver and kidney function tests were all within reference ranges. Urine microscopy revealed 10 RBCs per field. Histopathological examination of palpable

purpura revealed follicular plugging, a mild upper dermal lymphocytic infiltrate with extravasation of RBCs and no evidence of vasculitis. A radiological survey of the wrist and knees revealed cortical thinning, the Wimberger ring sign, the Frankel sign and the Pelkan spur [Figure 2]. The CT scan of brain showed subgaleal hematoma, cerebral atrophy and periventricular calcification. A normal blood culture and negative histopathologic features of Henoch-Schönlein purpura and the presence of characteristic radiological findings prompted the diagnosis of scurvy. The patient was re-evaluated for skin findings of scurvy. The dermoscopy of the keratotic papules revealed characteristic cork screw hair [Figure 3a]. Deep sectioning of histopathological tissue specimens revealed coiled hair [Figure 3b]. Thus the diagnosis of scurvy was confirmed. His ecchymotic patches and purpuric papules resolved completely with ten days of oral vitamin C (500 mg).

Scurvy is a multiorgan systemic disease because of diverse functions of vitamin C. The occurrence of scurvy in children with autism or other neuropsychiatric disorders is not uncommon.¹ Additionally, the high-risk groups include children with iron load due to multiple blood transfusions, anorexia nervosa, celiac disease, Crohn's disease, haemodialysis and other causes of a restricted diet.¹ A few dermatological signs, which are seen in the early stages, are follicular hyperkeratosis and coiled corkscrew hair.² Broken and lustreless hair are due to abnormal disulfide bonding and keratin formation.³ Fragile blood vessels resulting from impaired collagen synthesis give rise to perifollicular haemorrhages, petechiae and ecchymoses.² Rarely, we may see nail splinter haemorrhages and alopecia.³ Serum vitamin C levels are considered specific, but laboratory tests are

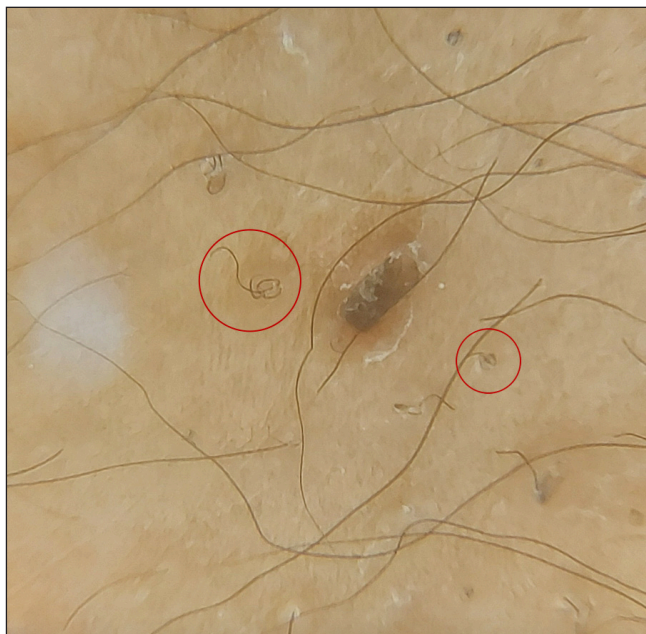

Figure 3a: Dermoscopy showing coiled hair

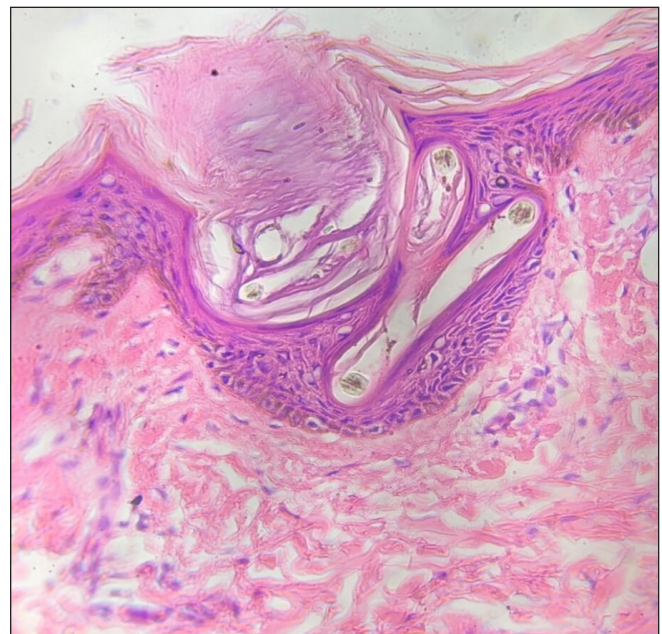

Figure 3b: Histopathology showing follicular plugging and corkscrew hair in epidermis (40x H&E stain)

usually insensitive. It is known that serum concentrations do not always correspond with tissue storage of ascorbic acid. A reliable indicator of body storage is the measure of urinary excretion after intravenous ascorbic acid administration. Normally, 80% of absorbed vitamin C should be excreted within 3–5 hours. Also, the prompt resolution of symptoms after substitution treatment represents key evidence to confirm the diagnosis of scurvy.⁴ Multivitamin therapy is initiated in most critical cases, which explains the normal serum vitamin C level in our case. The patient had very subtle cutaneous features, making the diagnosis challenging. The natural course of undetected and untreated vitamin C deficiency can result in seizures and cardiac abnormalities and cases of sudden death have also been reported.⁵ This signifies the need for prompt detection and early treatment. The regimen for vitamin C supplementation in scurvy has not been established yet. Therapeutic supplementation with 1 g/day of oral vitamin C for 2 weeks is the usual treatment.⁵ The dose and duration of treatment should be individualised.

Declaration of patient consent

The authors certify that they have obtained all appropriate patient consent.

Financial support and sponsorship

Nil.

Conflict of interest

There are no conflicts of interest.

***Rachita S Dhurat, Richa Sharma, Suraj Uday Pai,
Srushthi Manish Zatakia***

Department of Dermatology, Lokmanya Tilak Municipal Medical College and General Hospital, Mumbai, India

Corresponding author:

Dr. Rachita S Dhurat,
Department of Dermatology, Lokmanya Tilak Municipal Medical College and General Hospital, Mumbai, India.
rachitadhurat@yahoo.co.in

References

1. Leger D. Scurvy: reemergence of nutritional deficiencies. *Can Fam Physician* 2008;54:1403–6.
2. Chaudhry SI, Newell EL, Lewis RR, Black MM. Scurvy: a forgotten disease. *Clin Exp Dermatol* 2005;30:735–6.
3. Mapp SJ, Coughlin PB. Scurvy in an otherwise well young man. *Med J Aust* 2006;185:331–2.
4. Conversano E, Bergamaschi R, Ingrassiotta G, Martoni A, Monti S, Cattalini M. Scurvy in 2017 through cases. *Medico e Bambino* 2017;36:365–70.
5. Fain O. Musculoskeletal manifestations of scurvy. *Joint Bone Spine* 2005;72:124–8.