

WHAT IS YOUR DIAGNOSIS?

A forty year old male patient with lepromatous leprosy who was on antileprosy treatment for 8 years complained of itching on the body and scalp of 1 year's duration. There was no seasonal variation in the symptoms.

Examination revealed thick scaly lesions on palms, soles, elbows, wrists, knees and scalp. There was a superficial generalised scaling on the rest of the body. Resorption defects of fingers and toes were also present.

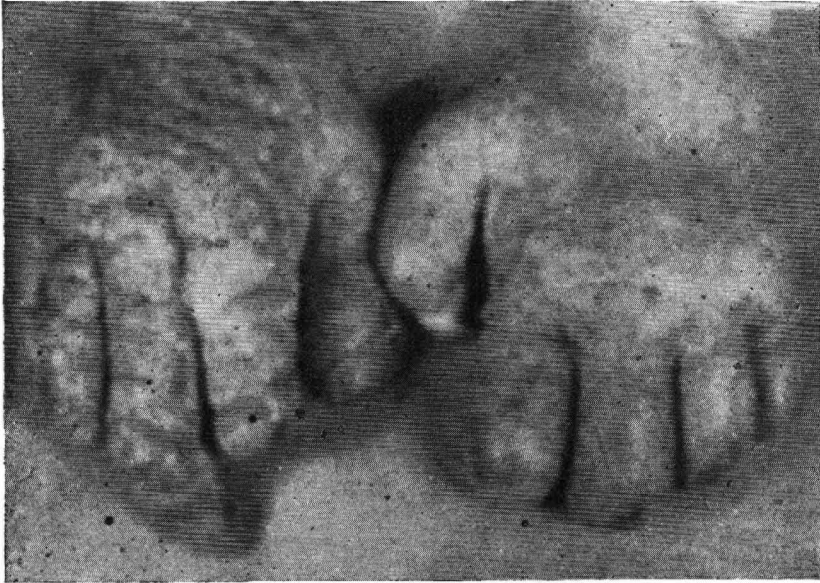

Fig. 1

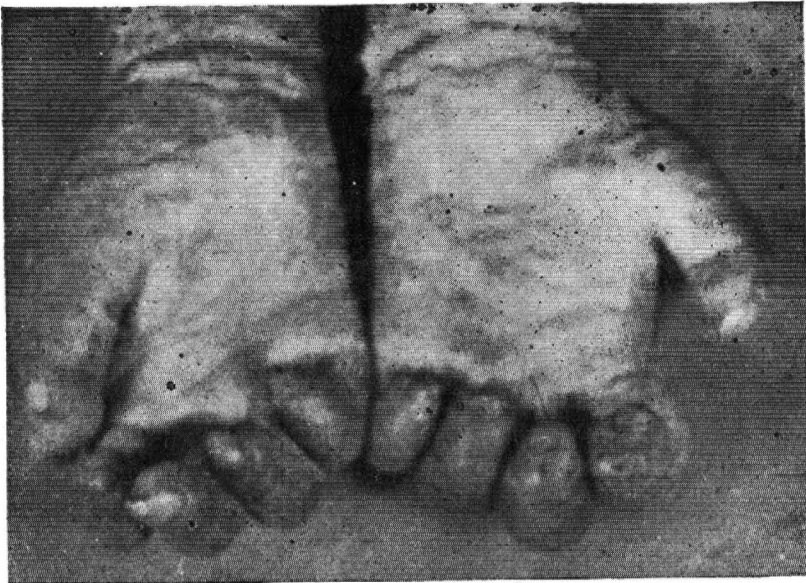

Fig. 2

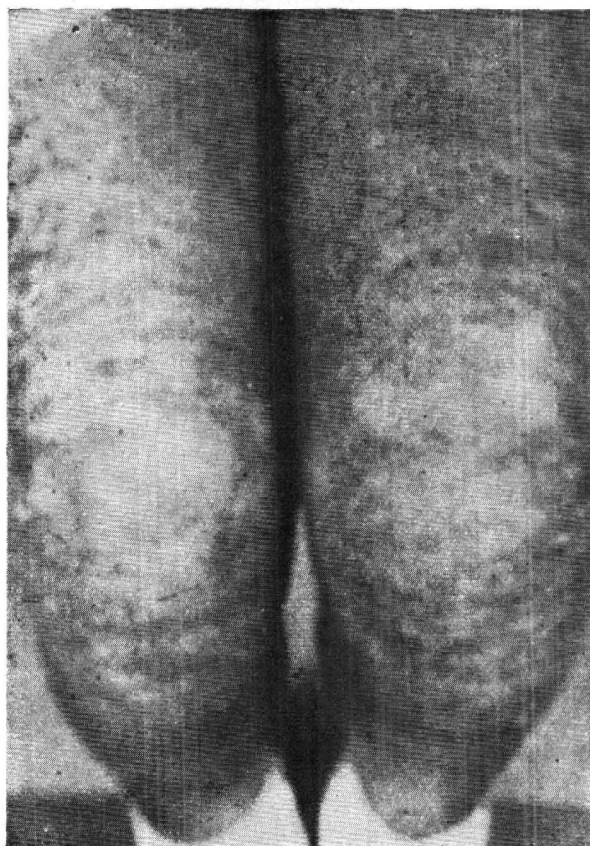


Fig. 3

- Differential diagnosis :**
1. Psoriasis
 2. Norwegian scabies
 3. Asteatotic dermatitis

Final diagnosis : Norwegian scabies

Norwegian or crusted scabies is well known to occur in association with lepromatous leprosy. In these patients a nonspecific lowering of immunological status is thought to be mainly responsible for this very widely disseminated infection with *acarus scabies var hominis*. Large numbers of parasites can be readily demonstrated by direct microscopic examination of crusts dissolved in saline.

Involvement of scalp, face, palms and soles are peculiarly common in this form of scabies even when it affects adults. Conventional short term therapy with scabidical agents is inadequate for cure of this condition. Long term vigorous antiscabetic applications are necessary to eradicate the infection.