

Indian Journal of Dermatology, Venereology & Leprology

Journal indexed with SCI-E, PubMed, and EMBASE

Vol 74 | Issue 2 | Mar-Apr 2008

C O N T E N T S

EDITORIAL

Management of autoimmune urticaria

Arun C. Inamadar, Aparna Palit 89

VIEW POINT

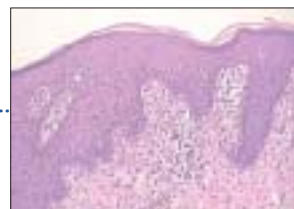Cosmetic dermatology versus cosmetology: A misnomer in need of urgent correction

Shyam B. Verma, Zoe D. Draelos 92

REVIEW ARTICLE

Psoriasiform dermatoses

Virendra N. Sehgal, Sunil Dogra, Govind Srivastava, Ashok K. Aggarwal 94



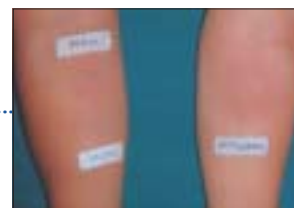ORIGINAL ARTICLES

A study of allergen-specific IgE antibodies in Indian patients of atopic dermatitis

V. K. Somani 100

Chronic idiopathic urticaria: Comparison of clinical features with positive autologous serum skin test

George Mamatha, C. Balachandran, Prabhu Smitha 105



Autologous serum therapy in chronic urticaria: Old wine in a new bottle

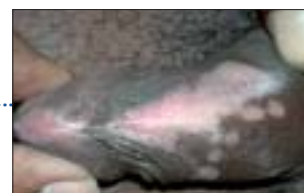A. K. Bajaj, Abir Saraswat, Amitabh Upadhyay, Rajetha Damisetty, Sandipan Dhar 109

Use of patch testing for identifying allergen causing chronic urticaria

Ashimav Deb Sharma 114

Vitiligoid lichen sclerosis: A reappraisal

Venkat Ratnam Attali, Sasi Kiran Attali 118



BRIEF REPORTS

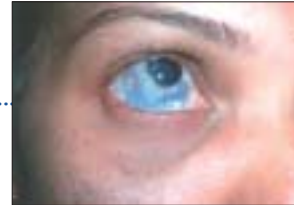Activated charcoal and baking soda to reduce odor associated with extensive blistering disorders

Arun Chakravarthi, C. R. Srinivas, Anil C. Mathew 122



Nevus of Ota: A series of 15 cases

Shanmuga Sekar, Maria Kuruvila, Harsha S. Pai 125



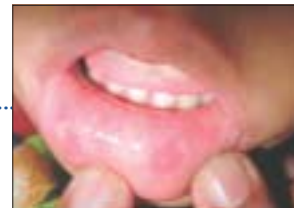Premature ovarian failure due to cyclophosphamide: A report of four cases in dermatology practice

Vikrant A. Saoji 128

CASE REPORTS

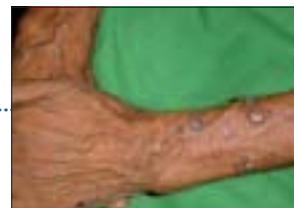Hand, foot and mouth disease in Nagpur

Vikrant A. Saoji 133



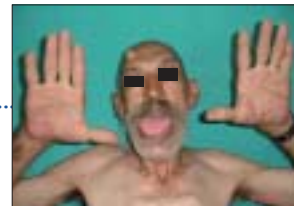Non-familial multiple keratoacanthomas in a 70 year-old long-term non-progressor HIV-seropositive man

Hemanta Kumar Kar, Sunil T. Sabhnani, R. K. Gautam, P. K. Sharma, Kalpana Solanki, Meenakshi Bhardwaj 136



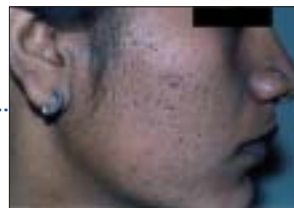Late onset isotretinoin resistant acne conglobata in a patient with acromegaly

Kapil Jain, V. K. Jain, Kamal Aggarwal, Anu Bansal 139



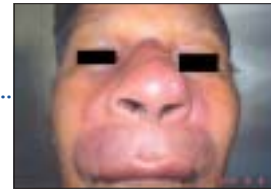Familial dyskeratotic comedones

M. Sendhil Kumaran, Divya Appachu, Elizabeth Jayaseelan 142



Nasal NK/T cell lymphoma presenting as a lethal midline granuloma

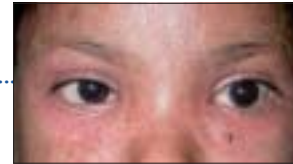Vandana Mehta, C. Balachandran, Sudha Bhat, V. Geetha, Donald Fernandes



145

Childhood sclerodermatomyositis with generalized morphea

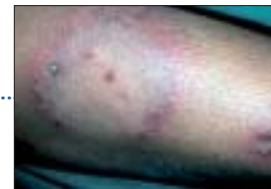Girishkumar R. Ambade, Rachita S. Dhurat, Nitin Lade, Hemangi R. Jerajani.....



148

Subcutaneous panniculitis-like T-cell cutaneous lymphoma

Avninder Singh, Joginder Kumar, Sujala Kapur, V. Ramesh.....



151

LETTERS TO EDITOR

Using a submersible pump to clean large areas of the body with antiseptics

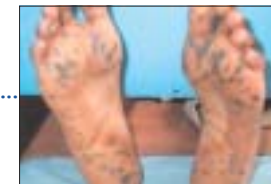C. R. Srinivas.....



154

Peutz-Jeghers syndrome with prominent palmoplantar pigmentation

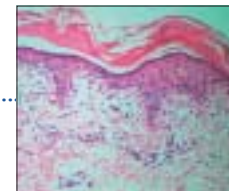
K. N. Shivaswamy, A. L. Shyamprasad, T. K. Sumathi, C. Ranganathan.....



154

Stratum corneum findings as clues to histological diagnosis of pityriasis lichenoides chronica

Rajiv Joshi



156

Author's reply

S. Pradeep Nair.....

157

Omalizumab in severe chronic urticaria

K. V. Godse.....

157

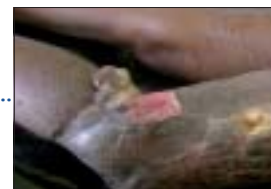Hypothesis: The potential utility of topical eflornithine against cutaneous leishmaniasis

M. R. Namazi

158

Nodular melanoma in a skin graft site scar

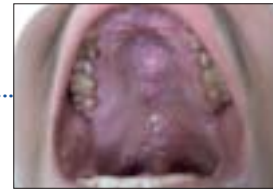A. Gnaneshwar Rao, Kamal K. Jhamnani, Chandana Konda



159

Palatal involvement in lepromatous leprosy

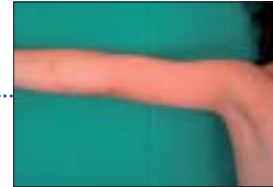A. Gnaneshwar Rao, Chandana Konda, Kamal Jhamnani.....



161

Unilateral nevoid telangiectasia with no estrogen and progesterone receptors in a pediatric patient

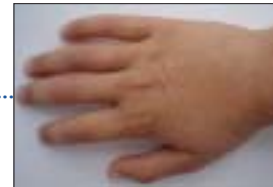F. Sule Afsar, Ragip Ortac, Gulden Diniz.....



163

Eruptive lichen planus in a child with celiac disease

Dipankar De, Amrinder J. Kanwar.....



164

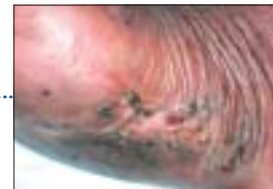Xerosis and pityriasis alba-like changes associated with zonisamide

Feroze Kaliyadan, Jayasree Manoj, S. Venkitakrishnan.....

165

Treatment of actinomycetoma with combination of rifampicin and co-trimoxazole

Rajiv Joshi.....



166

Author's reply

M. Ramam, Radhakrishna Bhat, Taru Garg, Vinod K. Sharma, R. Ray, M. K. Singh, U. Banerjee, C. Rajendran.....

168

Vitiligo, psoriasis and imiquimod: Fitting all into the same pathway

Bell Raj Eapen.....

169

Author's reply

Engin Şenel, Deniz Seçkin.....

169

Multiple dermatofibromas on face treated with carbon dioxide laser: The importance of laser parameters

Kabir Sardana, Vijay K. Garg.....

170

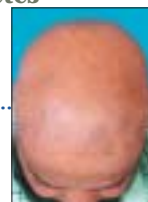Author's reply

D. S. Krupa Shankar, A. Kushalappa, K. S. Uma, Anjay A. Pai.....

170

Alopecia areata progressing to totalis/universalis in non-insulin dependent diabetes mellitus (type II): Failure of dexamethasone-cyclophosphamide pulse therapy

Virendra N. Sehgal, Sambit N. Bhattacharya, Sonal Sharma, Govind Srivastava, Ashok K. Aggarwal.....



171

Subungual exostosis

Kamal Aggarwal, Sanjeev Gupta, Vijay Kumar Jain, Amit Mital, Sunita Gupta.....

173

Clinicohistopathological correlation of leprosy

Amrish N. Pandya, Hemali J. Tailor 174

RESIDENT'S PAGE

Dermatographism

Dipti Bhute, Bhavana Doshi, Sushil Pande, Sunanda Mahajan, Vidya Kharkar 177

FOCUS

Mycophenolate mofetil

Amar Surjushe, D. G. Saple 180

QUIZ

Multiple papules on the vulva

G. Raghu Rama Rao, R. Radha Rani, A. Amareswar, P. V. Krishnam
Raju, P. Raja Kumari, Y. Hari Kishan Kumar 185



E-IDVL

Net Study

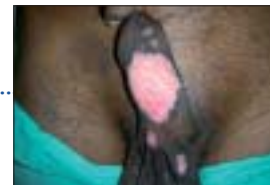Oral isotretinoin is as effective as a combination of oral isotretinoin and topical anti-acne agents in nodulocystic acne

Rajeev Dhir, Neetu P. Gehi, Reetu Agarwal, Yuvraj E. More 187

Net Case

Cutaneous diphtheria masquerading as a sexually transmitted disease

T. P. Vetrichevvel, Gajanan A. Pise, Kishan Kumar Agrawal,
Devinder Mohan Thappa 187



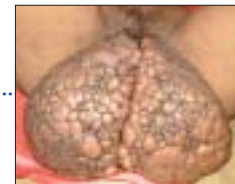Net Letters

Patch test in Behcet's disease

Ülker Gül, Müzeyyen Gönül, Seray Külcü Çakmak, Arzu Kılıç 187

Cerebriform elephantiasis of the vulva following tuberculous lymphadenitis

Surajit Nayak, Basanti Acharjya, Basanti Devi, Satyadarshi Pattnaik,
Manoj Kumar Patra 188



Net Quiz

Vesicles on the tongue

Saurabh Agarwal, Krishna Gopal, Binay Kumar 188



Chronic idiopathic urticaria: Comparison of clinical features with positive autologous serum skin test

George Mamatha, C. Balachandran, Prabhu Smitha

Department of Skin and STD, Kasturba Medical College, Manipal - 576 104, India

Address for correspondence: Dr. Smitha Prabhu, Department of Skin and STD, Kasturba Medical College, Manipal - 576 104, India.
E-mail: smithaprabhu@msn.com

ABSTRACT

Background: Chronic idiopathic urticaria (CIU), in its extremely severe form, can pose a therapeutic challenge to the treating physician. It has been noted that in one third of such patients, autoantibodies against the IgE receptor are seen and such patients have more severe and unremitting urticaria. **Aim:** To compare clinical features of autoimmune urticaria with those of other CIU patients. **Methods:** We conducted a prospective study in an attempt to correlate the clinical features with autoantibodies, indirectly detected via the autologous serum skin test (ASST), which is the simplest and the best *in vivo* clinical test for detection of basophil histamine-releasing activity. **Discussion:** Out of 100 patients with chronic idiopathic urticaria, 34 showed a positive reaction to the autologous serum skin test and it was found that the frequency and severity of attacks was higher in these patients. **Conclusion:** ASST may be used as a simple and cost-effective test for the classification of chronic urticaria, which has proven to be a therapeutic challenge to the treating physician.

Key Words: Autologous serum skin test, Chronic idiopathic urticaria, Histamine

INTRODUCTION

Chronic idiopathic urticaria (CIU) is manifested as widespread, short-lived (lasting less than 24 hours) weals occurring daily or almost daily for at least 6 weeks and where a predominant physical cause has been excluded. CIU is extremely disabling in its severe form and can be difficult to treat. Mast cell degranulation is of central importance in the pathogenesis of CIU. Recent reports have indicated the presence of autoantibodies in about one third of all patients with CIU. These histamine-releasing autoantibodies are directed against the α subunit of the high affinity IgE receptor, $F_{\epsilon}R_1\alpha$. Patients with autoantibodies in their sera have no distinctive diagnostic clinical features though they do tend to have more severe and unremitting urticaria.^[1-3]

The basophil histamine release assay is currently the gold standard for detecting these functional autoantibodies in the serum of patients with chronic urticaria. However, this bioassay is difficult to standardize because it requires fresh

basophils from healthy donors, is time-consuming and it remains confined to research centers. Western analysis, enzyme-linked immunosorbent assays (ELISA) and flow cytometry may be useful for screening in the future but they need to be validated.

Autologous serum skin test (ASST) is the simplest and the best *in vivo* clinical test for the detection of basophil histamine-releasing activity. ASST has a sensitivity of approximately 70% and a specificity of 80% when read at 30 min as a pink serum-induced weal ≥ 1.5 mm bigger than the adjacent normal saline control injection site. It may be used as a reasonably predictive clinical test to indicate the presence of functional circulating autoantibodies.^[4] We studied clinical features of CIU and correlated them with results of ASST.

METHODS

In a prospective study, we evaluated the clinical features of 100 patients of chronic idiopathic urticaria. In all patients, physical

How to cite this article: Mamatha G, Balachandran C, Prabhu S. Chronic idiopathic urticaria: Comparison of clinical features with positive autologous serum skin test. Indian J Dermatol Venereol Leprol 2008;74:105-8.

Received: August, 2007. **Accepted:** December, 2007. **Source of Support:** Nil. **Conflict of Interest:** Nil.

urticaria, food and drug allergies as well as urticarial vasculitis were ruled out after taking detailed history and relevant laboratory investigations. In all patients, antihistamines were withdrawn 2 days prior to ASST. Clinical details of all patients were recorded using a standard format. Details included duration of disease in months, duration of individual weals in hours, frequency of attacks, distribution of wheals, associated systemic symptoms (fever, joint and abdominal pains), provoking physical factors, food and drug intolerance, seasonal variation and associated angioedema. Informed consent was taken from all patients. Patients were subjected to a physical provocation test and laboratory investigations based on individual history. In patients with clinical features suggestive of systemic involvement, appropriate laboratory tests were done, these included: complete blood count, urine routine examination, liver function tests (LFT), renal function tests (RFT), thyroid function tests (TFT), C3 and C4 complement level estimation and antinuclear antibody (ANA).

Methodology of ASST

Samples of 5 ml of venous blood were collected in sterile Vacutainers without a clotting accelerator and allowed to clot at room temperature for 30 min. Serum was sent to a clinical laboratory for centrifugation at 2000 rpm for 15 min. Samples of 0.05 ml of autologous serum and 0.9% sterile normal saline were separately injected intradermally into the volar aspect of the right forearm with a gap of 5 cm between injection sites. About 0.05 ml of histamine (10 µg/ml) was injected into volar aspect of the left forearm as a positive control. Weal and flare response was measured at 30 min. ASST was deemed to be positive if a serum-induced weal which was both red and had a diameter bigger than a saline-induced response by ≥ 1.5 mm was seen at 30 min.

Statistical analysis

Descriptive statistics was used to summarize data for comparison between ASST-positive and ASST-negative groups. Chi Square test was used for categorical variables and the nonparametric test (Mann-Whitney test) was used for other variables as they were not distributed normally.

Observation

Out of 100 patients, 34 patients (34%) showed a positive reaction to the autologous serum test in the form of a weal and flare response, which was 1.5 mm bigger than the saline control read at 30 min [Figure 1].

Clinical characteristics

Patients were categorized into two groups (ASST-positive and -negative) based on ASST, for evaluation of clinical features.

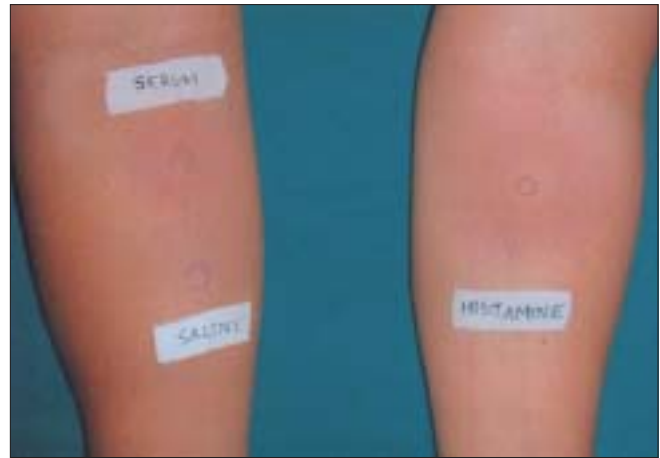

Figure 1: Positive response to ASST - intradermal injection of autologous serum has provoked a weal of 7 mm diameter

There was no significant difference in age distribution among patients with and without autoantibodies at the time of assessment [Table 1]. Of a total of 100 patients, 56 were females and 44 males. Eighteen out of the 34 ASST-positive patients (52.94%) and 38 out of the 66 ASST-negative patients (57.58%) were female.

Median duration was 12 months and 15 months in ASST positive and ASST-negative groups, respectively. There was no significant difference in the duration of disease between the two groups (Mann-Whitney Test). Wheals lasted for significantly longer duration in patients with positive ASST, the median duration being four hours for ASST-positive compared to two hours in ASST-negative individuals ($P = 0.001$, Mann-Whitney Test). Patients with positive ASST had more frequent attacks which was statistically significant

Table 1: Age distribution of autologous serum skin test-positive and -negative individuals

| Age group (years) | Autologous serum skin test | |
|-------------------|----------------------------|----------|
| | Positive | Negative |
| 12-20 | 0 | 8 |
| 21-30 | 10 | 20 |
| 31-40 | 7 | 14 |
| 41-50 | 14 | 16 |
| >50 | 3 | 8 |

Table 2: Frequency of urticarial attacks in autologous serum skin test-positive and -negative individuals

| Frequency of attacks | Autologous serum skin test | |
|----------------------|----------------------------|-----------|
| | Positive | Negative |
| Daily | 24 (71) | 34 (51.5) |
| 1-3/week | 10 (29.4) | 25 (37.8) |
| 1-3/month | 0 | 7 (10.6) |

compared to the ASST-negative group ($P = 0.038$, Mann-Whitney Test) [Table 2]. Of the total 100 patients, 32 patients showed a positive challenge test for simple dermographism, which occurred more frequently in ASST-negative patients (29/32) than in those who were ASST-positive (3/32) ($P < 0.001$, Fischer's Exact Test). Sixty eight of 100 patients gave details regarding the affected sites. There was no significant difference between ASST-positive and -negative patients regarding the affected sites (Mann-Whitney Test). Abnormal TFT was obtained in 5/20 patients, three of these patients had positive ASST (no significant correlation with the ASST results, Chi-Square Test). ANA was done for 10/100 patients and was positive for one patient.

DISCUSSION

The present study has evaluated patients with chronic idiopathic urticaria (CIU) by autologous serum skin testing and compared the clinical features of patients with positive and negative ASST results. The proportion of patients with CIU who showed a positive reaction to ASST was 34%, which is comparable with earlier reports [Table 3].

Sabroe *et al.* found evidence of functional autoantibodies in 31% of 107 patients with chronic urticaria.^[5] Zweiman *et al.* reported basophil histamine releasing activity in 30% of 70 chronic urticaria sera^[6] while Tong *et al.* found that 52% of 50 chronic urticaria sera released histamine from basophils.^[7]

It is now established that circulating autoantibodies against the high affinity IgE receptor ($Fc\epsilon R_1$) or against IgE can be found in approximately one third of all patients with CIU.^[1] That these autoantibodies are functional has been demonstrated both *in vivo* and *in vitro* by induction of a weal and flare response to an intradermal injection of

serum (ASST) and basophil and mast cell histamine release assays respectively. In addition, removal of autoantibodies by plasmapheresis has been shown to produce clinical improvement in patients with CIU.^[2] The clinical features of patients with CIU were defined in several studies before the identification of autoantibodies.^[8,9] Now it is known that there are at least two subsets of patients with CIU - those with and without autoantibodies.

In the present study, the same investigator has recruited the patients and done the test. Thus, there is a possibility of bias due to lack of blinding. However, since the test interpretation was clear-cut and unambiguous, we feel this would not significantly affect the results. Sabroe *et al.* compared clinical features of patients with and without autoantibodies and concluded that patients with autoantibodies in their sera have more severe and unremitting urticaria.

The median duration of disease was 12 and 15 months for ASST-positive and -negative patients respectively, which was not statistically significant compared to the previous study by Sabroe *et al.* Lesions lasted for significantly longer durations in patients with a positive ASST, median duration being four hours when compared to two hours in ASST-negative individuals ($P = 0.001$). Patients with a positive ASST had more frequent attacks, which was statistically significant compared to the ASST-negative group ($P = 0.038$). Majority of patients (24/34) with positive ASST had almost daily attacks.

A study done by Sabroe *et al.*^[5] concluded that patients with autoantibodies in their sera have more severe attacks according to several parameters including frequency, duration of individual episodes and sites involved. This is in concordance with our study, which noted frequent long-lasting episodes in ASST-positive patients.

Angioedema occurred in 15 of our 100 patients. In a similar study done by Sabroe *et al.* angioedema occurred in 93 out of 107 cases. In both the studies, there was no significant difference between ASST-positive or -negative patients in the incidence, duration, frequency or distribution of angioedema.

There was no significant difference between ASST-positive or -negative patients regarding sites affected or diurnal variation. Majority of patients (90%) had generalized lesions involving the trunk and extremities.

Of the total 100 patients, 32 patients showed a positive challenge test for dermographism. Dermographism

Table 3: Comparison of our study with previous study

| Authors | Sabroe <i>et al.</i> | Present study |
|--|----------------------|---------------|
| Mean age of presentation | 45 | 34 |
| Male/female ratio | 88/19 | 44/56 |
| Percentage of patients with autoimmunity | 31% | 34% |
| Correlation of frequency and positive ASST | Present | Present |
| Correlation of duration and positive ASST | Present | Present |
| Angioedema | 93/107 | 15/100 |
| Correlation of systemic symptoms and positive ASST | Present | Absent |
| Association with autoimmune thyroid disease | Absent | Absent |

occurred more frequently in 29/32 ASST-negative patients than in those (3/32) who were ASST-positive ($P < 0.001$). Dermographic subjects comprise a special group. They do not have autoantibodies according to *in vitro* tests but manipulation of skin while injecting the sample may cause a weal and flare response regardless of the substance injected and may be taken as false positive responses.^[4]

ASST-positive patients had significantly more systemic symptoms in a study by Juhlin.^[9] In particular, gastrointestinal symptoms and flushing occur more frequently in patients with autoantibodies.^[9] Our study failed to reveal such associations.

Autoimmune diseases like thyroid disease, vitiligo, diabetes mellitus, pernicious anemia and rheumatoid arthritis were reported more commonly in patients with autoimmune urticaria.^[5,10]

In our study, out of ten patients tested, ANA was positive in one patient who also had positive ASST. Although a higher frequency of autoimmune disease has been reported in patients with autoimmune urticaria by O' Donnell *et al.*^[10] we did not find an increased incidence of other autoimmune diseases in our clinical study.

Abnormal TFT values were detected in three ASST-positive patients. The association of chronic urticaria with thyroid autoimmunity has been studied by Leznoff *et al.*^[11] and it has been postulated that thyroid autoimmunity may play a role in the pathogenesis of chronic urticaria and angioedema. However, in contrast with previous studies,^[11] we did not find any difference in the incidence of thyroid disease. This is likely to be because an insufficient number of patients was included for the study of a disease of low incidence (thyroid autoimmunity) or because TFT and thyroid autoantibodies were not routinely measured for all patients. Thus, TFT alone is not enough to rule out thyroid disease and the thyroid antibody test should be carried out in all CIU patients. Hence, patients with autoimmune urticaria have no distinctive, diagnostic clinical or histopathological features, which differentiate them from nonautoimmune cases although they tend to have more severe urticaria.

In our setting, ASST is the only available test for the diagnosis of autoimmune urticaria. It is a simple, inexpensive, semiinvasive and easy-to-perform test which can be done and recorded by the dermatologist himself

to determine whether the patient's CIU is autoimmune in origin. As conventional approaches of management may be unsuccessful, ASST is especially important from the therapeutic point of view as it can help the dermatologist to commit himself to initiate immunosuppressive therapy in such patients.

ACKNOWLEDGMENT

We are thankful to Mrs. Meera B and Mr. Dinesh P, our laboratory technicians, who helped us with ASST.

REFERENCES

1. Niimi N, Francis DM, Kermani F, O'Donnell BF, Hide M, Kobza-Black A, *et al.* Dermal mast cell activation by autoantibodies against the high affinity IgE receptor in chronic urticaria. *J Invest Dermatol* 1996;106:1001-6.
2. Grattan CE, Wallington TB, Warin RP, Kennedy CT, Bradfield JW. A Serological mediator in chronic idiopathic urticaria: A clinical, immunological and histological evaluation. *Br J Dermatol* 1986;114:583-90.
3. Fiebiger E, Maurer D, Holub H, Reininger B, Hartmann G, Woisetschläger M, *et al.* Serum IgG autoantibodies directed against the α chain of FcE R1: A selective marker and pathogenetic factor for a distinct subset of chronic urticaria patients? *J Clin Invest* 1995;96:2606-12.
4. Sabroe KA, Grattan CE, Francis DM, Barr RM, Kobza Black A, Greaves MW. The autologous serum skin test: A screening test for autoantibodies in chronic idiopathic urticaria. *Br J Dermatol* 1999;140:446-52.
5. Sabroe RA, Seed PT, Francis DM, Barr RM, Kobza Black A, Greaves MW. Chronic idiopathic urticaria: Comparison of the clinical features of patients with ondurthout anti FCER1 or anti IgE auto antibodies. *J Am Acad Dermatol* 1999;40:443-50.
6. Zweiman B, Valenzano M, Atkins PC, Tanus T, Getsy JA. characteristics of histaminereleasing activity in the sera of patients with chronic idiopathic urticaria. *J Allergy Clin Immunol* 1996;98:89-98.
7. Tong LJ, Balakrishnan G, Kochan JP, Kinét JP, Kaplan AP. Assessment of autoimmunity in patients with chronic idiopathic urticaria. *J Allergy Clin Immunol* 1997;99:461-5.
8. Champion RH. Urticaria then and now. *Br J Dermatol* 1998;119:427-36.
9. Juhlin L. Recurrent urticaria: Clinical investigations of 330 patients. *Br J Dermatol* 1981;104:369-81.
10. O'Donnell BF, Swana GT, Kobza Black A. Organ and nonorgan specific autoimmunity in chronic urticaria. *Br J Dermatol* 1995;133:42A.
11. Leznoff A, Sussman GL. Syndrome of idiopathic chronic urticaria and angioedema with thyroid autoimmunity. *J Allergy Clin Immunol* 1989;84:66-71.