

Dermoscopy: An easy way to solve the diagnostic puzzle in pityriasis versicolor

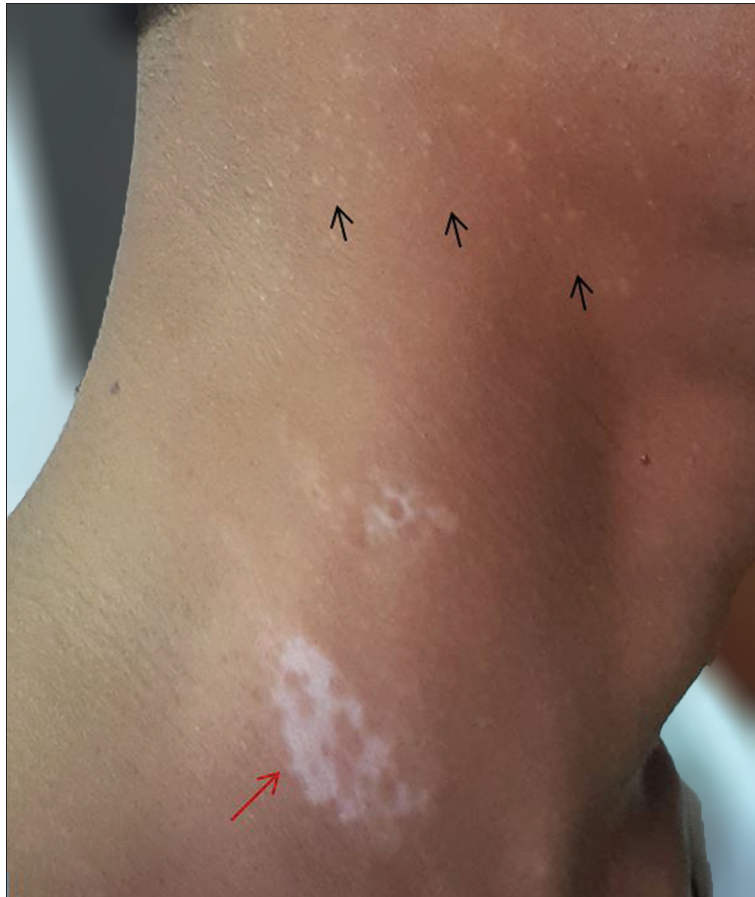

Figure 1: Patient with vitiligo (red arrow) showing multiple hypopigmented to depigmented macules (black arrows) on the neck

A 28-year-old man, undergoing treatment for vitiligo, presented with complaints of new lesions on the neck for the last 1 week. On examination, multiple hypopigmented macules were seen on the neck [Figure 1]. “Scratch sign” or “coup d’angle sign” was negative on examination with naked eye. On examination with a dermoscope (DermLite dl3 dermoscope, noncontact, polarizing, 10× magnification), very fine scales were present along the natural skin creases on a background of hypopigmented skin. Scaling was inconspicuous on the area between the skin creases. On stretching the skin these fine scales appeared more prominent under dermoscope but were still inconspicuous with naked eye [Figure 2]. Potassium hydroxide (KOH) mount confirmed the diagnosis of pityriasis versicolor.

Access this article online	
Quick Response Code:	Website: www.ijdvl.com
	DOI: 10.4103/ijdvl.IJDVL_816_16

This is an open access journal, and articles are distributed under the terms of the Creative Commons Attribution-NonCommercial-ShareAlike 4.0 License, which allows others to remix, tweak, and build upon the work non-commercially, as long as appropriate credit is given and the new creations are licensed under the identical terms.

For reprints contact: reprints@medknow.com

How to cite this article: Thomas N, Malakar S. Dermoscopy: An easy way to solve the diagnostic puzzle in pityriasis versicolor. Indian J Dermatol Venereol Leprol 2019;85:664-5.

Received: October, 2016. **Accepted:** May, 2018.




Figure 2: Dermoscopic picture showing fine scales along the skin markings with sparing of the skin between the markings



Figure 3: Magnified dermoscopic picture showing scales arranged along diamond-shaped skin markings giving a "wire fence" or "fish net appearance"

The dermoscopic feature of presence of fine scaling along the normal skin markings on a background of hypopigmented/hyperpigmented skin, giving it a "wire fence" appearance, may serve as a useful clue for easy and quick diagnosis of pityriasis versicolor [Figure 3].

Declaration of patient consent

The authors certify that they have obtained all appropriate patient consent forms. In the form, the patient has given his consent for his images and other clinical information to be reported in the journal. The patient understands that name and initials will not be published and due efforts will be made to conceal identity, but anonymity cannot be guaranteed.

Financial support and sponsorship

Nil.

Conflicts of interest

There are no conflicts of interest.

Naveen Thomas, Subrata Malakar

Rita Skin Foundation, Kolkata, West Bengal, India

Correspondence: Dr. Subrata Malakar,
Rita Skin Foundation, GD Block, Salt Lake City, Kolkata, West Bengal, India.
E-mail: subr3575@gmail.com