

Dermatoscopic evaluation of three cases of nevus lipomatosus cutaneous superficialis

Sir,
Nevus lipomatosus cutaneous superficialis is an uncommon hamartoma characterized by ectopic presence of mature adipocytes in the papillary dermis. The use of dermatoscopy has extended

beyond skin cancers and is increasingly being utilized as a diagnostic aid in many benign and inflammatory conditions.¹ We herein describe the dermatoscopic features of three cases of nevus lipomatosus cutaneous superficialis. We also report an index case

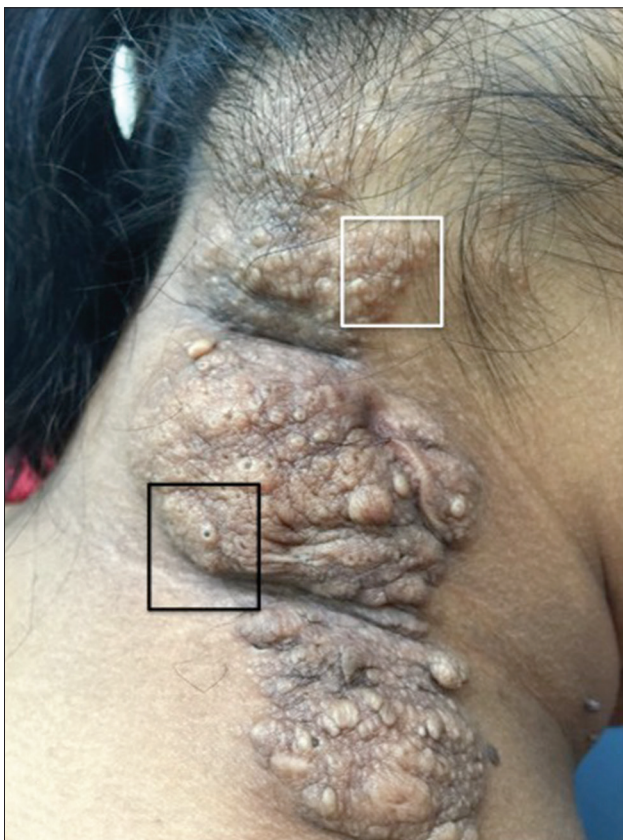

Figure 1a: Nevus lipomatosus cutaneous superficialis on the nape of the neck. Dermatoscopic evaluation was conducted from sites highlighted by white and black boxes

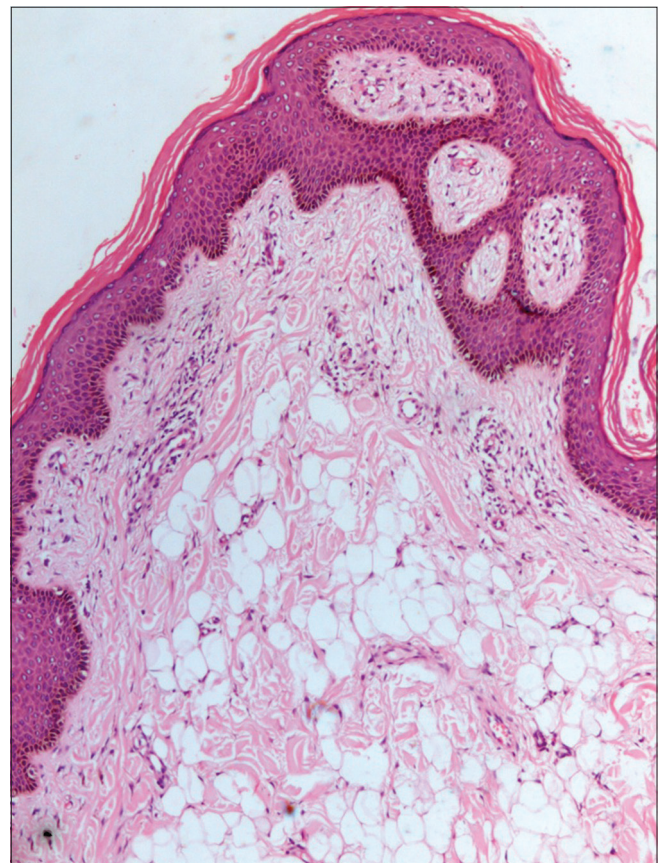


Figure 1b: Lobules and single scattered mature adipocytes in the upper dermis with overlying acanthosis of the epidermis (H and E, ×100)

on an unusual site in which dermatoscopy aided in establishing the diagnosis.

A 20-year-old lady presented to the dermatology outpatient department with an asymptomatic lesion on the nape of her neck which was gradually progressive over the past 7 years. Cutaneous examination revealed a skin colored, well-defined plaque of 30 cm × 15 cm size extending from the lower scalp hair margin to the nape of the neck on the left side [Figure 1a]. It had an irregular surface and was studded with multiple comedones [Figure 1a]. A punch skin biopsy showed globules of mature adipocytes deposited between the normal collagen fibers of the papillary dermis [Figure 1b].

Dermatoscopic evaluation was performed in the index case from the sites marked by white [Figure 2a] and black [Figure 2b] boxes and two other patients [Figure 2c and d] of biopsy proven nevus lipomatosus cutaneous superficialis using a DermLite II hybrid m dermatoscope at 10× magnification in polarized contact mode. Photographs were captured by Apple iPhone 6 Plus with the aid of DermLite app. Five dermatoscopic features were noted (1) cerebriform surface formed by gyri (ridges) and sulci (fissures), the latter filled with keratin products [Figure 2b, c and d] (2) web-like regular pigment network consisting of brown lines and yellowish holes creating a honeycomb-like pattern [Figure 2c and d] (3) rim of the cerebriform surface showed a “ground glass” white film or “veil” [Figure 2c, green arrow and arc] (4) yellowish structureless areas, some of them showing a perifollicular distribution [Figure 2a and d, red circles] and (5) comedo-like openings [Figure 2b, black arrow].

Two variants of nevus lipomatosus cutaneous superficialis have been described, the classical and the solitary.² The classic variant manifests as multiple, soft, pedunculated, cerebriform papules or nodules that often coalesce to form plaques in a zonal pattern. The common sites of occurrence of the classical variant are the flank, buttocks and upper thigh, though it is known to occur on unusual sites such as upper trunk, abdomen, axillae, genitalia and face where it can pose a diagnostic challenge.^{3,4} The solitary variant presents as a solitary, dome-shaped, sessile papule or nodule and can be misdiagnosed as giant skin tag or solitary neurofibroma. In such a situation, dermatoscopic evaluation aids in establishing the diagnosis and avoids skin biopsy, especially in infants and young children. However, we were unable to find any previous report describing the dermatoscopic features of nevus lipomatosus cutaneous superficialis.

The index case had her lesion located on the nape of the neck, an uncommon site for nevus lipomatosus cutaneous superficialis. The site and distribution of the lesion were suggestive of segmental neurofibromatosis and nevus sebaceous. Based on our experience with dermatoscopic evaluation of previous two cases, nevus lipomatosus cutaneous superficialis was strongly considered and was further confirmed by histopathological examination.

Dermatoscopic features of neurofibromatosis have been recently described and include peripheral pigmented network, a halo of brown pigmentation, pink-red structureless areas, fingerprint-like structures, scar-like areas, fissures and blood vessels.⁵ Dermatoscopy of nevus sebaceous shows bright yellow dots not associated with hair follicles.⁶ None of these features were seen in our patients.

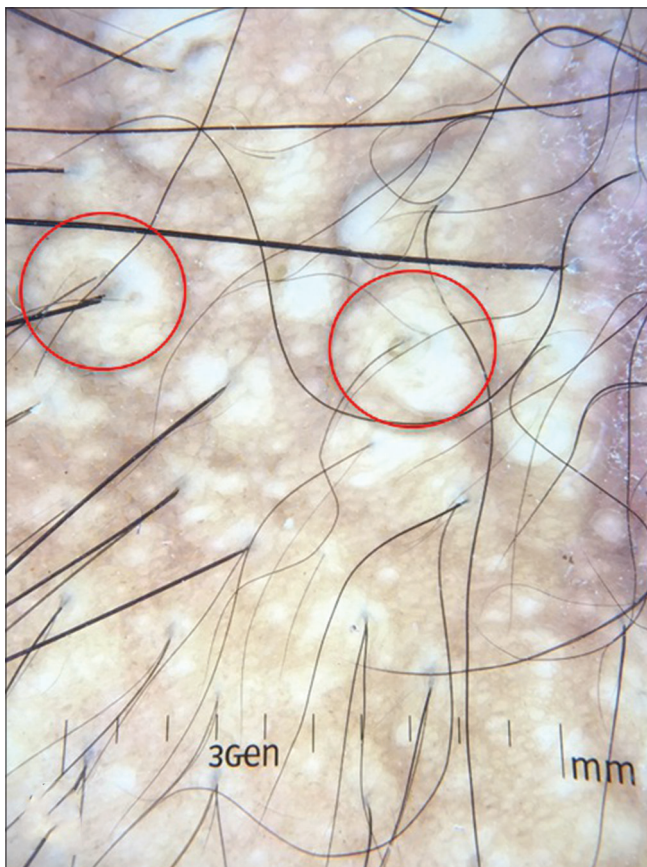

Figure 2a: Dermatoscopic evaluation showing yellowish structureless areas (red circles), some of them in perifollicular distribution

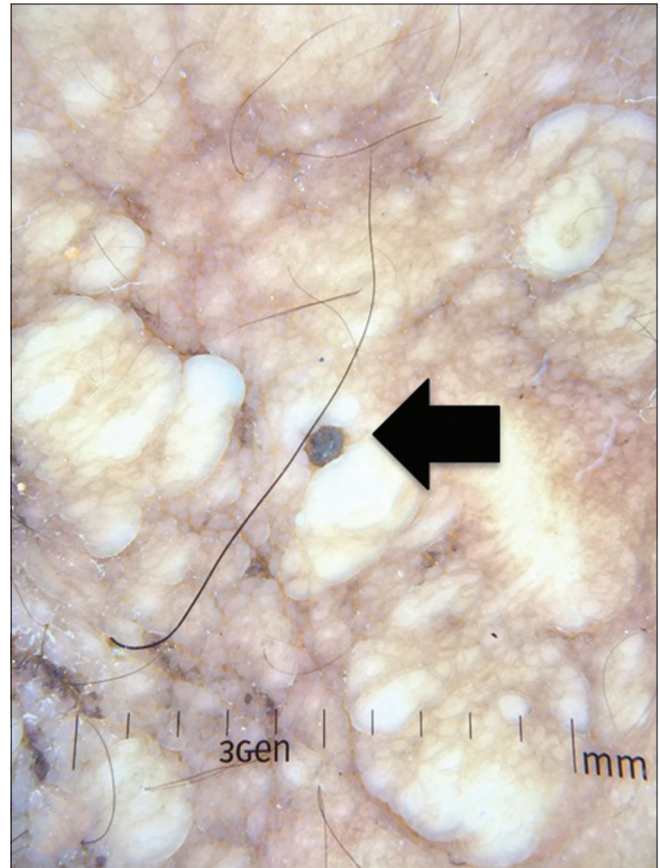


Figure 2b: Comedo-like opening (arrow)

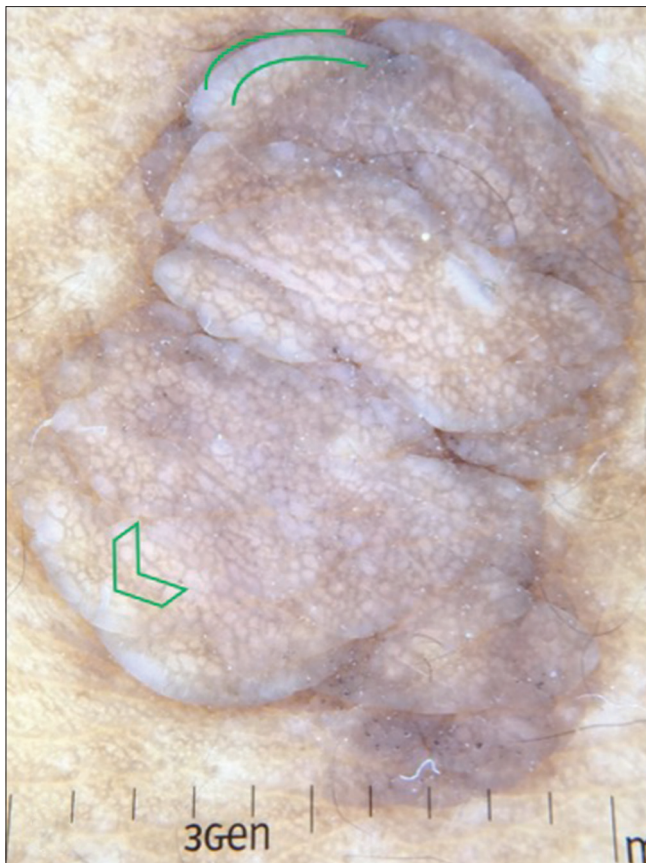


Figure 2c: Cerebriform surface with honeycomb-like pigmentary network admixed with yellowish holes and a rim of white veil (green arc and arrowhead)

The cerebriform surface seen on dermatoscopy represents the uneven surface seen clinically. The cerebriform surface formed by gyri and sulci may also be seen in dermal nevus and seborrheic keratosis while comedo-like openings are usually characteristic of seborrheic keratosis.⁷ However, the presence of yellow structureless areas representing dermal adipocytes is more suggestive of nevus lipomatosus cutaneous superficialis. The presence of a regular pigment network in our cases indicates the relative histological preservation of the normal rete ridge in most nevus lipomatosus cutaneous superficialis as opposed to disrupted rete ridge anatomy in neurofibromas (epidermal flattening) and nevus sebaceous (acanthosis). The pigment network was distinct in our cases since all three patients belonged to skin phototype IV and V. This particular feature may require enhancement with nonpolarized immersion dermatoscopy in lower skin types. Yellow dots seen in nevus sebaceous represent sebaceous glands and are generally not associated with hair follicles in infancy.⁶ However, the developed sebaceous glands during late childhood in nevus sebaceous may surround small hair follicles. Therefore, the likelihood of finding perifollicular yellow dots in nevus sebaceous is low (especially in infancy). In contrast, dermatoscopy of nevus lipomatosus cutaneous superficialis shows yellow structureless areas in perifollicular distribution around terminal hair follicles [Figure 2a].

In conclusion, no single dermatoscopic feature is distinctive of nevus lipomatosus cutaneous superficialis. However, the combination of the above-mentioned dermatoscopic features aids in differentiating

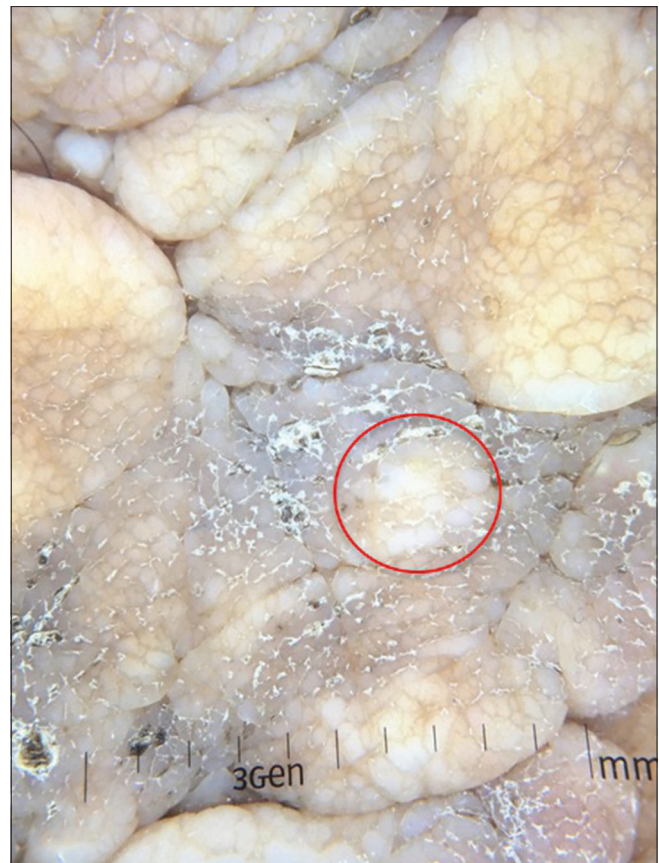

Figure 2d: Gyri and sulci with sulci containing keratinous debris and yellow structureless area (red circle)

it from neurofibroma and nevus sebaceous and is a helpful adjunct in its clinical diagnosis.

Financial support and sponsorship

Nil.

Conflicts of interest

There are no conflicts of interest.

**Keshavamurthy Vinay, Gitesh U. Sawatkar,
Uma Nahar Saikia¹, Muthu Sendhil Kumaran**

Departments of Dermatology, Venereology and Leprology and
¹Histopathology, Postgraduate Institute of Medical Education and Research,
Research, Chandigarh, India

Correspondence: Dr. Muthu Sendhil Kumaran,
Department of Dermatology, Venereology and Leprology,
Postgraduate Institute of Medical Education and Research,
Sector 12, Chandigarh - 160 012, India.
E-mail: drsen_2000@yahoo.com

References

1. Russo T, Piccolo V, Lallas A, Argenziano G. Recent advances in dermoscopy. *F1000Res* 2016;5. pii: F1000Rev-184.
2. Moss C, Shahidullah H. Naevi and other Developmental Defects. In:

- Burns T, Breathnach S, Cox NH, Griffiths C, editors. Rook's Textbook of Dermatology. 8th ed. Oxford: Blackwell Scientific Publications; 2010. p. 658-9.
3. Lane JE, Clark E, Marzec T. Nevus lipomatosus cutaneus superficialis. *Pediatr Dermatol* 2003;20:313-4.
 4. Sendhil Kumaran M, Narang T, Dogra S, Saikia UN, Kanwar AJ. Nevus lipomatosus superficialis unseen or unrecognized: A report of eight cases. *J Cutan Med Surg* 2013;17:335-9.
 5. Duman N, Elmas M. Dermoscopy of cutaneous neurofibromas associated with neurofibromatosis type 1. *J Am Acad Dermatol* 2015;73:529-31.
 6. Neri I, Savoia F, Giacomini F, Raone B, Aprile S, Patrizi A. Usefulness of dermoscopy for the early diagnosis of sebaceous naevus and differentiation from aplasia cutis congenita. *Clin Exp Dermatol* 2009;34:e50-2.
 7. Hirokawa D, Lee JB. Dermoscopy: An overview of subsurface morphology. *Clin Dermatol* 2011;29:557-65.

This is an open access article distributed under the terms of the Creative Commons Attribution-NonCommercial-ShareAlike 3.0 License, which allows others to remix, tweak, and build upon the work non-commercially, as long as the author is credited and the new creations are licensed under the identical terms.

Access this article online	
Quick Response Code:	Website: www.ijdv1.com
	DOI: 10.4103/ijdv1.IJDVL_677_16

How to cite this article: Vinay K, Sawatkar GU, Saikia UN, Kumaran MS. Dermoscopic evaluation of three cases of nevus lipomatosus cutaneus superficialis. *Indian J Dermatol Venereol Leprol* 2017;83:383-6.

Received: August, 2016. **Accepted:** October, 2016.

© 2017 Indian Journal of Dermatology, Venereology, and Leprology | Published by Wolters Kluwer - Medknow