

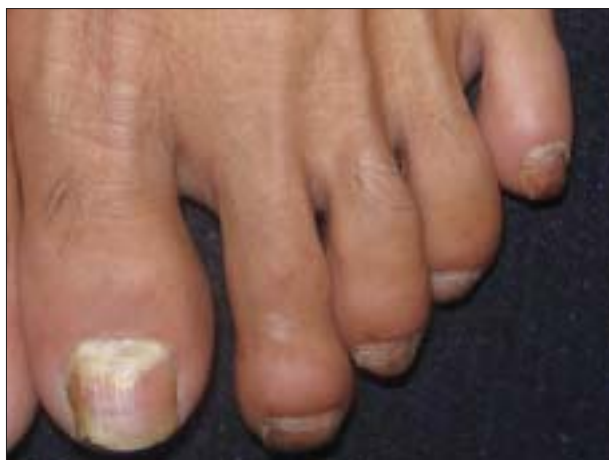## Proximal subungual onychomycosis caused by *Aspergillus flavus* in a HIV-positive patient

Sir,

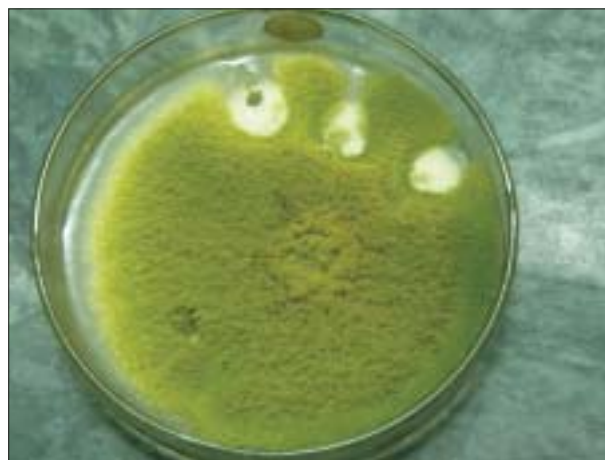
Onychomycosis is defined as a fungal infection of the nail caused by dermatophytes, nondermatophyte

moulds (NDM) and yeasts. Types of onychomycosis are distal-lateral subungual onychomycosis (DLSO), proximal subungual onychomycosis (PSO), white superficial onychomycosis and total dystrophic onychomycosis. DLSO is the most common clinical type. PSO is uncommon in the general population but is frequently associated with human immunodeficiency virus (HIV) infection and is mostly caused by *Trichophyton rubrum* and *Trichophyton megninii*. PSO is nearly pathognomonic of HIV infection.<sup>[1,2]</sup> Multiple fungal species and unusual opportunistic fungi are frequently cultured from HIV-infected patients and may be a reflection of the degree of immunosuppression.<sup>[3]</sup> Previously regarded as contaminants, yeasts and moulds are now being increasingly recognized as pathogens in fungal nail infection.<sup>[4]</sup> *Aspergillus flavus* is a widespread saprophyte found in soil, seeds, fruits and decaying vegetation. We report a rare case of PSO caused by *Aspergillus flavus* in an HIV-positive patient.

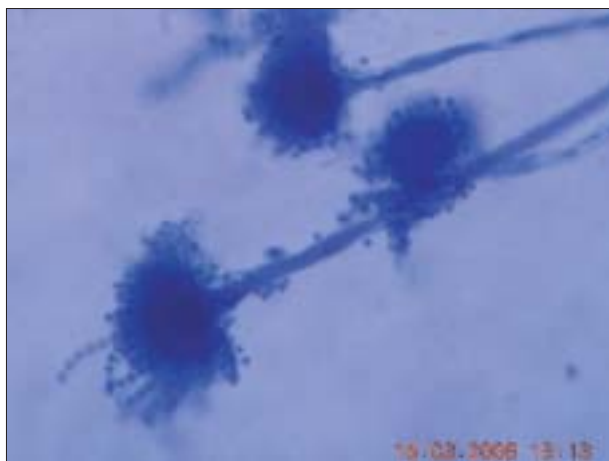
A 30-year-old male patient, farmer by occupation, presented with severe tingling sensation and burning pain affecting both the lower extremities for the past 2 months. He gave history of unprotected heterosexual genito-genital exposure and loss of weight for the past 1.5 years. General examination revealed thin, cachexic built of the patient. Cutaneous examination revealed diffuse greasy scales involving the scalp, eyebrow and retroauricular region. The oral mucous membrane showed a curdy-white plaque involving the dorsum of the tongue. The left great toe nail revealed whitish discoloration of the proximal nail plate with brittleness [Figure 1]. Nail folds were normal. Clinically, the possibility of Hansen's disease was ruled out. With this history and clinical examination, the possibility of underlying immunosuppression was thought and the case was investigated. Routine investigations revealed gross anemia. Blood sugar levels were normal. Enzyme-linked immunosorbent assay test was positive for HIV antibodies. The proximal nail plate of the left great toe was scraped and pared with surgical blade no. 15. With the help of a curette, material from the proximal nail bed was taken. The sample was sent to the microbiology department for KOH examination and culture. KOH examination revealed septate branching mycelium. Culture carried out on Sabouraud's dextrose agar with chloramphenicol revealed the characteristic green-colored colony suggestive of *Aspergillus flavus* [Figure 2]. Slide culture revealed septate branching mycelium, conidiophore, phialide and conidia of *Aspergillus flavus* [Figure 3]. Fruiting bodies of *Aspergillus flavus* are similar to *Syncephalastrum*



**Figure 1: Proximal subungual onychomycosis involving the left great toe in a human immunodeficiency virus-positive patient**



**Figure 2: Culture on sabouraud's dextrose agar revealed the characteristic green-colored colony of *Aspergillus flavus***



**Figure 3: Slide culture revealed septate branching mycelium, conidiophore, phialide and conidia of *Aspergillus flavus***

*racemosum*, but *Syncephalastrum racemosum* has aseptate hyphae and a merosporangial sac surrounding the sporangiospores. KOH examination of the curdy-white plaque from the dorsum of the tongue revealed budding yeast-like cells with pseudohyphae. The final diagnosis was peripheral neuropathy with seborrhoeic dermatitis, oral candidiasis and PSO due to *Aspergillus flavus* of the left great toe in an HIV-positive patient.

Nondermatophyte moulds (NDM) were the rare cause of onychomycosis. Tosti *et al.* in their study found that PSO was the most common type of onychomycosis caused by NDM and that those cases were not associated with significant systemic illness or immunosuppression.<sup>[5]</sup> Goettmann-Bonvallot, in his article, reported that PSO without fingernail or toenail paronychia is generally caused by *Trichophyton rubrum* in immunodepressed subjects (patients with acquired immunodeficiency syndrome).<sup>[6]</sup> Recently published

reports from India revealed increased incidence of NDM causing onychomycosis in HIV-infected patients.<sup>[7]</sup> Several authors have reported cases of onychomycosis due to *Aspergillus* species. To the best of our knowledge, there are only few reports of *Aspergillus flavus* (green mould) causing onychomycosis.<sup>[8-10]</sup> In our case, *Aspergillus flavus* species was the pathogen and not a contaminant as (1) KOH examination of nail scrapings revealed a septate branching mycelium, (2) three repeated cultures performed on Sabouraud's dextrose agar with chloramphenicol revealed characteristic morphology and color suggestive of *Aspergillus flavus* and (3) slide culture findings were suggestive of *Aspergillus flavus* only.

PSO is more frequently seen when the CD4 cell count falls below 450 cells/mm<sup>3</sup>.<sup>[11,12]</sup> But we did not have follow-up of the patient and CD4 cell counts. Usually, periungual inflammation is seen in onychomycosis (especially PSO) caused by *Aspergillus* species.<sup>[5]</sup> But in our case no periungual inflammation was seen. So far, we know that onychomycosis caused by *Aspergillus flavus* species is a rare finding. To the best of our knowledge, there are only few reports in the international literature and not a single one from India.

#### ACKNOWLEDGMENT

The authors would like to acknowledge Dr. Priyesh Jaiswal, 3<sup>rd</sup> year MD resident of Medicine of Jawaharlal Nehru Medical College, Sawangi.

**Sanjiv V. Choudhary, Sankha Koley,  
Sanjay Mallick<sup>1</sup>, Seema Bose<sup>1</sup>, Silpi Basak<sup>1</sup>**

Departments of Dermatology and <sup>1</sup>Microbiology, Jawaharlal Nehru Medical College, Sawangi, Maharashtra, India

**Address for correspondence:** Dr. Sanjiv V. Choudhary,  
28, Modern Nagpur Society, Chhatrapati Nagar,  
Nagpur - 15 (M.S), India  
E-mail: Sanjiv\_choudhary26@yahoo.com

**DOI:** 10.4103/0378-6323.53152 -

## REFERENCES

1. Prose NS, Abson KG, Scher RK. Disorders of the nails and hair associated with human immunodeficiency virus infection. *Int J Dermatol* 1992;31:453-7.
2. Sehgal VN, Join S. Onychomycosis- clinical perspective. *Int J Dermatol* 2000;39:241-9.
3. Cribier B, Mena ML, Rey D, Partisani M, Fabien V, Lang JM, *et al.* Nail changes in patients infected with human immunodeficiency virus. A prospective controlled study. *Arch Dermatol* 1998;134:1216-20.
4. Midgley G, Moore MK, Cook C, Phan QG. Mycology of nail disorders. *J Am Acad Dermatol* 1994;31:S68-74.
5. Tosti A, Piraccini BM, Lorenzi S. Onychomycosis caused by nondermatophytic molds: Clinical features and response to treatment of 59 cases. *J Am Acad Dermatol* 2000;42:217-24.
6. Goettmann-Bonvallot S. Clinical types of onychomycosis. *Ann Dermatol Venereol* 2003;130:1237-43.
7. Surjushe A, Kamath R, Oberai C, Saple D, Thakre M, Dharmshale S, *et al.* A clinical and mycological study of onychomycosis in HIV infection. *Indian J Dermatol Venereol Leprol* 2007;73:397-401.
8. Gianni C, Romano C. Clinical and histological aspects of toenail onychomycosis caused by *Aspergillus* spp. *Dermatology* 2004;209:104-10.
9. Mahmoudabadi AZ, Zarrin M. Onychomycosis with *Aspergillus flavus*: A case report from Iran. *Pak J Med Sci* 2005;21:497-8.
10. Hilimoglu-Polat S, Metin DY, Inci R, Dereli T, Kilinc I, Tumbay E. Nondermatophyte molds as agents of onychomycosis in Turkey: A prospective study. *Mycopathologica* 2005;160:125-8.
11. Kaplan MH, Sadick N, McNutt NS, Meltzer M, Sarngadharan MG, Pahwa S. Dermatologic findings and manifestations of AIDS. *J Am Acad Dermatol* 1987;16:485-506.
12. Conant MA. The AIDS epidemic. *J Am Acad Dermatol* 1994;31:47-50.