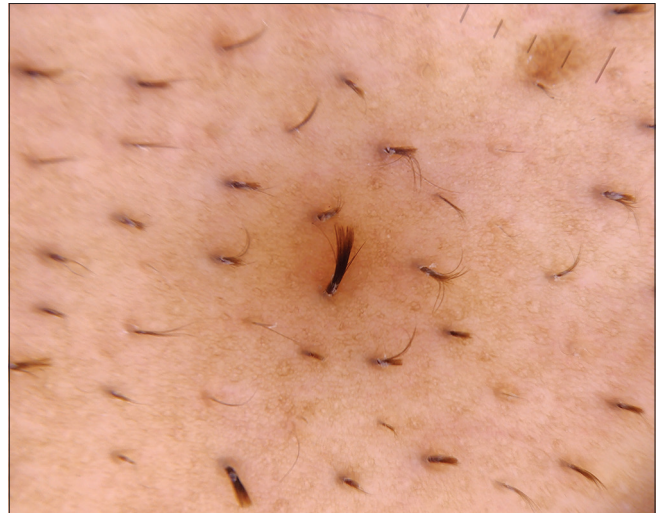


## Pili multigemini



**Figure 1:** Close-up view highlighting the sharp stubby hair over interscapular region



**Figure 2:** Trichoscopy (Illuco IDS-1100, Korea;  $\times 10$ , polarized mode) revealing multiple short terminal hair emerging from a single hair canal

A 42-year-old male presented with complaints of persistent itching over back, of 3 years duration. Examination revealed an area of thick, short, prominent terminal hair over the interscapular region [Figure 1]. Trichoscopy revealed multiple easily extractable short hair of different lengths, emerging from a single hair canal, and enclosed in a common outer sheath [Figure 2]. Histological examination showed multiple hair shafts emerging from a single infundibulum, enclosed in a common outer root sheath and separated from each other by layers of inner root sheath. A diagnosis of pili multigemini was made. Treatment options include laser hair removal and electrolysis.

### Declaration of patient consent

The authors certify that they have obtained all appropriate patient consent forms. In the form, the patient has given his consent for his images and other clinical information to be reported in the journal. The patient understands that name and initials will not be published and due efforts will be made to conceal identity, but anonymity cannot be guaranteed.

### Financial support and sponsorship

Nil.

### Conflicts of interest

There are no conflicts of interest.

**Eeshaan Ranjan, Sandeep Arora, Raka Maitra<sup>1</sup>**

Departments of Dermatology and <sup>1</sup>Pathology, Command Hospital Air Force, Bengaluru, Karnataka, India

### Corresponding author:

Dr. Sandeep Arora,  
Skin Department, Command Hospital Air Force, Bengaluru, Karnataka, India.  
aroraderma@gmail.com

**How to cite this article:** Ranjan E, Arora S, Maitra R. Pili multigemini. Indian J Dermatol Venereol Leprol 2021;87:379.

Received: March, 2019 Accepted: August, 2019 Published: April, 2021

DOI: 10.4103/ijdv.IJDVL\_139\_19 PMID: 31857519

This is an open-access article distributed under the terms of the Creative Commons Attribution-Non Commercial-Share Alike 4.0 License, which allows others to remix, tweak, and build upon the work non-commercially, as long as the author is credited and the new creations are licensed under the identical terms.