

Successful treatment of capillary malformation with foam sclerotherapy

Problem

Capillary malformations are successfully treated with pulse dye laser (PDL). But as it is very expensive, most dermatology clinics/ institutes don't have it. PDL is out of reach for patients due to high cost per session and multiple sessions are generally required to treat vascular lesions. As a result, majority of the patients have to spend rest of their lives coping with psychological stress and cosmetic anxiety.

Solution

To overcome this difficulty, we used a 3% polidocanol foam formulation as a sclerosing agent for the treatment of capillary malformation [Figure 1]. Polidocanol (synthetic detergent-like substance) disrupts endothelial vessels, causing clotting and inflammation, resulting in closure. It is efficacious, safe, and cost-effective. The preparation involved combining 2 mL of 3% polidocanol with air and 6 mL of sterile water using a 3-way cannula and a 10 mL syringe. The resulting solution was transferred into a 1 mL insulin syringe and intradermally

injected into the anaesthetised (2% lignocaine cream for 45 minutes) capillary malformation. After injecting 0.3 mL of the solution, the erythema blanches with an approximate size of 1–2 cm², indicative of successful sclerosing of capillary vessels [Video 1]. Subsequently, injections were administered at 1–2 cm² intervals, totaling 4–6 mL of solution per session. Sessions were repeated every four weeks for three sessions, with no recurrence observed at two months follow-up post-treatment. The advantages of using 3% polidocanol as a sclerosing agent include its readily availability, cost-effectiveness, and ease of administration with minimal side effects. There was a low risk of scarring, edema, pain, ulceration, thrombosis, and transient blindness with this modest dose of injection compared to the higher dose used in varicose vein treatment.^{1,2} With its innovative technique of sclerotherapy coupled with its low cost, simplicity, and safety profile, it can yield results comparable to those of a laser [Figure 2, Video 1].

Video 1: "Demonstration of intralesional 3% polidocanol".

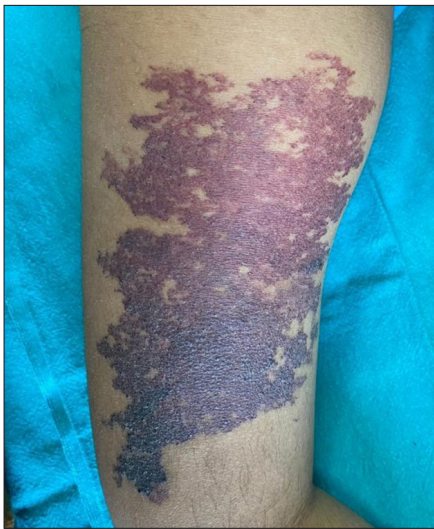

Figure 1: Capillary malformation over right overgrowth arm.

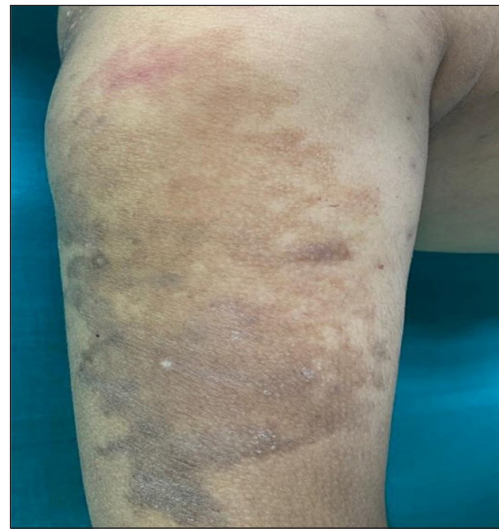


Figure 2: Hyperpigmentation after three sessions of foam sclerotherapy at a monthly interval.

How to cite this article: Paul D, Snehal A, Singh S. Successful treatment of capillary malformation with foam sclerotherapy. *Indian J Dermatol Venereol Leprol*. doi: 10.25259/IJDVL_170_2024

Received: February, 2024 **Accepted:** May, 2024 **Epub Ahead of Print:** July, 2024

DOI: 10.25259/IJDVL_170_2024 **Video available on:** https://doi.org/10.25259/IJDVL_170_2024

This is an open-access article distributed under the terms of the Creative Commons Attribution-Non Commercial-Share Alike 4.0 License, which allows others to remix, tweak, and build upon the work non-commercially, as long as the author is credited and the new creations are licensed under the identical terms.

Declaration of patient consent

The authors certify that they have obtained all appropriate patient consent.

Financial support and sponsorship

Nil.

Conflicts of interest

There are no conflicts of interest.

Use of artificial intelligence (AI)-assisted technology for manuscript preparation

The authors confirm that there was no use of artificial intelligence (AI)-assisted technology for assisting in the writing or editing of the manuscript and no images were manipulated using AI.

Debopriya Paul, Aditi Snehal, Suvesh Singh

Department of Dermatology and Venereology,
All India Institute of Medical Sciences, Patna.

Corresponding author:

Dr. Suvesh Singh,
Senior resident, Department of Dermatology and Venereology,
All India Institute of Medical Sciences, Patna.
suveshsingh2658@gmail.com

Reference

1. Mishra M, Singh G, Gaur A, Tandon S, Singh A. Role of sclerotherapy in management of vascular malformation in the maxillofacial region: Our experience. *Natl J Maxillofac Surg* 2017;8:64–9.
2. Li N, Li J, Huang M, Zhang X. Efficacy and safety of polidocanol in the treatment of varicose veins of lower extremities: A protocol for systematic review and meta-analysis. *Medicine (Baltimore)* 2021;100:e24500.