

CREEPING ERUPTION ON GLANS PENIS

K Pavithran and P Ramachandran Nair

A young male having a creeping eruption on the glans penis is reported.

Key words : Creeping eruption, Larva migrans, Glans penis.

Creeping eruption (larva migrans) is a condition in which the filariform larvae of certain nematodes wander about through the skin in an aimless manner producing a burrow along the path traversed by them. Common larvae that produce creeping eruption are those of *Ancylostoma braziliensis*, *Ancylostoma caninum* and *Uncinaria stenocephala*.¹ The areas most commonly affected are the buttocks, feet and trunk.^{1,2} The mucous membranes of the vulva and anus are not usually affected.¹ We are reporting a case of larva migrans on the glans penis of a young male. Excellent therapeutic response was observed after a course of oral thiabendazole.

Case Report

A 30-year-old male was seen for an itchy linear eruption on his glans penis since two weeks. It started as a red papule on the glans penis from which a linear, cord-like lesion progressed. Four days prior to the onset of the skin lesion, he had drunk alcohol and slept on the soil in a rubber garden throughout the night, wearing only a short underwear made of thin cotton cloth. He denied history of sexual exposure, though recently, he had received one injection of 2.4 mega units of benzathine penicillin, from a local hospital since the blood VDRL test was reported to be 1:16 positive. In spite of this treatment, the genital lesion progressed. Examination

revealed a linear and curved erythematous track 0.25 mm wide, on the glans penis (Fig. 1).

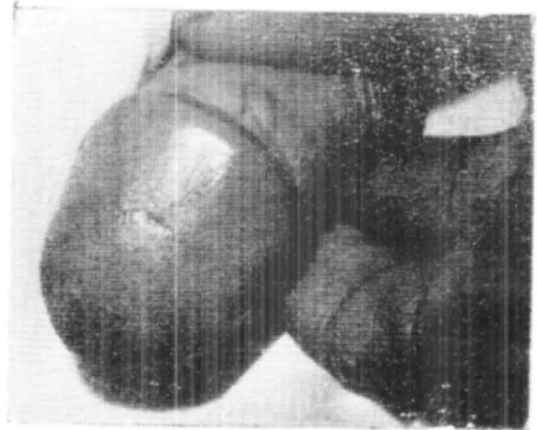


Fig. 1. Creeping eruption on glans penis.

The track advanced at the rate of 2 to 3 cm per day. As the tunnel advanced on one end, the opposite end became scaly and crusted. There was no other skin lesion. General physical and systemic examination did not reveal any abnormality.

Routine laboratory investigations on blood, urine and stools were normal. Blood VDRL was non-reactive on three occasions. Thiabendazole 500 mg tablets, giving 2 tablets twice a day for 3 days led to complete subsidence of the lesion in 7 days.

Comments

Occurrence of larva migrans on the glans penis is quite rare, though a similar case had been reported from Trivandrum.³ A person

From the Department of Skin and VD, Medical College, Kottayam-686008, India.

Address correspondence to: Dr. K. Pavithran.

lying on a contaminated beach in a bathing towel is just as easily affected as those with bare skin in contact with the ground.² The diagnosis of a case of larva migrans is easy when the clinician is familiar with the condition. But when it occurs on the genitalia, the diagnosis can be missed.

References

1. Canizare O : Clinical Tropical Dermatology, Blackwell Scientific Publications, London, 1975; p 229.
2. Leeming JAL and Loewenthal LJA : Cutaneous larva migrans, in : Essays on Tropical Dermatology, editors, Simons RDJ and Marshal J, Excerpta Medica Foundation, Amsterdam, 1969; p 169.
3. Pavithran K : Larva migrans on the glans penis, Ind J Dermatol Venereol Leprol, 1982; 48 : 237-238.