

Interdigital, tendon, and gluteal xanthomas in familial hypercholesterolemia

A 21-year-old male presented with multiple asymptomatic yellowish-brown papules, plaques, and nodules over web spaces, proximal interphalangeal joints, and metacarpophalangeal joints of both hands [Figure 1a], elbows [Figure 1b], and gluteal region [Figure 1c] since the age of six years. His father had died of myocardial infarction at 39 years and his paternal uncle aged 34 years was on treatment for coronary artery disease. Investigations

revealed elevated total cholesterol (723 mg/dl) and low-density lipoprotein (LDL) cholesterol (602 mg/dl). Heart echocardiography was normal. Genetic studies showed a missense mutation in the LDL-receptor gene (c.2054C>T). He was diagnosed as familial hypercholesterolemia and started on pravastatin and counselled regarding lifestyle modifications. Follow-up at the sixth month revealed persistence of xanthomas and normal cholesterol levels.

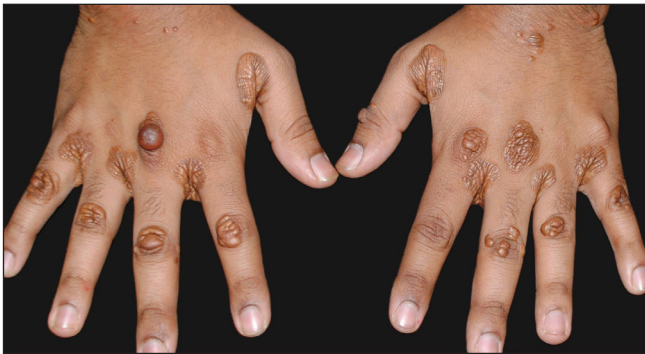


Figure 1a: Interdigital and tendon xanthomas over both the hands.

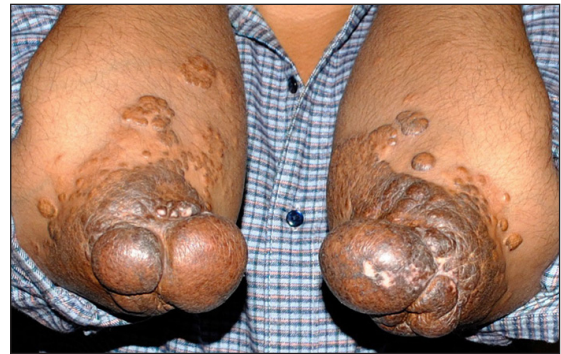

Figure 1b: Tendon xanthomas over the elbows.

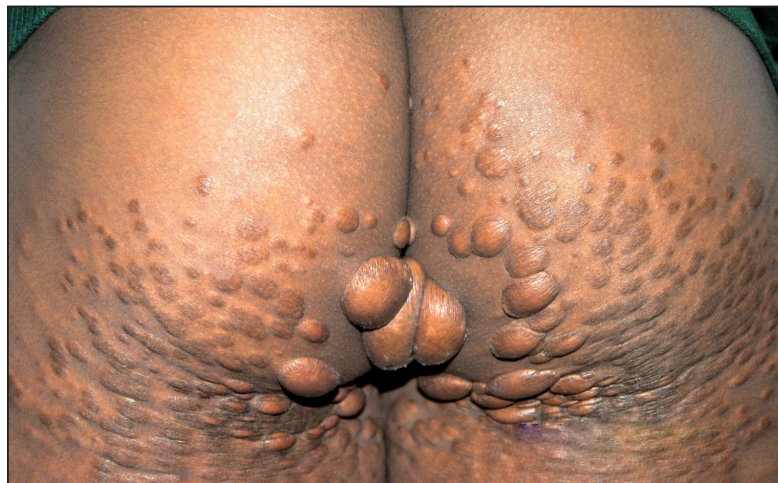

Figure 1c: Gluteal xanthomas.

How to cite this article: Kothari R, Khare S. Interdigital, tendon, and gluteal xanthomas in familial hypercholesterolemia. *Indian J Dermatol Venereol Leprol*. doi: 10.25259/IJDVL_521_2024

Received: April, 2024 **Accepted:** April, 2024 **Epub Ahead of Print:** July, 2024

DOI: 10.25259/IJDVL_521_2024

This is an open-access article distributed under the terms of the Creative Commons Attribution-Non Commercial-Share Alike 4.0 License, which allows others to remix, tweak, and build upon the work non-commercially, as long as the author is credited and the new creations are licensed under the identical terms.

Declaration of patient consent

The authors certify that they have obtained all appropriate patient consent.

Financial support and sponsorship

Nil.

Conflicts of interest

There are no conflicts of interest.

Use of artificial intelligence (AI)-assisted technology for manuscript preparation

The authors confirm that there was no use of AI-assisted technology for assisting in the writing or editing of

the manuscript and no images were manipulated using AI.

Rohit Kothari, Sanjay Khare¹

Department of Dermatology, 12 Air Force Hospital, Gorakhpur, India,
¹Department of Dermatology, Mahatma Gandhi Memorial Medical College,
Indore, Madhya Pradesh, India.

Corresponding author:

Dr. Rohit Kothari,
Department of Dermatology, 12 Air Force Hospital,
Gorakhpur, India.
rohitkothari3422@gmail.com