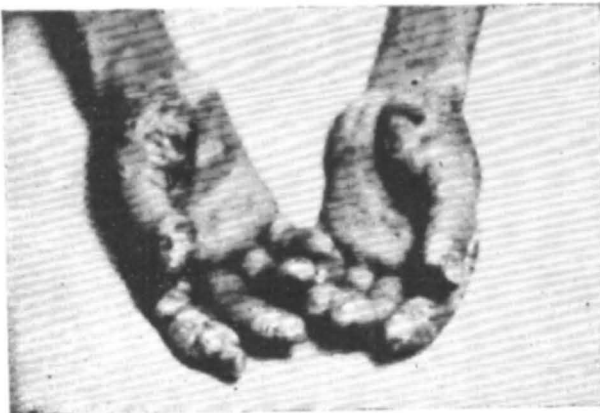
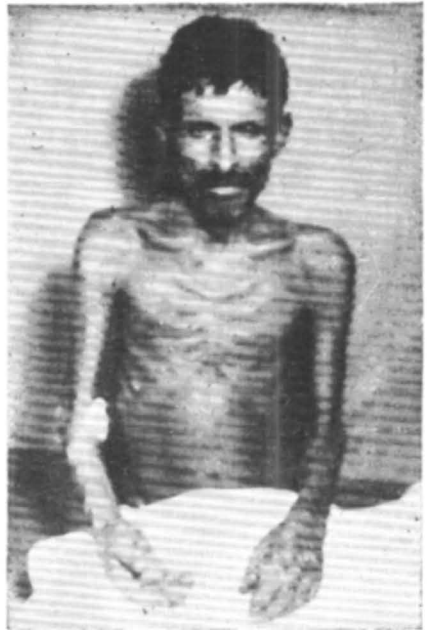
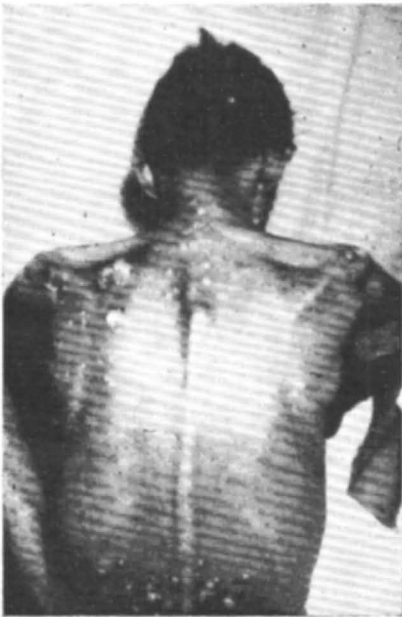WHAT IS YOUR DIAGNOSIS ?

Fifty-one year old male patient was admitted with complaints of swelling of the abdomen and fever for 3 months and nodular eruptions on the skin for 10 days.

On examination, patient was sick looking, pale and febrile with bilateral pedal edema. Both eyes showed small yellowish nodules at the limbus. Liver was palpable 3 cm below right costal margin and spleen 14 cm below left costal margin. Large matted lymph glands were palpable on the right side of the neck. Skin showed multiple nodules and plaques all over the body. Nodules were firm, ulcerating or necrotic.

Investigations at time of admission showed Hb. 7 Gm% ; total WBC of 4,200 cmm showing Blasts 1, Neut. 47, Basophils 8, Lymph. 5 and myelocytes 15 ; E. S. R. 141 mm. Hg. at end of 1st hour.



Differential Diagnosis :

1. Chronic myeloid leukemia with leukemic infiltration in the skin
2. Mycosis fungoides
3. Disseminated Tuberculosis with myelofibrosis.

(Answer Page No. 108)

DARIER'S DISEASE—B. S. N. Reddy, Gurmohan Singh

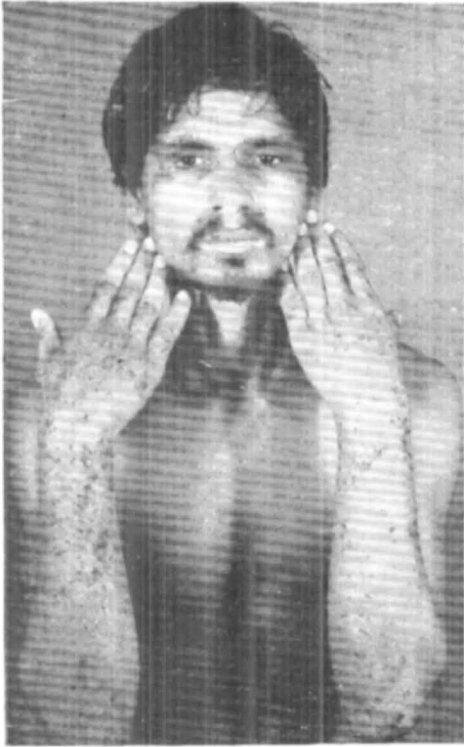


Fig. 1 Darier's disease. Note the characteristic lesions on the periorbital areas, nasolabial folds and upper extremities.

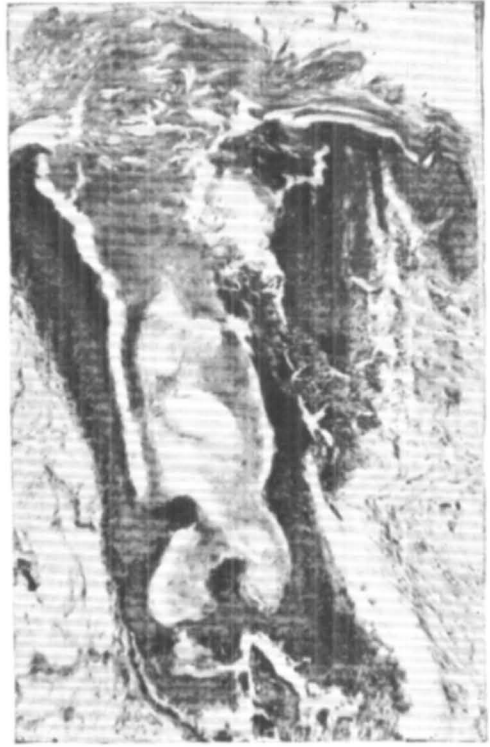

Fig. 3 Histology of Darier's disease showing hyperkeratosis, follicular plugging, acanthosis, suprabasal splitting and multiple corps ronds and grains.

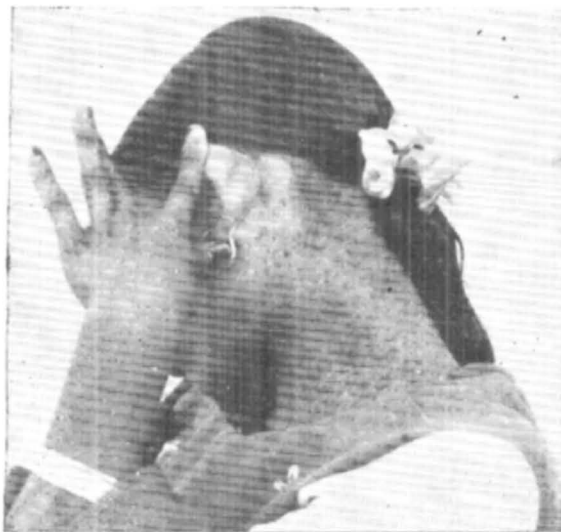

Fig. 2 Darier's disease. The lesions are seen over the retroauricular areas and side of the neck.