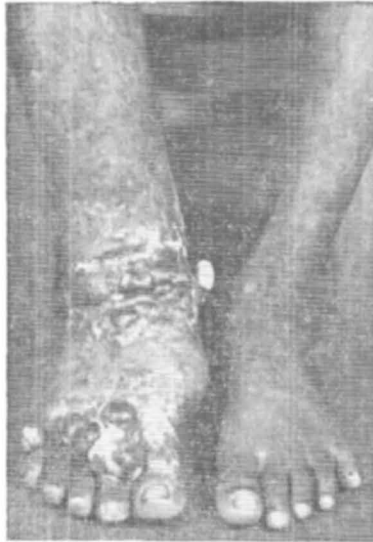

## SPOT THE DIAGNOSIS ?



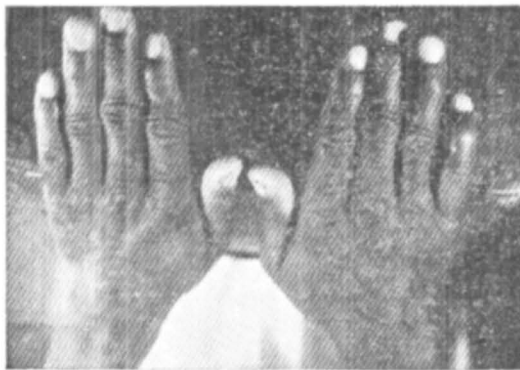
(With the courtesy of Dr. A. P. S. Prakash,  
Bhagalpur)

Final diagnosis - Mycetozoa

---

## SYMMETRICAL PROGRESSIVE ERYTHROKERATODERMA

— T. R. Kapur et al



**Fig. 1** Symmetrical well defined erythrokeratodermic plaques on the dorsa of hands and forearms.