

# Indian Journal of Dermatology, Venereology & Leprology

Journal indexed with SCI-E, PubMed, and EMBASE

Vol 74 | Issue 2 | Mar-Apr 2008

C O N T E N T S

## EDITORIAL

### Management of autoimmune urticaria

Arun C. Inamadar, Aparna Palit ..... 89

## VIEW POINT

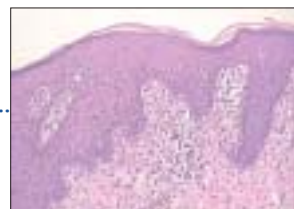### Cosmetic dermatology versus cosmetology: A misnomer in need of urgent correction

Shyam B. Verma, Zoe D. Draelos ..... 92

## REVIEW ARTICLE

### Psoriasiform dermatoses

Virendra N. Sehgal, Sunil Dogra, Govind Srivastava, Ashok K. Aggarwal ..... 94



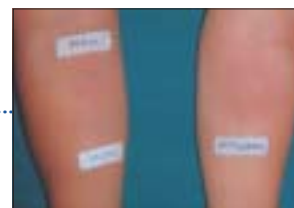## ORIGINAL ARTICLES

### A study of allergen-specific IgE antibodies in Indian patients of atopic dermatitis

V. K. Somani ..... 100

### Chronic idiopathic urticaria: Comparison of clinical features with positive autologous serum skin test

George Mamatha, C. Balachandran, Prabhu Smitha ..... 105



### Autologous serum therapy in chronic urticaria: Old wine in a new bottle

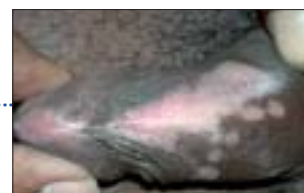A. K. Bajaj, Abir Saraswat, Amitabh Upadhyay, Rajetha Damisetty, Sandipan Dhar ..... 109

### Use of patch testing for identifying allergen causing chronic urticaria

Ashimav Deb Sharma ..... 114

### Vitiligoid lichen sclerosus: A reappraisal

Venkat Ratnam Attali, Sasi Kiran Attali ..... 118



**BRIEF REPORTS**

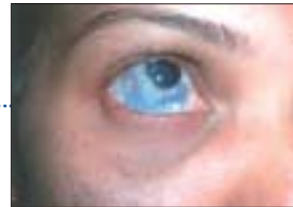**Activated charcoal and baking soda to reduce odor associated with extensive blistering disorders**

Arun Chakravarthi, C. R. Srinivas, Anil C. Mathew ..... 122



**Nevus of Ota: A series of 15 cases**

Shanmuga Sekar, Maria Kuruvila, Harsha S. Pai ..... 125



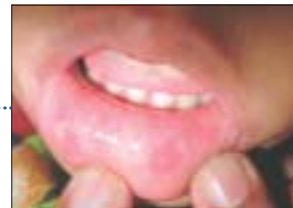**Premature ovarian failure due to cyclophosphamide: A report of four cases in dermatology practice**

Vikrant A. Saoji ..... 128

**CASE REPORTS**

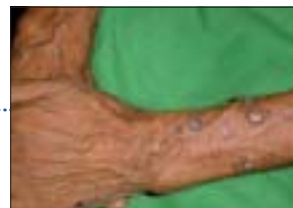**Hand, foot and mouth disease in Nagpur**

Vikrant A. Saoji ..... 133



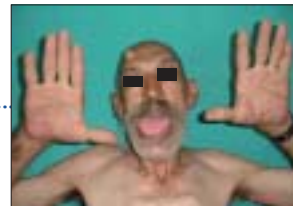**Non-familial multiple keratoacanthomas in a 70 year-old long-term non-progressor HIV-seropositive man**

Hemanta Kumar Kar, Sunil T. Sabhnani, R. K. Gautam, P. K. Sharma, Kalpana Solanki, Meenakshi Bhardwaj ..... 136



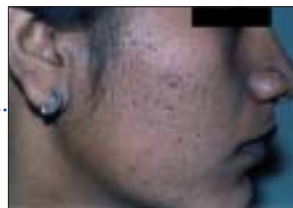**Late onset isotretinoin resistant acne conglobata in a patient with acromegaly**

Kapil Jain, V. K. Jain, Kamal Aggarwal, Anu Bansal ..... 139



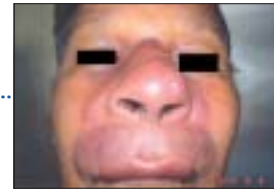**Familial dyskeratotic comedones**

M. Sendhil Kumaran, Divya Appachu, Elizabeth Jayaseelan ..... 142



**Nasal NK/T cell lymphoma presenting as a lethal midline granuloma**

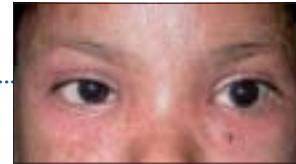Vandana Mehta, C. Balachandran, Sudha Bhat, V. Geetha, Donald Fernandes .....



145

**Childhood sclerodermatomyositis with generalized morphea**

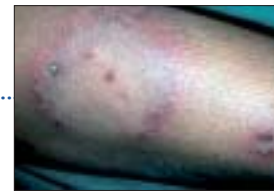Girishkumar R. Ambade, Rachita S. Dhurat, Nitin Lade, Hemangi R. Jerajani.....



148

**Subcutaneous panniculitis-like T-cell cutaneous lymphoma**

Avninder Singh, Joginder Kumar, Sujala Kapur, V. Ramesh.....



151

**LETTERS TO EDITOR**

**Using a submersible pump to clean large areas of the body with antiseptics**

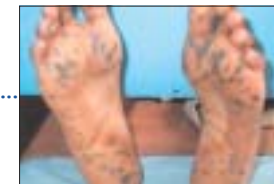C. R. Srinivas .....



154

**Peutz-Jeghers syndrome with prominent palmoplantar pigmentation**

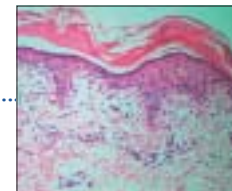
K. N. Shivaswamy, A. L. Shyamprasad, T. K. Sumathi, C. Ranganathan .....



154

**Stratum corneum findings as clues to histological diagnosis of pityriasis lichenoides chronica**

Rajiv Joshi .....



156

**Author's reply**

S. Pradeep Nair .....

157

**Omalizumab in severe chronic urticaria**

K. V. Godse.....

157

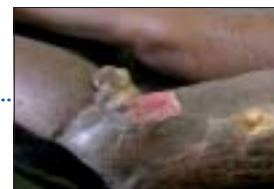**Hypothesis: The potential utility of topical eflornithine against cutaneous leishmaniasis**

M. R. Namazi .....

158

**Nodular melanoma in a skin graft site scar**

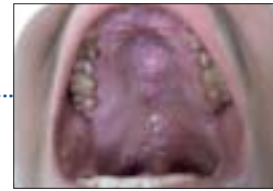A. Gnaneshwar Rao, Kamal K. Jhamnani, Chandana Konda .....



159

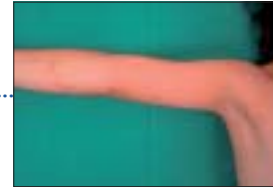**Palatal involvement in lepromatous leprosy**

A. Gnaneshwar Rao, Chandana Konda, Kamal Jhamnani..... 161



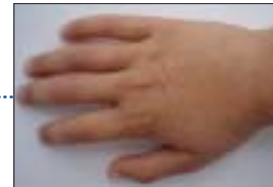**Unilateral nevoid telangiectasia with no estrogen and progesterone receptors in a pediatric patient**

F. Sule Afsar, Ragip Ortac, Gulden Diniz ..... 163



**Eruptive lichen planus in a child with celiac disease**

Dipankar De, Amrinder J. Kanwar..... 164

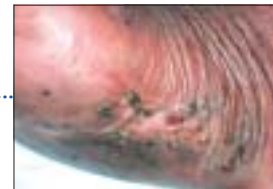

**Xerosis and pityriasis alba-like changes associated with zonisamide**

Feroze Kaliyadan, Jayasree Manoj, S. Venkitakrishnan..... 165

**Treatment of actinomycetoma with combination of rifampicin and co-trimoxazole**

Rajiv Joshi ..... 166



**Author's reply**

M. Ramam, Radhakrishna Bhat, Taru Garg, Vinod K. Sharma, R. Ray, M. K. Singh, U. Banerjee, C. Rajendran ..... 168

**Vitiligo, psoriasis and imiquimod: Fitting all into the same pathway**

Bell Raj Eapen ..... 169

**Author's reply**

Engin Şenel, Deniz Seçkin ..... 169

**Multiple dermatofibromas on face treated with carbon dioxide laser: The importance of laser parameters**

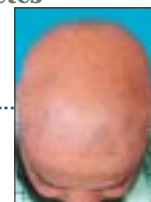Kabir Sardana, Vijay K. Garg ..... 170

**Author's reply**

D. S. Krupa Shankar, A. Kushalappa, K. S. Uma, Anjay A. Pai..... 170

**Alopecia areata progressing to totalis/universalis in non-insulin dependent diabetes mellitus (type II): Failure of dexamethasone-cyclophosphamide pulse therapy**

Virendra N. Sehgal, Sambit N. Bhattacharya, Sonal Sharma, Govind Srivastava, Ashok K. Aggarwal ..... 171



**Subungual exostosis**

Kamal Aggarwal, Sanjeev Gupta, Vijay Kumar Jain, Amit Mital, Sunita Gupta..... 173

**Clinicohistopathological correlation of leprosy**

Amrish N. Pandya, Hemali J. Tailor ..... 174

**RESIDENT'S PAGE**

**Dermatographism**

Dipti Bhute, Bhavana Doshi, Sushil Pande, Sunanda Mahajan, Vidya Kharkar ..... 177

**FOCUS**

**Mycophenolate mofetil**

Amar Surjushe, D. G. Saple ..... 180

**QUIZ**

**Multiple papules on the vulva**

G. Raghu Rama Rao, R. Radha Rani, A. Amareswar, P. V. Krishnam  
Raju, P. Raja Kumari, Y. Hari Kishan Kumar ..... 185



**E-IDVL**

**Net Study**

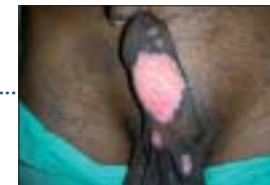**Oral isotretinoin is as effective as a combination of oral isotretinoin and topical anti-acne agents in nodulocystic acne**

Rajeev Dhir, Neetu P. Gehi, Reetu Agarwal, Yuvraj E. More ..... 187

**Net Case**

**Cutaneous diphtheria masquerading as a sexually transmitted disease**

T. P. Vetrichevvel, Gajanan A. Pise, Kishan Kumar Agrawal,  
Devinder Mohan Thappa ..... 187



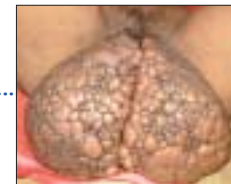**Net Letters**

**Patch test in Behcet's disease**

Ülker Gül, Müzeyyen Gönül, Seray Külcü Çakmak, Arzu Kılıç ..... 187

**Cerebriform elephantiasis of the vulva following tuberculous lymphadenitis**

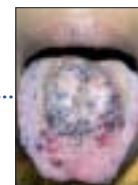Surajit Nayak, Basanti Acharjya, Basanti Devi, Satyadarshi Pattnaik,  
Manoj Kumar Patra ..... 188



**Net Quiz**

**Vesicles on the tongue**

Saurabh Agarwal, Krishna Gopal, Binay Kumar ..... 188

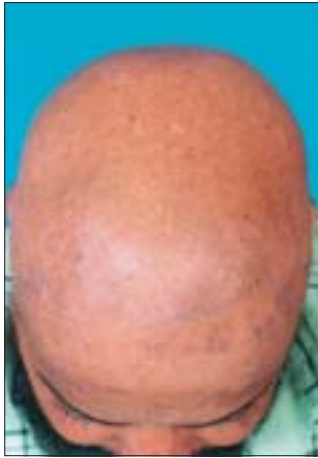

## **Alopecia areata progressing to totalis/universalis in non-insulin dependent diabetes mellitus (type II): Failure of dexamethasone-cyclophosphamide pulse therapy**

Sir,

The development of alopecia areata (AA) progressing to totalis/universalis in well-established non-insulin-dependent diabetes mellitus (NIDDM, type II) is an exclusive phenomenon, an indirect circumstantial evidence favoring it as an autoimmune disease. Dexamethasone-cyclophosphamide pulse was initiated but failed to produce a response.

A 47-year-old man, apparently well until a year ago had a few recalcitrant multiple boils on the nape of the neck. His fasting and postprandial blood sugar levels were markedly elevated pointing to a diagnosis of NIDDM, for which oral anti-diabetics (metformin 500 mg + glipizide 5 mg), along with dietary advice and appropriate oral and topical antibiotics were started. The preceding treatment ensured complete healing of the boils within 2 weeks. Four months



**Figure 1: Alopecia areata progressing to totalis/universalis: Complete loss of hair over the scalp**

later, he experienced spontaneous loss of hair over the legs progressing to involve other sites. In a short period of time, hair loss was noticed over the trunk, scalp and the beard area. It was accompanied by mild to moderate itching. However, hair loss was not preceded by any perifollicular papular or pustular lesions. The loss of hair over the scalp was total and was a source of embarrassment, which brought him for consultation. Examination of the skin was marked by loss of hair over the whole of the skin surface of the trunk, upper and lower extremities with patches of hair loss over the beard area. Hair pull test was positive. The complete loss of hair over the scalp was without any evidence of scarring or any skin lesion [Figure 1], which was characteristic of AA. Routine total and differential leukocyte count, complete hemogram and blood biochemical parameters were within normal limits. However, his random blood sugar was 197 mg (normal up to 140) and glycosylated hemoglobin (HbA1c) was 9.6 percent (normal 9%-10% fair glycemic control). The hematoxylin eosin stained biopsy section from the area of hair loss showed dense lymphocytic infiltrate in the dermis involving the receding remnant of hair follicles.

Dexamethasone cyclophosphamide pulse (DCP) therapy was opted for the treatment of extensive AA as it has successfully been used for bullous autoimmune dermatoses,<sup>[1,2]</sup> including pemphigus vulgaris. Moreover, side-effect profile is considered to be less severe with the pulse form than the conventional daily dosing of corticosteroids. It comprised 100 mg of dexamethasone dissolved in 5% dextrose administered intravenously over 3-4 h on three consecutive days plus intravenous 500 mg of cyclophosphamide administered on day 2 only, followed by daily oral 50 mg cyclophosphamide. The effect of administration of dextrose and concomitant

NIDDM was neutralized by simultaneous administration of 16 units of human mono-component regular insulin. About three such doses (cycles) were contemplated at intervals of 1 month each. Besides, he was maintained on oral anti-diabetics comprising metformin and glipizide. The patient was advised to come for follow-up every month till the completion of 1 year. A thorough examination of the scalp and rest of the skin surface was conspicuous by the absence of any hair growth, signaling the failure of dexamethasone-cyclophosphamide pulse therapy.

Alopecia areata is a well-recognized clinical entity characterized by non-scarring round and/or oval patches of hair loss. However, an exclamation mark at the active hair margin is its diagnostic hallmark. The lesions are largely asymptomatic, which may manifest either as alopecia areata (classic, reticulate AA, alopecia totalis/universalis or ophiasis and ophiasis in versa).<sup>[3]</sup>

A number of associations have been reported with diabetes mellitus, including a series of cutaneous disorders like candida endocrinopathy syndrome, lichen planus, lupus erythematosus and vitiligo.<sup>[4]</sup> While AA and vitiligo are markers of auto-immunity in insulin-dependent diabetes mellitus (Type I),<sup>[5-7]</sup> the association of AA and NIDDM type II is extraordinary and hitherto has never been emphasized.

Most effective therapies for AA have immunosuppression as a common denominator. However, the failure of DCP pulse therapy in our patient supports equivocal outcome reported following prednisolone as a single 2 g dose intravenously (i.v.)/0.5 g daily for 5 days orally.<sup>[8]</sup> Nonetheless, the proposed role of DCP as a treatment option in the management of AA per se or in association with other auto-immune disease needs to be evaluated in a larger number of patients. This is particularly because its efficacy in auto-immune diseases like systemic sclerosis/scleroderma,<sup>[9-11]</sup> paraneoplastic pemphigus<sup>[12]</sup> and discoid lupus erythematosus<sup>[13]</sup> was admirably established.

**Virendra N. Sehgal, Sambit N. Bhattacharya,  
Sonal Sharma, Govind Srivastava,  
Ashok K. Aggarwal**

Dermato-Venereology (Skin/VD) Centre, Sehgal Nursing Home, Panchwati, Azadpur, Delhi, Departments of Dermatology, STD and Pathology, University College of Medical Sciences and Associated Guru Teg Bahadur Hospital Delhi; Skin Institute and School of Dermatology, Greater Kailash, New Delhi, India

**Address for correspondence:** Prof. Virendra N. Sehgal, Sehgal Nursing Home, A/6, Panchwati, Azadpur, Delhi - 110 033. India.  
E-mail: drsehgal@ndf.vsnl.net.in

## REFERENCES

1. Raman M. Dexamethasone pulse therapy in dermatology. *Indian J Dermatol Venereol Leprol* 2003;69:319-22.
2. Appelhans M, Monsmann G, Orge, Brocker EB. Dexamethasone-cyclophosphamide pulse therapy in bullous autoimmune dermatoses. *Hautarzt* 1993;44:143-7.
3. Sehgal VN, Srivastava G, Aggarwal AK, Sethi G, Adhikari T. Alopecia areata in the Indian subcontinent. *Skinmed* 2007;6:63-9
4. Sehgal VN, Jain S. Alopecia areata: Clinical perspective and an insight into pathogenesis. *J Dermatol (Tokyo)* 2003;30:271-89.
5. Sipetic S, Vlajinac H, Kocev N, Marinkovic J, Radmanovic S, Denic L. Family history and risk of type 1 diabetes mellitus. *Acta Diabetol* 2002;39:111-5.
6. Flagothier C, Quatresooz P, Bourguignon R, Pierard-Franchimont C, Pierard GE. CHR hutois: Cutaneous stigmata of diabetes mellitus. *Rev Med Liege* 2005;60:553-9.
7. Wong J, Shohat T, Vadheim C, Shellow W, Edwards J, Rotter JI. Increased risk of type-I (insulin dependent) diabetes in relatives of patients with alopecia areata. *Am J Med Genet* 1994;51:234.
8. Burton JL, Shuster S. Large doses of glucocorticoid in the treatment of alopecia areata. *Acta Derm Venereol* 1975;55:493-6.
9. Sharda B, Kumar A, Kakkar R, Adya CM, Pande I, Uppal SS, *et al.* Intervavenous dexamethasone pulse therapy in diffuse systemic sclerosis: A randomized placebo-controlled study. *Rheumatol Internal* 1994;14:91-4.
10. Pai BS, Srinivas CR, Sabitha L, Shenoi SD, Balachandran CN, Acharya S. Efficacy of dexamethasone pulse therapy in progressive systemic sclerosis. *Int J Dermatol* 1995;34:726-8.
11. Vatwani V, Palta SC, Verma N, Pathak PR, Singh RP. Pulse therapy in scleroderma. *Indian Pediatr* 1994;31:993-5.
12. Becker LR, Bastian BC, Wesselmann U, Karl S, Hamm H, Brocker EB. Paraneoplastic pemphigus treated with dexamethasone / cyclophosphamide pulse therapy. *Eur J Dermatol* 1998;8: 551-3.
13. Singh OP, Vema KK. Discoid lupus erythematosus treated with dexamethasone pulse therapy. *Indian J Dermatol Venereol Leprol* 1991;57:311.