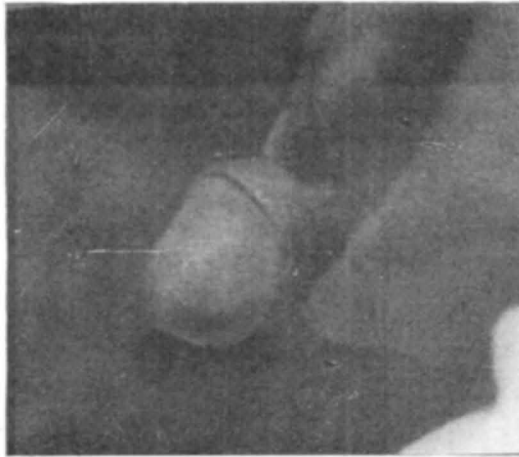


## Short Communication

### Larva migrans on the glans penis

A twenty years old male attended the dermatology department of Medical College, Trivandrum for an itching eruption on his glans penis since one week. History revealed that recently he had been to a Kalari (gymnasium) where he had to lie prone on the ground for massaging the body with oil. Three days following this he noticed an erythematous papule on the glans penis from where interrupted linear erythematous tracks advanced. He denied any history of 'exposure'. On examination there were linear and curved (Fig. 1) erythematous tracks on the glans penis near the external meatus. The tracks advanced at a rate of 1 - 2 cm/day. He was clinically diagnosed as a case of larva migrans. Blood VDRL was non reactive. He was given a course of thiabendazol (Mintezol 500 mg 2 bd x 3 days). Since there was no relief even after 7 days a second course of the drug was given along with direct freezing of the area with ethyl chloride which caused severe pain to the patient. One week later when patient reported for follow up, the tracks were all found completely subsided. Follow up for a further period of 6 months did not show recurrence.



The case is reported since it is quite unusual to see Larva migrans on the glans penis. The areas most affected are those which come in contact with ground - feet, buttocks and trunk<sup>1</sup>. It is possible in the present case that the larva entered the mucosa of the glans penis from the ground during 'massaging'. The freezing of the terminus of the tunnel with ethylchloride spray which is the only treatment that has stood the best of time<sup>2</sup> was effective in our case.

### References

1. Canizare O: Clinical Tropical Dermatology, Blackwell Scientific Publications, London, 1975.