

## H syndrome with histological features of Langerhans cell histiocytosis

Sir,

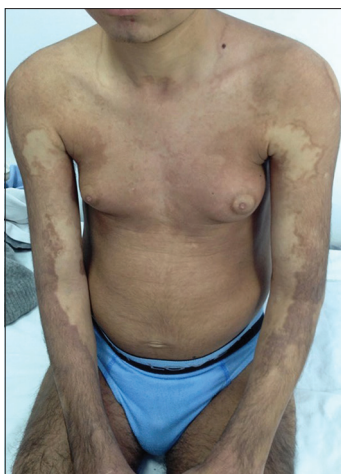
The H syndrome (OMIM 602782) is a very rare autosomal recessive disorder first described by Molho-Pessach in 2008 and refers to a constellation of clinical and laboratory findings.<sup>[1-4]</sup> This disorder has been recently shown to be caused by mutations in the SLC29A3 gene encoding the human equilibrative nucleoside transporter.<sup>[5]</sup> We report a novel case of H syndrome with a particular histological and genetic presentation.

The patient followed up with us since the age of 14 years for progressive sclerodermatous thickening of the skin, with overlying hyperpigmentation and hypertrichosis on the limbs [Figure 1]. In addition, he was followed up in the endocrinology department since the age of 16 years for insulin-dependent diabetes mellitus, short stature and dysmorphic features. The child also had sensorineural hearing loss from the age of 9 years. He was born after a normal pregnancy to non-related parents of Tunisian origin. His brother and two sisters were healthy. On physical examination, we noted bilateral gynecomastia [Figure 1], short stature, hepatosplenomegaly, flexion contractures of the fingers

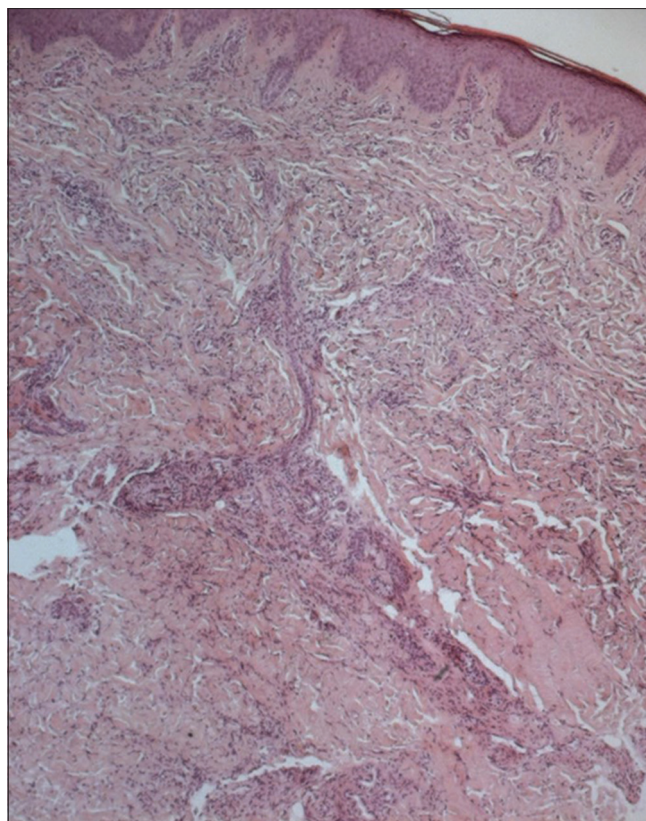
and toes, hallux valgus and a micropenis. Indurated and hyperpigmented patches were present on the middle and lower half of the body, extending over the trunk and neck. He was not found to have cardiovascular or ocular anomalies. Laboratory investigations revealed low rates of insulin growth factor type 1, insulin growth factor binding protein type 3 and testosterone. A growth hormone stimulation test with arginine did not indicate growth hormone deficiency. Thyroid function tests and karyotype were normal.

Histopathological examination of involved skin showed hyperpigmentation of the basal layer with infiltration by histiocytes [Figure 2]. Immunohistochemistry showed positivity with both CD1a and PS100 [Figure 3]. However, CD68 was negative. A perivascular mononuclear infiltrate with plasma cells and mast cells throughout the dermis and subcutaneous fat was noted. Blood samples were collected from the patient and his parents. Informed consent was obtained from each of them. Mutation analysis of genomic DNA confirmed the diagnosis of H syndrome in our patient and showed that he was a compound heterozygote for two types of mutations in exon 6 of the SLC29A3 gene (described below).

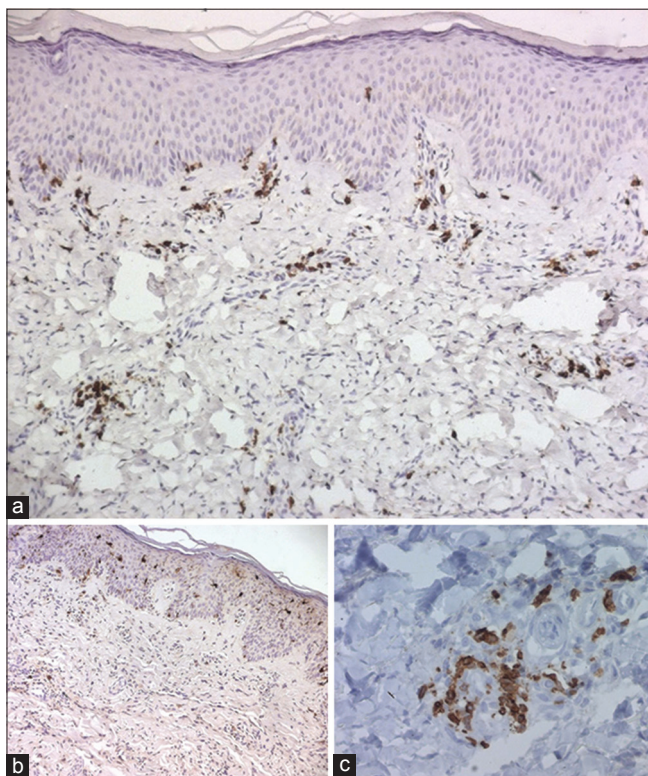
More than a hundred cases of the H syndrome have been reported.<sup>[2]</sup> Major systemic features include hearing loss, heart anomalies, hepatosplenomegaly,



**Figure 1: Extensive hyperpigmentation over upper limbs and thighs, and prominent gynecomastia**



**Figure 2: Marked fibrosis of the dermis and superficial subcutis with chronic perivascular inflammatory infiltrates (H and E, x400)**



**Figure 3: (a) The lymphoid cells are seen to be mostly T cells (CD3+) (b) with histiocytes which are CD1a+ (c) histiocytes are also positive with PS100**

hypogonadism and hyperglycemia. A hallmark of this syndrome is the cutaneous hyperpigmentation which is accompanied by sclerodermatous thickening and hypertrichosis.<sup>[3]</sup> The lower limbs are the most common site described with cutaneous hyperpigmentation. Flexion contractures of the fingers and toes are the second most common feature.<sup>[3]</sup> In a recent study which focuses on the spectrum of radiological findings in the H syndrome, severe symmetrical deformation

was demonstrated.<sup>[6]</sup> Sensorineural hearing loss is the third most common clinical finding. A recent report describes two cases of H syndrome who had hearing loss as a prominent feature.<sup>[7]</sup> Lymphadenopathy has been described as another feature.<sup>[3]</sup> According to a recent review, insulin-dependent diabetes mellitus was observed in 18 (23%) patients, and this may be the sole presentation.<sup>[8]</sup> Micropenis has also been observed.<sup>[3,4]</sup> Further, several other biological anomalies such as hypertriglyceridemia, anemia, red cell aplasia/dyserythropoiesis and pancytopenia have been described in the literature.<sup>[3,4,9]</sup> Hormonal evaluation was done in some studies. A growth hormone stimulation test with arginine was consistent with growth hormone deficiency, providing an explanation for the short stature.<sup>[1,4]</sup> Low insulin-like growth factor 1 level was reported as another contributing factor to short stature. The sex hormone profile showed relatively high gonadotropins and low testosterone levels, indicating primary hypogonadism.<sup>[1,4]</sup> Our patient had many of these findings [Table 1].

Skin biopsy specimens in the H syndrome demonstrate polyclonal perivascular lympho-histiocytic infiltrates and hyperpigmentation of the basal layer,<sup>[5]</sup> as with our

**Table 1: The clinical and biological findings characterizing H syndrome in our patient compared with those reported in the literature**

Clinical and biological findings in H syndrome described in the literature	Features in our patient
Hypertrichosis	+
Hyperpigmentation	+
Hearing loss	+
Hepatosplenomegaly	+
Heart anomalies	-
Flexion contractures	+
Lymphadenopathy	-
Insulin-dependent diabetes mellitus	+
Micropenis	+
Hyperglycemia	+
Hypertriglyceridemia	-
Anemia	-
Red cell aplasia	-
Dyserythropoiesis	-
Pancytopenia	-
Hormone stimulation test with arginine: positive	-
Low insulin-like growth factor	+

+: Feature present, -: Feature not found

patient. However, in our case, immunohistochemical stains showed histiocytes positive for CD1a and PS100, a feature not described earlier. Our patient could therefore be considered as having a variant of H syndrome, within the spectrum of inherited histiocytosis.

Till now, only twenty mutations have been identified in the H syndrome.<sup>[3]</sup> Our patient had two different mutations previously described: a missense mutation c. 1088G>A changing arginine 363 to glutamine (p.Arg363Gln) previously detected in Arab patients and a splice site mutation, c. 300+1G>A which was reported in Pakistani patients.<sup>[5]</sup> The spectrum of phenotypes related to SLC29A3 mutations appears to be very wide, ranging from a severe syndrome as in our patient, to a very mild clinical presentation. No clear correlation between any of the clinical features and a specific mutation has been found. In fact, patients with a mild phenotype have been identified after mutation screening in families with severely affected individuals.<sup>[4]</sup> There is no specific treatment for this syndrome, and genetic counseling is essential.

**Financial support and sponsorship**

Nil.

**Conflicts of interest**

There are no conflicts of interest.

**Mouna Korbi, Amina Aounallah, Dorra Hmida<sup>1</sup>, Najet Ghariani, Wafa Saidi, Lobna Boussofara, Colandone Belajouza, Laurence Jonard<sup>2</sup>, Badreddine Sriha<sup>2</sup>, Ali Saad<sup>1</sup>, Mohamed Denguezli, Rafiaa Nouira**

Departments of Dermatology, <sup>1</sup>Medical Genetics, <sup>2</sup>Pathological Anatomy and Cytology, Farhat Hached Hospital, Sousse, Tunisia, <sup>3</sup>Department of Biochemistry and Molecular Biology, Trousseau Hospital, Paris, France

**Address for correspondence:** Dr. Mouna Korbi, Department of Dermatology, Farhat Hached Hospital, Sousse, Tunisia. E-mail: korbimouna68@gmail.com

**REFERENCES**

- Molho-Pessach V, Agha Z, Amar S, Glaser B, Doviner V, Hiller N, *et al.* The H syndrome: A genodermatosis characterized by indurated, hyperpigmented, and hypertrichotic skin with systemic manifestations. *J Am Acad Dermatol* 2008;59:79-85.
- Sharad M, Vaishali M, Asit M, Achok KK, Lalit GK. The H syndrome. *Indian J Peadiatric Dermatol* 2015;16:102-4.
- Molho-Pessach V, Ramot Y, Camille F, Doviner V, Babay S, Luis SJ, *et al.* H syndrome: The first 79 patients. *J Am Acad Dermatol* 2014;70:80-8.
- Molho-Pessach V, Lerer I, Abeliovich D, Agha Z, Abu Libdeh A, Broshtilova V, *et al.* The H syndrome is caused by mutations in the nucleoside transporter hENT3. *Am J Hum Genet* 2008;83:529-34.
- Jonard L, Couloigner V, Pierrot S, Louha M, Gherbi S, Denoyelle F, *et al.* Progressive hearing loss associated with a unique cervical node due to a homozygous SLC29A3 mutation: A very mild phenotype. *Eur J Med Genet* 2012;55:56-8.
- Hiller N, Zlotogorski A, Simanovsky N, Ingber A, Ramot Y, Molho-Pessach V. The spectrum of radiological findings in H syndrome. *Clin Imaging* 2013;37:313-9.
- Ramot Y, Sayama K, Sheffer R, Doviner V, Hiller N, Kaufmann-Yehezkeley M, *et al.* Early-onset sensorineural hearing loss is a prominent feature of H syndrome. *Int J Pediatr Otorhinolaryngol* 2010;74:825-7.
- Broshtilova V, Ramot Y, Molho-Pessach V, Zlotogorski A. Diabetes mellitus may be the earliest and sole manifestation of the H syndrome. *Diabet Med* 2009;26:1179-80.
- Priya TP, Philip N, Molho-Pessach V, Busa T, Dalal A, Zlotogorski A. H syndrome: Novel and recurrent mutations in SLC29A3. *Br J Dermatol* 2010;162:1132-4.

This is an open access article distributed under the terms of the Creative Commons Attribution-NonCommercial-ShareAlike 3.0 License, which allows others to remix, tweak, and build upon the work non-commercially, as long as the author is credited and the new creations are licensed under the identical terms.

Access this article online	
<b>Quick Response Code:</b>	<b>Website:</b> www.ijdv1.com
	<b>DOI:</b> 10.4103/0378-6323.185044

**How to cite this article:** Korbi M, Aounallah A, Hmida D, Ghariani N, Saidi W, Boussofara L, *et al.* H syndrome with histological features of Langerhans cell histiocytosis. *Indian J Dermatol Venereol Leprol* 2016;82:702-4.

**Received:** August, 2015. **Accepted:** February, 2016.