

A novel mutation in neurofibromatosis type 1

Dear Editor,

Neurofibromatosis type 1 (NF1) is an autosomal dominant disorder with a global prevalence of about 0.03% caused by mutations in the neurofibromatosis type 1 gene at 17q11.2, which encodes neurofibromin. Approximately half of the patients have family history and the others have sporadic mutations.¹ Typical symptoms of neurofibromatosis type 1 include café-au-lait macules, cutaneous neurofibroma or plexiform neurofibroma, axillary or inguinal freckles, iris Lisch nodules, optic pathway gliomas, skeletal dysplasia, behavioural defects and cognitive impairment.

The proband was a 21-year-old woman. There were many café-au-lait macules of different sizes all over the body since one month after birth. The number of the café-au-lait macules in the waist and abdomen gradually increased and fused with age. At around 16-years of age, subcutaneous mass appeared on her both sides of the lumbar ribs and gradually increased in size [Figure 1]. Pathology of subcutaneous mass biopsy showed tumours formed by spindle cells [Figure 1]. neurofibromatosis type 1 was diagnosed by the diagnostic criteria formulated by the National Institutes of Health. The proband's mother also had café-au-lait macules, tumours and freckles [Figure 2], and a biopsy was performed on her posterior dorsal tumours [Figure 2]. The proband's maternal grandmother and second aunt also had café-au-lait macules. Her father and sister were normal.

We collected blood samples from the proband, her parents and sister after the informed consent. This study was approved by the hospital ethics committee. The DNA of the proband's mother was sent to the company (Shanghai SARO Biotechnology Co., Ltd.) for panel-targeted capture sequencing. The novel mutation was verified in the proband, her father and sister by Sanger sequencing.

A point mutation (*c.T1664>G*) in exon 15 of the neurofibromatosis type 1 gene (NM_001042492) was found, which caused the cDNA from T to G at position 1664, resulting in premature termination of protein translation at

position 555 and abnormal structure of neurofibromin. The mutation was detected in the proband but not in her sister and father by Sanger sequencing [Figure 3]. Mutation Taster predicted this mutation to be “D” (disease causing) and the Likelihood Ratio Test predicts deleterious. It is not described in gnomAD exomes and any other databases. According to the American College of Medical Genetics and Genomics guidelines, this variant is a nonsense mutation and can be interpreted as a pathogenic variant of neurofibromatosis type 1 (PVS1+PM2+PP1).²

More than 3000 pathogenic mutations have been identified in the neurofibromatosis type 1 gene, including missense, nonsense, splicing, microdeletion, microinsertion, total deletion (>20 bp), total insertion (>20 bp) and complex rearrangement. The penetrance of neurofibromatosis type 1 is 100%, but the expression of the neurofibromatosis type 1 gene is highly variable and age-dependent. Even within the same family, the clinical manifestations can be variable in different patients. As in this case, though the proband and her mother held the same mutation, the mother mainly presented with cutaneous neurofibroma, while the proband mainly had giant type plexiform neurofibroma. Phenotype differences may be related to allelic and nonallelic heterogeneity, cell heterogeneity, epigenetics, modified loci, environmental and random factors.

In our case, the mutation is a premature termination codon mutation. Depending on the differences of the clinical manifestations of the proband and her mother, it is not possible to judge whether the mutation causes serious phenotypes, which may require a comprehensive physical examination and long-term follow-up. So far, we have found that five genotypes are clinically identified to be associated with the phenotypes, and there is no correlation between premature termination codon mutations and specific phenotypes. It is only suggested that neurofibromatosis type 1 gene microdeletion and total deletion are associated with severe phenotypes. The number of plexiform and spinal neurofibromas increases, and intellectual and skeletal abnormalities can occur.³

How to cite this article: Luo Z, Tao X, Jin Z, Wang Z. A novel mutation in neurofibromatosis type 1. *Indian J Dermatol Venereol Leprol* 2023;89:453-5.

Received: May, 2022 **Accepted:** September, 2022 **Epub Ahead of Print:** December, 2022 **Published:** April, 2023

DOI: 10.25259/IJDVL_480_2022 **PMID:** 36688894

This is an open-access article distributed under the terms of the Creative Commons Attribution-Non Commercial-Share Alike 4.0 License, which allows others to remix, transform, and build upon the work non-commercially, as long as the author is credited and the new creations are licensed under the identical terms.

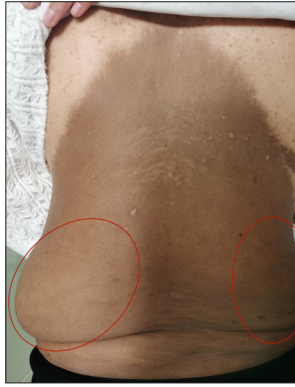

Figure 1a: A 21-year-old woman with neurofibromatosis type 1. (a): Large brown patch on the back of the proband and subcutaneous mass of waist (left about 20 cm * 15 cm * 1 cm, right about 10 cm * 8 cm * 1 cm)

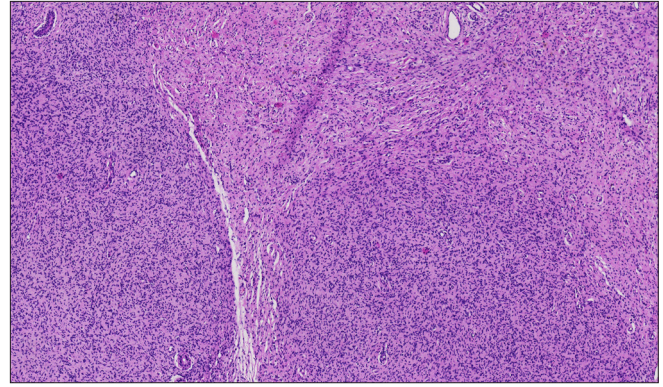


Figure 1b: Histopathology of a subcutaneous mass on the posterior back of the proband (H&E, ×40). Tumours formed by spindle cells were found in the dermis, involving subcutaneous adipose tissue and unclear boundaries. Spindle cell cytoplasm is not obvious, nucleus spindle or oval

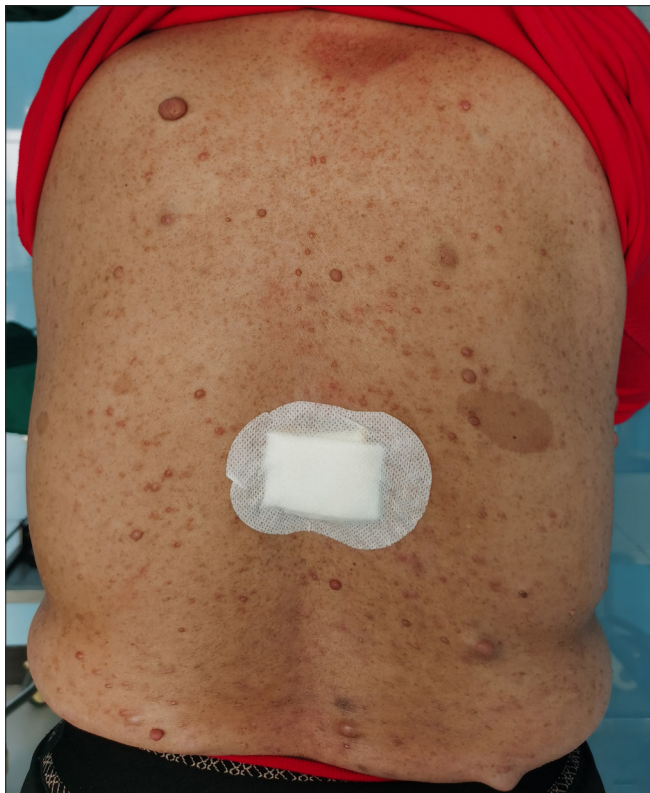

Figure 2a: A 52-year-old woman with neurofibromatosis type 1. Cutaneous neurofibroma of various sizes on the back (a) and freckles in the armpit

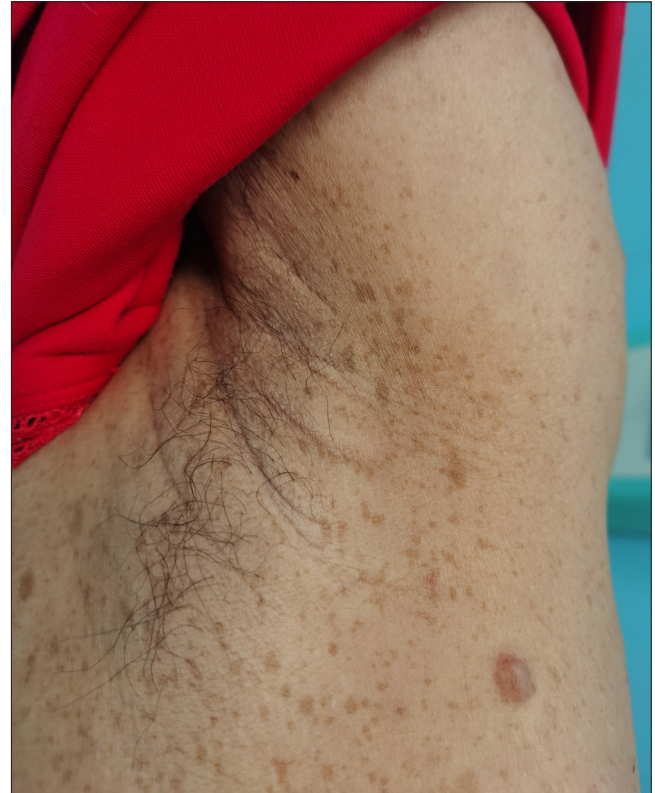

Figure 2b: A 52-year-old woman with neurofibromatosis type 1. Cutaneous neurofibroma of various sizes on the back (b) of the proband's mother

Different phenotypes were found in mutations with different locations. The missense change of codon 1809 (p. Arg1809 Cys) mainly manifested as café-au-lait macules and freckles, macrocephaly, growth retardation and learning problems;⁴ the missense mutations affecting codons 844–848 are related to the severe phenotypes, which can be manifested as high

risk of plexiform neurofibroma, spinal neurofibroma and even malignant transformation.⁵ Mild phenotype is associated with in-frame deletion of codon 992 (p.Met992del) mainly characterised by pigmentation-like features without cutaneous neurofibroma.⁶ Therefore, there was no significant phenotypic difference in the mutation types.

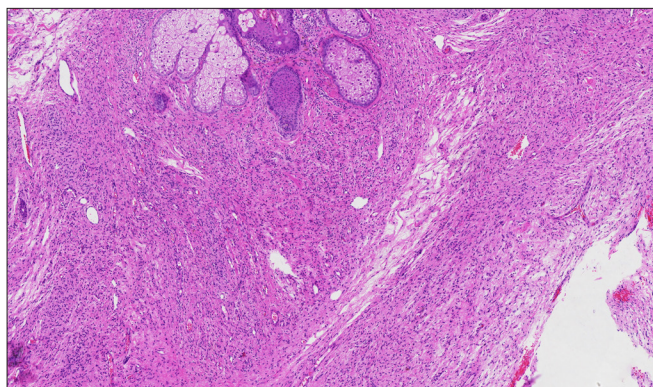


Figure 2c: Histopathology of a cutaneous neurofibroma on the back of the mother (H&E, ×40). The tumours formed by spindle cells have unclear boundaries, unobvious cytoplasm of spindle cells, and spindle or oval nuclei

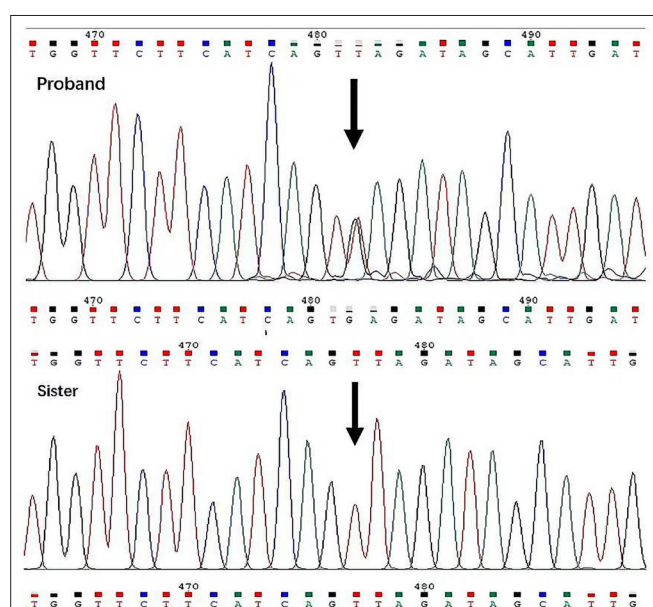


Figure 3: Nonsense mutation c.T1664>G (position indicated by arrow) in the proband, but not in the sister

In summary, we have identified a novel nonsense mutation in the neurofibromatosis type 1 gene causing different phenotypes of neurofibromatosis in family lines, and our findings expand

the spectrum of mutations causing neurofibromatosis type 1 and provide information for genetic counselling.

Declaration of patient consent

The authors certify that they have obtained all appropriate patient consent.

Financial support and sponsorship

Nil.

Conflict of interest

There are no conflicts of interest.

Zhen Luo, Xiaoran Tao, Zhangsi Jin, Zaixing Wang

Department of Dermatology, First Affiliated Hospital of Anhui Medical University, Hefei, Anhui, China.

Corresponding author:

Dr. Zaixing Wang,
Department of Dermatology, First Affiliated
Hospital of Anhui Medical University,
Hefei, Anhui, China.
wzx2370@163.com

References

- McKeever K, Shepherd CW, Crawford H, Morrison PJ. An epidemiological, clinical and genetic survey of neurofibromatosis type 1 in children under sixteen years of age. *Ulster Med J* 2008;77:160–3.
- Richards S, Aziz N, Bale S, Bick D, Das S, Gastier-Foster J, *et al.* Standards and guidelines for the interpretation of sequence variants: A joint consensus recommendation of the American College of Medical Genetics and Genomics and the Association for Molecular Pathology. *Genet Med* 2015;17:405–24.
- Well L, Döbel K, Kluwe L, Bannas P, Farschtschi S, Adam G, *et al.* Genotype-phenotype correlation in neurofibromatosis type-1: NF1 whole gene deletions lead to high tumor-burden and increased tumor-growth. *PLoS Genet* 2021;17:e1009517.
- Pinna V, Lanari V, Daniele P, Consoli F, Agolini E, Margiotti K, *et al.* p.Arg1809Cys substitution in neurofibromin is associated with a distinctive NF1 phenotype without neurofibromas. *Eur J Hum Genet* 2015;23:1068–71. 10.1038/ejhg.2014.243
- Ruggieri M, Polizzi A, Spalice A, Salpietro V, Caltabiano R, D'Orazi V, *et al.* The natural history of spinal neurofibromatosis: a critical review of clinical and genetic features. *Clin Genet* 2015;87:401–10. 10.1111/cge.12498
- Bettegowda C, Upadhyaya M, Evans DG, Kim A, Mathios D, Hanemann CO, *et al.* Genotype-phenotype correlations in neurofibromatosis and their potential clinical use. *Neurology* 2021;97:S91–8.