

Sweet's syndrome associated with chronic neutrophilic leukemia

Sir,

Sweet's syndrome is characterized by fever, leucocytosis, tender erythematous plaques and nodules, and a dense dermal neutrophilic infiltrate.^[1] It has been reported in association with both hematologic malignancies and solid organ tumors.^[2] We report a patient of chronic neutrophilic leukemia (CNL), presenting with Sweet's syndrome. We were able to find only one previous report of this association.^[3]

A 33-year-old male presented with a 3-week history of skin lesions over face, neck, and upper limbs accompanied by intense burning sensation, fever, anorexia, and myalgia. His past medical history was unremarkable. Examination revealed multiple, well defined, violaceous, edematous, papules and plaques, over the entire face, front and back of

neck, retroauricular area, extensor aspect of arms, dorsal aspect of both hands, and fingers. The surface showed pseudovesiculation and marked edema [Figures 1 and 2]. Similar lesions developed over dorsum of both feet and lower legs over the next few days. There was conjunctival congestion, hepatomegaly and marked splenomegaly, but no lymphadenopathy or oral erosions. Investigations revealed leucocytosis of $71.8 \times 10^9/L$ (reference range $4-10 \times 10^9/L$) with a differential count of 81% neutrophils, 7% lymphocytes, 1% monocytes, 3% eosinophils, 5% myelocytes, and 3% metamyelocytes. The immature myeloid precursors were less than 10%, without blasts, and basophils or toxic granules were not seen. Hemoglobin was 10.2 g/dL, and platelet count was $9 \times 10^9/L$ (reference range $150-410 \times 10^9/L$). Erythrocyte sedimentation rate (ESR) was 115 mm/h (reference range 0-20 mm/h), C-reactive protein was 171.2 mg/L (reference range 0-6 mg/L), and serum lactate dehydrogenase was 463 U/L (135-225 U/L). Leukocyte alkaline phosphatase (LAP) score was 120 (reference range: 20-120). Serum vitamin B 12 levels were 2000 pg/ml (reference value 191-663 pg/ml). Liver and renal function tests, urine analysis, thyroid profile were normal; screening for antinuclear antibodies and serology for Hepatitis B, C and human immunodeficiency virus was negative. Blood and urine cultures were sterile and test for stool occult blood was negative. Chest X-ray was normal while computed tomography (CT) scan of abdomen revealed marked splenomegaly with peripheral hypo-dense, non-enhancing areas suggestive of infarcts. Histopathology of skin lesions showed a diffuse neutrophilic infiltrate within the upper dermis, dermal edema, and prominent leucocytoclasia [Figure 3]. No immature or atypical cells, granuloma formation or microorganisms were detected. Based on these features, the diagnosis of Sweet's syndrome was established [Table 1]. Peripheral blood findings were suggestive of a leukemoid reaction or a chronic myeloproliferative neoplasm. Bone marrow aspiration smears showed a hypercellular marrow exhibiting myeloid hyperplasia with myeloid: erythroid ratio of 8:1. The myeloid series showed an orderly cell maturation having no prominence of blast cells, eosinophils or their precursors. Erythroid series showed normoblastic maturation and megakaryocytes were normal in number and morphology. There was no prominence of plasma cells or dysplasia in any lineage [Figure 4a]. Bone marrow biopsy showed a hypercellular marrow exhibiting marked myeloid hyperplasia. Both megakaryocytes and erythroid precursors were identified. No fibrosis was noted [Figure 4b]. BCR/ABL gene translocation assay

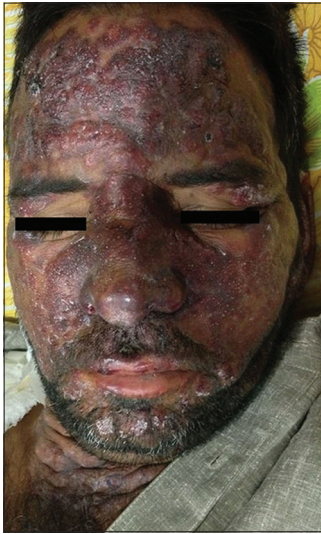

Figure 1: Violaceous plaques with pseudovesiculation over face

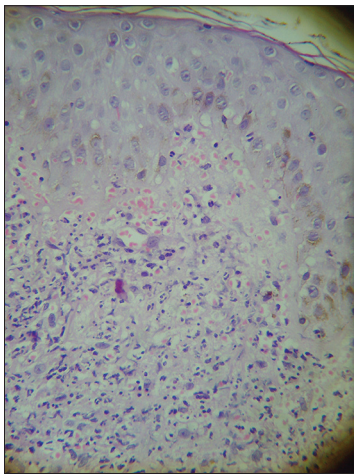


Figure 3: Histopathology of skin lesion showing a dense neutrophilic infiltrate in the dermis (H and E 400x)

showed negative results, thus excluding the major, minor, and micro breakpoints corresponding to p210, p190, p230 kDa proteins. No mutations were observed in the JAK2 gene.

Among the myeloproliferative neoplasms, chronic myeloid leukemia (CML), atypical CML, and chronic neutrophilic leukemia were the most important conditions in the differential diagnosis. The first two conditions were excluded in view of mature neutrophilic leucocytosis, absence of immature precursors, or basophilia, normal leukocyte alkaline phosphatase score and negative results for BCR/ABL. Absence of thrombocytosis, megakaryocytic hyperplasia in bone marrow and negative JAK2 mutation excluded polycythemia vera and essential thrombocythemia. Absence of fibrosis ruled out primary myelofibrosis and absence of eosinophilia

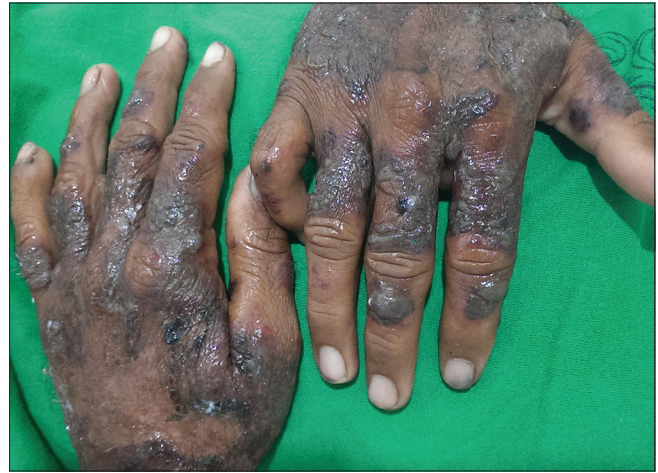

Figure 2: Well defined violaceous plaques and vesicobullous lesions on dorsal surface of hands

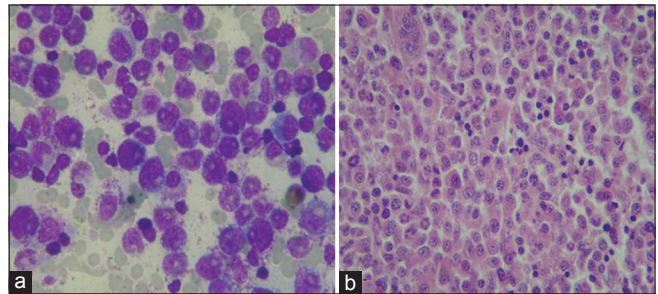


Figure 4: (a) Bone marrow aspiration showing marked myeloid hyperplasia. No prominence of blast cells seen (Giemsa stain 1000x). (b) Bone marrow biopsy exhibiting hypercellular marrow and myeloid hyperplasia without blasts (H and E 400x)

excluded chronic eosinophilic leukemia. Lack of evidence of any infective pathology or solid malignancy based on histopathology, microbiology and imaging studies, lack of toxic granules and a normal leukocyte alkaline phosphatase score, went against the diagnosis of leukemoid reaction.

With these findings, a final diagnosis of chronic neutrophilic leukemia associated with Sweet's syndrome was established [Table 1]. Prednisolone 1 mg/kg/day and hydroxyurea 500 mg/day was initiated along with supportive therapy. Corticosteroids were gradually tapered and his skin lesions regressed. Currently he is in remission, with normal blood counts and is continuing treatment with hydroxyurea 500 mg/day.

Malignancy associated or paraneoplastic Sweet's syndrome, in which either the onset or recurrence of the dermatosis is temporally associated with the presence of malignancy, is currently considered a distinct subset.^[1] It has an equal incidence in males and females and is characterized by recurrent episodes,

Table 1: Diagnostic criteria of Sweet's syndrome and Chronic Neutrophilic Leukemia and the corresponding patient data

Criteria of Sweet's syndrome	Patient data	Criteria of CNL*	Patient data
Rapid onset of characteristic skin lesions, which are tender erythematous plaques or nodules	✓	Peripheral blood leucocytosis (WBC>25×10 ⁹ /L) Segmented neutrophils and band forms are>80% of the WBCs Immature granulocytes (promyelocytes, myelocytes, metamyelocytes) are <10% of WBCs Myeloblasts are <1% of WBC	✓
Typical histopathologic features: Dense neutrophilic infiltration in dermis without leucocytoclastic vasculitis	✓	Hypercellular bone marrow biopsy Neutrophilic granulocytes increased in number and percentage Myeloblasts <5% of nucleated bone marrow cells Neutrophilic maturation pattern normal Megakaryocytes normal or left shifted	✓
Accompanied by fever(>38°C), or general malaise	✓	Hepatosplenomegaly	✓
Preceded by nonspecific respiratory or gastrointestinal infection or immunization, or associated with hematologic or solid neoplasia inflammatory disorder or pregnancy	✓	No identifiable cause for physiologic neutrophilia or, if present, demonstration of clonality in myeloid cells by cytogenetic or molecular studies No infectious or inflammatory process No underlying tumor	
Excellent response to corticosteroids or potassium iodide	✓	No Philadelphia chromosome or BCR/ABL fusion gene	✓
Abnormal laboratory values at presentation, (3 out of 4 necessary) ESR>20, Leukocytes>8000, Neutrophils>70%, CRP positive	✓	No rearrangement of PDGFRA, PDGFRB or FGFR1 No evidence of polycythemia vera, essential thrombocythemia, or primary myelofibrosis No evidence of MDS or MDS/MPN No granulocytic dysplasia No myelodysplastic changes in other myeloid lineages Monocytes <1×10 ⁹ /L	Not done ✓ ✓

*CNL: Chronic neutrophilic leukemia, WBC: White blood corpuscles, ESR: Erythrocyte sedimentation rate, CRP: C-reactive protein, MDS: Myelodysplastic syndrome, MPN: Myeloproliferative neoplasia, FGFR: Fibroblast growth factor receptor, PDGFR: Platelet derived growth factor receptor

Table 2^[1,2]: Drugs used for treatment of malignancy associated Sweet's syndrome

First line agents	Second line agents
Systemic corticosteroids (oral, high dose)	Dapsone
Methylprednisolone (intravenous pulse)	Indomethacin
Intralesional corticosteroids	Clofazimine
Potassium iodide	Cyclosporine
Colchicine	Thalidomide
	Chlorambucil
	Cyclophosphamide
	Antimetabolites
	Immunoglobulins
	Interferon-α
	Tumor necrosis factor
	Antiangiogenic agents
	Infliximab

more frequent extracutaneous manifestations and a lack of preceding upper respiratory tract infection.^[1,2] Clinically, ulcerated plaques, nodules, vesicles, and bullae are noticed more often.^[2] A hematologic malignancy or a solid tumor was present in approximately 21% of patients newly diagnosed with Sweet's syndrome.^[2] About 85% patients had underlying hematopoietic neoplasia, while 15% had

solid malignancies.^[2] A good response is observed with systemic corticosteroids. Several other drugs are useful in these patients [Table 2].^[1,2]

Chronic neutrophilic leukemia is a rare myeloproliferative neoplasm characterized by sustained peripheral blood neutrophilia, bone marrow hypercellularity due to neutrophilic granulocyte proliferation, hepatosplenomegaly and no Philadelphia chromosome or BCR/ABL 1 fusion gene.^[4] Prognosis is poor with a mean survival time of approximately 2 years.^[4] The diagnosis requires exclusion of reactive neutrophilia and other myeloproliferative neoplasms,^[5] which were ruled out by appropriate laboratory investigations in our case.

Sukhjot Kaur, Amit Bery¹, Bhavna Garg², Neena Sood²

Department of Dermatology and Venereology, ¹Internal Medicine, ²Pathology, Dayanand Medical College and Hospital, Ludhiana, India

Address for correspondence: Dr. Sukhjot Kaur, Department of Dermatology and Venereology, Dayanand Medical College and Hospital, Ludhiana, India. E-mail: sukhjotgoraya@gmail.com

REFERENCES

1. Raza S, Kirkland RS, Patel AA, Shortridge JR, Freter C. Insight into Sweet's syndrome and associated-malignancy: A review of the current literature. *Int J Oncol* 2013;42:1516-22.
2. Cohen PR, Kurzrock R. Sweet's syndrome and Cancer. *Clin Dermatol* 1993;11:149-57.
3. Castanet J, Lacour JP, Garnier G, Perrin C, Taillan B, Fizibet JG, *et al.* Neutrophilic dermatosis associated with chronic neutrophilic leukemia. *J Am Acad Dermatol* 1993;29:290-2.
4. Bain BJ, Brunning RD, Vardiman J, Thiele J. Chronic neutrophilic leukemia. In: Swerdlow, Campo E, Harris NL, editors. *International Agency for research on cancer. WHO Classification of Tumours of Hematopoeitic and Lymphoid tissue.* Geneva, Switzerland: World Health Organization; 2008. p. 38-9.
5. Neureiter D, Kemmerling R, Ocker M, Seidhofer C, Faber V, Stocher M, *et al.* Differential diagnostic challenge of chronic neutrophilic leukemia in a patient with prolonged leucocytosis. *J Hematop* 2008;1:23-7.

Access this article online	
Quick Response Code:	Website: www.ijdvl.com
	DOI: 10.4103/0378-6323.152304