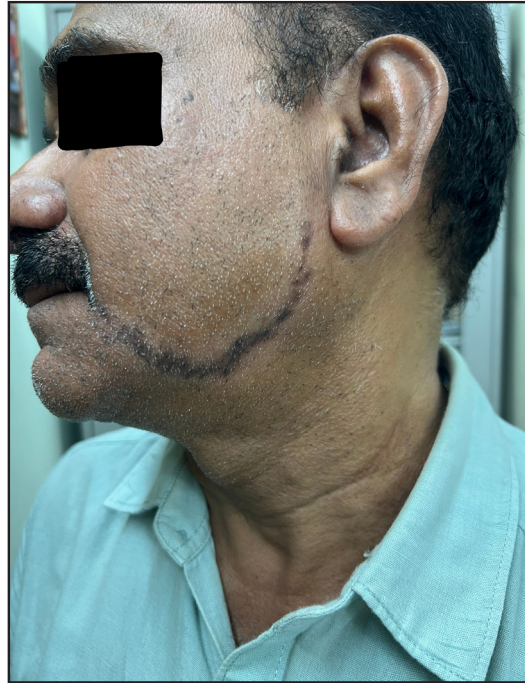

## Blaschkoid lichen planus pigmentosus on face

A 53-year-old man presented with an asymptomatic hyperpigmented lesion along the lines of Blaschko, extending from the left angle of the mouth to the left ear, of one-year duration [Figure 1]. There were no similar lesions elsewhere on the body. Lesional biopsy revealed numerous prominent melanophages in the upper dermis with an intact

basal layer, features which were suggestive of lichen planus pigmentosus (LPP). LPP commonly presents as reticular or diffuse morphological types. Cases of linear LPP are rarely reported. The presence of lesions along the lines of Blaschko suggests that the predisposition to develop such lesions was probably determined in the early embryonic phase of life.




**Figure 1:** Hyperpigmented lesion along the lines of Blaschko extending from the left angle of mouth to left ear.

**Declaration of patient consent:** The authors certify that they have obtained all appropriate patient consent.

**Financial support and sponsorship:** Nil.

**Conflicts of interest:** There are no conflicts of interest.

**Use of artificial intelligence (AI)-assisted technology for manuscript preparation:** The authors confirm that there was no use of artificial intelligence (AI)-assisted technology for assisting in the writing or editing of the manuscript and no images were manipulated using AI.

*Singamsetty Sushma<sup>1</sup>, Kollipara Haritha<sup>2</sup> , Gandikota Raghu Rama Rao<sup>3</sup>, Sudhir Babu K<sup>4</sup>*

<sup>1</sup>Consultant Dermatologist, Surya Skin Care & Research Centre, Visakhapatnam, <sup>2</sup>Department of Dermatology, Venereology and Leprosy, GITAM Institute of Medical Sciences and Research, Visakhapatnam,

<sup>3</sup>Consultant Dermatologist, Surya Skin Care & Research Centre, <sup>4</sup>Consultant Pathologist, Vijaya Diagnostic Centre, Visakhapatnam, India.

**Corresponding author:**

Dr. Gandikota Raghu Rama Rao,  
Consultant Dermatologist, Surya Skin Care & Research Centre,  
Visakhapatnam, India. graghuramarao@gmail.com

**How to cite this article:** Sushma S, Haritha K, Raghu GRR, KSB. Blaschkoid lichen planus pigmentosus on face. Indian J Dermatol Venereol Leprol. doi: 10.25259/IJDVL\_709\_2024

**Received:** May, 2024 **Accepted:** December, 2024 **Epub Ahead of Print:** March, 2025

**DOI:** 10.25259/IJDVL\_709\_2024

This is an open-access article distributed under the terms of the Creative Commons Attribution-Non Commercial-Share Alike 4.0 License, which allows others to remix, transform, and build upon the work non-commercially, as long as the author is credited and the new creations are licensed under the identical terms.