

## References

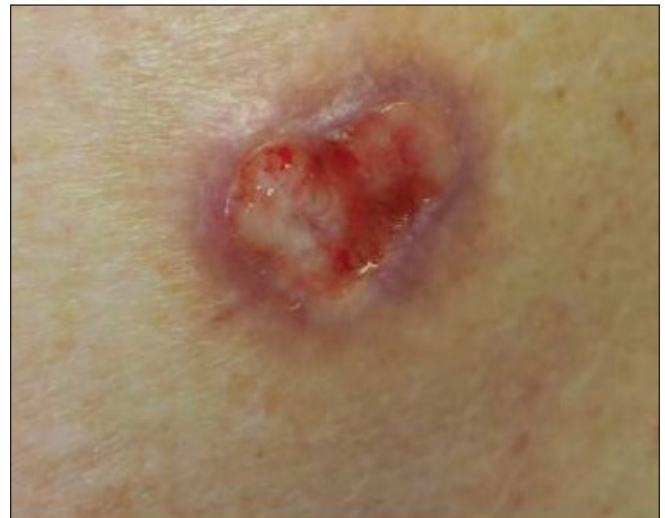1. Cameron MC, Lee E, Hibler BP, Barker CA, Mori S, Cordova M, *et al.* Basal cell carcinoma: Epidemiology; pathophysiology; clinical and histological subtypes; and disease associations. *J Am Acad Dermatol* 2019;80:303–17.
2. Iorizzo LJ, Brown MD. Atypical fibroxanthoma: A review of the literature. *Dermatologic Surg*. 2011;37:146–57.
3. Alves R, Ocaña J, Vale E, Correia S, Viana I, Bordalo O. Basal cell carcinoma and atypical fibroxanthoma: An unusual collision tumor. *J Am Acad Dermatol* 2010;63:e74–e76.
4. Speiser JJ, Aggarwal S, Wold L, Tung R, Hutchens KA. A rare collision in dermatopathology: Basal cell carcinoma and atypical fibroxanthoma. *Am J Dermatopathol* 2015;37:950–3.
5. Wentzell S FH. A rare collision of atypical fibroxanthoma and basal cell carcinoma. *J Case Rep Images Pathol* 2018.
6. Bulte CA, Hoegler KM, Khachemoune A. Collision tumors: A review of their types, pathogenesis, and diagnostic challenges. *Dermatol Ther* 2020;33.
7. Boyd AS, Rapini RP. Cutaneous collision tumors: An analysis of 69 cases and review of the literature. *Am J Dermatopathol* 1994;16:253–7.
8. Cohen PR, Calame A. Multiple skin neoplasms at one site (Musk in a nest): A comprehensive review of basal cell carcinoma and benign or malignant “collision” tumors at the same cutaneous location. *Clin Cosmet Investig Dermatol* 2020;13:731–41.
9. Satter EK, Metcalf J, Lountzis N, Elston DM. Tumors composed of malignant epithelial and melanocytic populations: A case series and review of the literature. *J Cutan Pathol* 2009;36:211–9.
10. Youssef KK, Lapouge G, Bouvrée K, Rorive S, Brohée S, Appelstein O, *et al.* Adult interfollicular tumour-initiating cells are reprogrammed into an embryonic hair follicle progenitor-like fate during basal cell carcinoma initiation. *Nat Cell Biol* 2012;14:1282–94.
11. Koelsche C, Stichel D, Griewank KG, Schrimpf D, Reuss DE, Bewerunge-Hudler M. Genome-wide methylation profiling and copy number analysis in atypical fibroxanthomas and pleomorphic dermal sarcomas indicate a similar molecular phenotype. *Clin Sarcoma Res* 2019;9:2.
12. Cornejo KM, Deng AC. Malignant Melanoma Within Squamous Cell Carcinoma and Basal Cell Carcinoma. *Am J Dermatopathol* 2013;35:226–34.
13. Blum A, Siggs G, Marghoob A. Collision skin lesions—results of a multicenter study of the International Dermoscopy Society (IDS). *Dermatol Pract Concept* 2017;7:51–62.
14. Soleymani T, Aasi SZ, Novoa R, Hollmig ST. Atypical fibroxanthoma and pleomorphic dermal sarcoma: Updates on classification and management. *Dermatol Clin* 2019;37:253–9.
15. Moscarella E, Piana S, Specchio F, Kyrgidis A, Nazzaro G, Eliceche ML, *et al.* Dermoscopy features of atypical fibroxanthoma: A multicenter study of the international dermoscopy society. *Australas J Dermatol* 2018;59:309–14.
16. Yélamos O, Braun RP, Liopyris K, Wolner ZJ, Kerl K, Gerami P, *et al.* Dermoscopy and dermatopathology correlates of cutaneous neoplasms. *J Am Acad Dermatol* 2019;80:341–63.

# Squamoid eccrine ductal carcinoma: A frequently misdiagnosed entity

Dear Editor,

Eccrine carcinomas comprise around 0.01% of all tumours.<sup>1</sup> Squamoid eccrine ductal carcinoma (SEDC) is a rare tumour first described by Wong *et al.* in 1997, representing a lesion showing eccrine ductal differentiation along with a prominent squamous component.<sup>2</sup> It usually involves the head and neck area and only few cases have been reported in the English literature, including a series of 30 patients by van der Horst *et al.*<sup>3</sup> Accurate diagnosis is crucial given its aggressive nature, along with increased risk of local recurrence and metastasis.

An 89-year-old male presented to VA Medical Center, Pittsburgh with a non-healing lesion of unknown duration on right posterior shoulder. Clinical examination revealed a 2.0 × 1.0 cm ulcerated pink plaque with violaceous border [Figure 1]. Histopathology revealed epidermal ulceration with proliferation of infiltrating glandular structures composed of markedly pleomorphic squamoid cells containing intraluminal secretions [Figures 2a and 2b]. Abundant mitoses were noted, along with tumour cell necrosis and focal

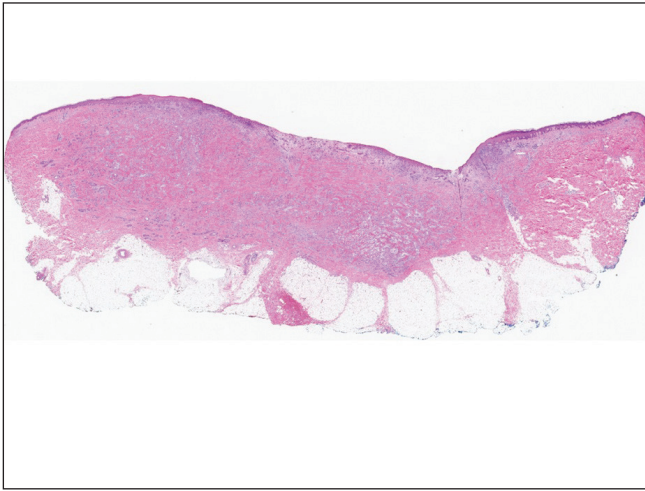


**Figure 1:** Ulcerated pink plaque (2.0 × 1.0 cm) with violaceous border on the right posterior shoulder.

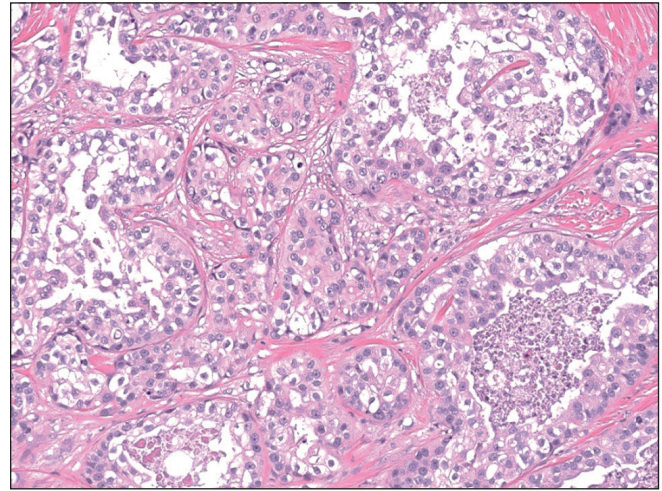
**How to cite this article:** Srivastava P, Dando E, Doeden K. Squamoid eccrine ductal carcinoma: A frequently misdiagnosed entity. *Indian J Dermatol Venereol Leprol*. 2024;90:503-5. doi: 10.25259/IJDVL\_310\_2022

**Received:** March, 2022 **Accepted:** May, 2023 **Epub Ahead of Print:** June, 2023 **Published:** June, 2024

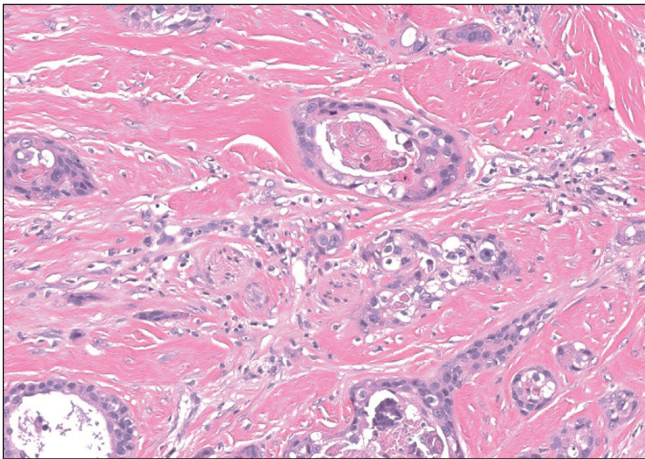
**DOI:** 10.25259/IJDVL\_310\_2022 **PMID:** 37436011



**Figure 2a:** Epidermal ulceration and proliferation of tumour cells within the dermis (Haematoxylin & Eosin, 20x).



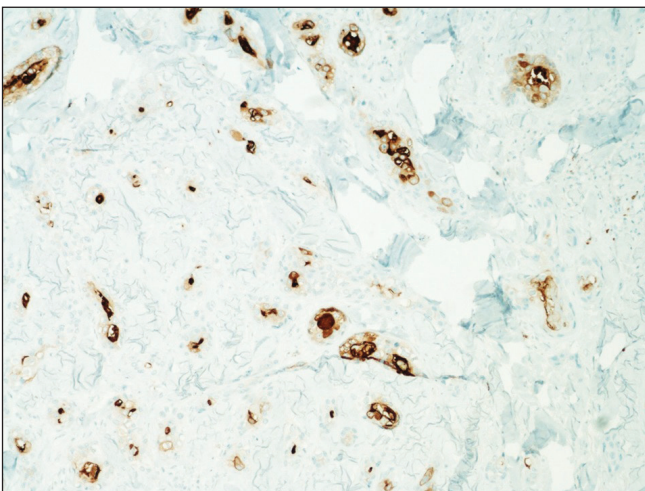
**Figure 2b:** Proliferation of infiltrating glandular structures within the dermis with ductal structures showing markedly pleomorphic squamoid cells (Haematoxylin & Eosin, 200x).



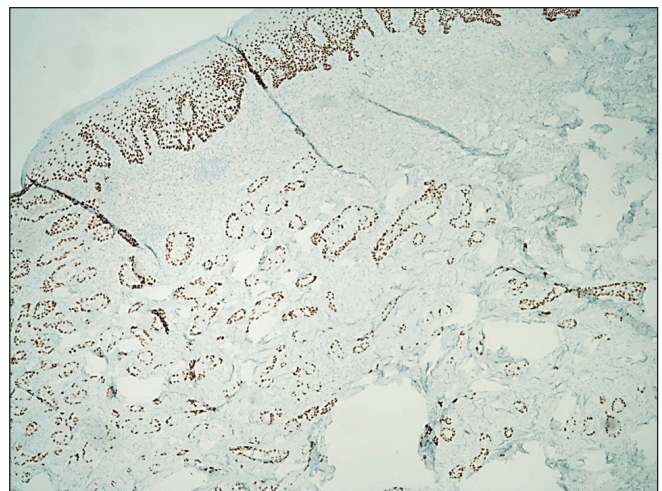
**Figure 2c:** Tumour cells with foci of intraluminal necrosis and perineural infiltration (Haematoxylin & Eosin, 200x)

perineural invasion [Figure 2c]. On immunohistochemistry, the neoplastic cells were positive for CEA [Figure 3a], p63 [Figure 3b], CK5/6 and weakly positive for GATA3. Mucicarmine stain was negative. Based on morphology and immunohistochemistry, a diagnosis of squamoid eccrine ductal carcinoma was made. We recommended wide local excision, but the patient declined further management citing advanced age and medical comorbidities. He died two years later due to unrelated causes.

Squamoid eccrine ductal carcinoma is a rare eccrine carcinoma, commonly affecting the seventh to eighth decade (age range 30–91 years). There is slight male predominance and usually involves the head and neck as a slow-growing nodule or plaque with ulceration or crusting.<sup>2</sup> Few cases have been reported in the extremities or trunk.<sup>3</sup> Histologically, the tumour exhibits a biphasic growth pattern with the superficial component resembling squamous cell carcinoma (SCC) and



**Figure 3a:** CEA immunostaining showing intraluminal staining pattern within the tumour cells (IHC, 100x).



**Figure 3b:** p63 immunostain is positive in the tumour cells (IHC, 40x).



the deeper component demonstrating ductal differentiation indicating eccrine ductal carcinoma.<sup>2,3</sup> These tumours exhibit marked cytologic atypia with desmoplastic stroma and cords of deeply infiltrative tumour cells. Mitoses are frequent along with perineural invasion. Rarely, tumoural necrosis and lymphovascular invasion may be observed.

The histologic differentials include squamous cell carcinoma, porocarcinoma with squamous differentiation, microcystic adnexal carcinoma and cutaneous metastasis from visceral tumours.<sup>1</sup> Adequate sampling and histologic examination are necessary to demonstrate ductal differentiation in the deeper component to rule out squamous cell carcinoma. Chhibber *et al.* reported a case of squamoid eccrine ductal carcinoma, repeatedly misdiagnosed as squamous cell carcinoma on biopsy.<sup>1</sup>

Porocarcinoma usually affects the lower extremity while squamoid eccrine ductal carcinoma predominantly involves the head and neck region. Porocarcinoma demonstrates tumour cells with poroid characteristics in a background of pre-existing poroma. Microcystic adnexal carcinoma usually shows both follicular and ductal differentiation with keratinous cystic structures in the superficial component, and small nests of cells, lacking significant cytologic atypia in the deeper component.<sup>3</sup> p63 immunostain positivity favours a primary cutaneous sweat gland carcinoma over metastatic adenocarcinoma. EMA and CEA are typically positive in glandular tissue and usually negative in epithelial malignancies such as squamous cell carcinoma. Hence, their positivity indicates an adnexal origin.<sup>4</sup> Like other eccrine carcinomas, squamoid eccrine ductal carcinoma may become aggressive. Among 24 patients followed-up by van der Horst *et al.*, six (25%) developed local recurrence, three (12.5%) lymph node metastasis and one (4%) widespread systemic metastatic resulting in death.<sup>3</sup> It is unclear whether further workup like sentinel lymph node biopsy or imaging is indicated, due to the rarity of this tumour and lack of randomized studies. There is no accepted standard margin for surgical resection. Recurrence may be minimized by Mohs micrographic surgery, compared to wide local excision. A literature review by Kim *et al.* reported local recurrence rates of 10–70% after wide local excision which reduced to 0–5% following Mohs micrographic surgery after ~30.9 months follow-up.<sup>5</sup> Thus, these tumours require close clinical follow-up to avoid recurrence.

Squamoid eccrine ductal carcinoma is a diagnostic challenge, as it is an eccrine gland tumour histologically resembling squamous cell carcinoma superficially, and deeper tissue sampling is needed to reveal ductal differentiation. These deeply infiltrating tumours frequently demonstrate perineural invasion and are candidates for local recurrence and metastasis. Immunostaining with p63, EMA, CEA and mucicarmine may help in differentiating them from histologic mimics. Treatment with Mohs micrographic surgery ensures complete margin control, and is recommended to minimize local recurrence.

### Declaration of patient consent

Patient's consent not required as the patient's identity is not disclosed or compromised.

### Financial support and sponsorship

Nil.

### Conflicts of interest

There are no conflicts of interest.

### *Pooja Srivastava, Emily Dando<sup>1</sup>, Katherine Doeden<sup>2</sup>*

Departments of Pathology, <sup>1</sup>Dermatology, University of Pittsburgh Medical Center, <sup>2</sup>Department of Pathology, VA Medical Center, Pittsburgh, PA, United States

### Corresponding author:

Dr. Pooja Srivastava,  
Department of Pathology, University of Pittsburgh Medical Center,  
3550 Terrace Street, Pittsburgh, PA, United States.  
panacea.2417@gmail.com

### References

1. Chhibber V, Lyle S, Mahalingam M. Ductal eccrine carcinoma with squamous differentiation: A propos a case. *J Cutan Pathol* 2007;34:503–7.
2. Frouin E, Vignon-Pennamen MD, Balme B, Cavelier-Balloy B, Zimmermann U, Ortonne N, *et al.* Anatomoclinical study of 30 cases of sclerosing sweat duct carcinomas (microcystic adnexal carcinoma, syringomatous carcinoma and squamoid eccrine ductal carcinoma). *J Eur Acad Dermatol Venereol* 2015;29:1978–94.
3. van der Horst MP, Garcia-Herrera A, Markiewicz D, Martin B, Calonje E, Brenn T. Squamoid eccrine ductal carcinoma: A clinicopathologic study of 30 cases. *Am J Surg Pathol* 2016;40:755–60.
4. Terushkin E, Leffell DJ, Futoryan T, Cowper S, Lazova R. Squamoid eccrine ductal carcinoma: a case report and review of the literature. *Am J Dermatopathol* 2010;32:287–92.
5. Kim YJ, Kim AR, Yu DS. Mohs micrographic surgery for squamoid eccrine ductal carcinoma. *Dermatol Surg* 2005;31:1462–4.