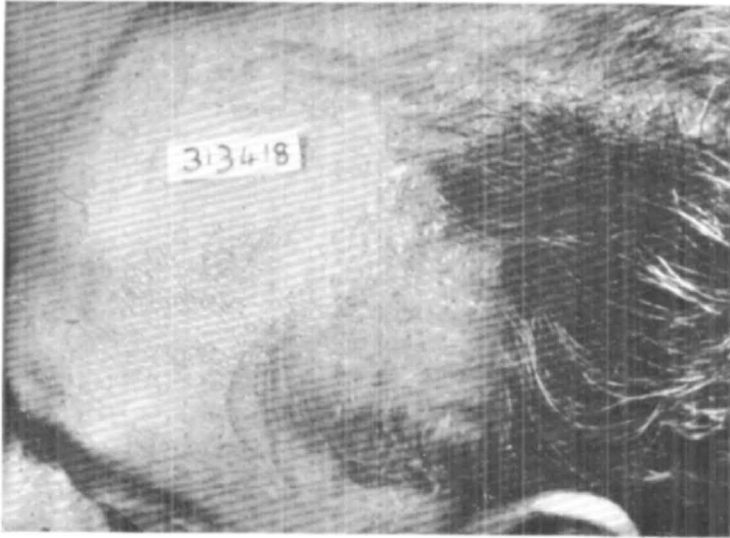


## WHAT IS YOUR DIAGNOSIS ?

40 year old male patient complained of gradual progressive baldness in patchess for 9 years. He was otherwise well.

Examination showed irregular areas of alopecia in the fronto-parietal temporal regions. Spreading periphery of the bald areas showed follicular papules and pustules of 2-3 m.m size. No regional lymphadenopathy. No history of alcoholism



### Differential diagnosis :

1. Folliculitis Decalvans
2. Lupus vulgaris
3. Blastomycosis like pyoderma

---

The clinical picture of a scarring alopecia with peripherally active border of follicular papules and pustules of 9 years' duration in an otherwise healthy patient is suggestive of Folliculitis Decalvans. Histopathology showed epidermis with patchy parakeratosis, hyperkeratosis and irregular acanthosis. Upper and mid dermis showed a dense infiltration of predominant plasma cells around the hair follicles. Some hair follicles were invaded by the infiltrate. There was also perivascular infiltration with plasma cells. Histologic features are also consistent with a diagnosis of Folliculitis decalvans.

**Final diagnosis :** Folliculitis Decalvans