

Circumscribed acral hypokeratosis: A benign localized lesion in the palm

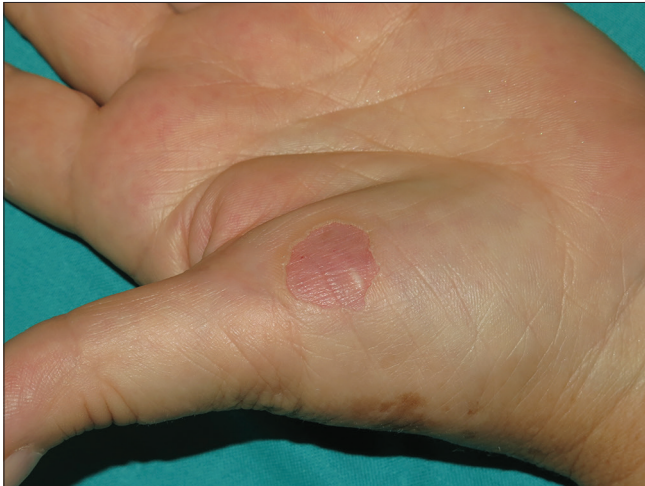

Figure 1: Circumscribed acral hypokeratosis: depressed pink plaque with well-defined borders

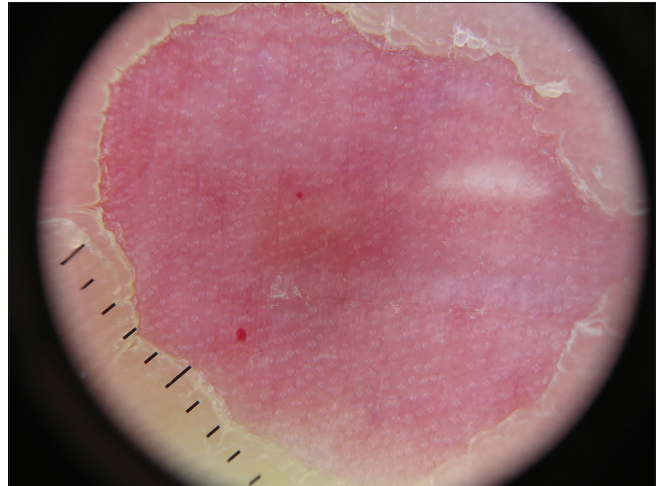


Figure 2: Circumscribed acral hypokeratosis: regularly distributed white rosettes in a pink background (Dermlite DL200 HR polarized light mode, ×10)

Circumscribed acral hypokeratosis is a benign entity, usually presenting in middle-aged women, over the thenar or hypothenar eminences (less frequently in the soles) as an asymptomatic depressed pink plaque with well-defined borders [Figure 1].¹ Dermoscopy shows regularly distributed white dots (which we have described as rosettes) which appear to correspond to the acrosyringium [Figure 2].² Histologic examination shows an abrupt stair-like thinning of the horny layer. Although no clear etiology has been determined for circumscribed acral hypokeratosis, it has been proposed to be a localized acquired genodermatosis of keratinocytes secondary to repeated trauma or other noxious exposition.^{3,4} Even though it is usually benign in its course, there are a few reports of premalignant transformation in the elderly.⁵ Treatment options in such cases include cryotherapy, topical fluorouracil or calcipotriol, ablative laser or surgery, with variable results.^{3,4} Circumscribed acral hypokeratosis is an underdiagnosed dermatosis and it should be included in the differential diagnosis of well-defined erosive lesions of the palms and the soles.

How to cite this article: Rizo-Potau D, Marti-Marti I, Martin-Ortega E. Circumscribed acral hypokeratosis: A benign localized lesion in the palm. *Indian J Dermatol Venereol Leprol* 2022;88:426-7.

Received: December, 2019 **Accepted:** May, 2020 **Epub Ahead of Print:** February, 2021 **Published:** April, 2022

DOI: 10.4103/ijdv.IJDVL_1095_19 **PMID:** 32969354

This is an open-access article distributed under the terms of the Creative Commons Attribution-Non Commercial-Share Alike 4.0 License, which allows others to remix, transform, and build upon the work non-commercially, as long as the author is credited and the new creations are licensed under the identical terms.

Declaration of patient consent

The authors certify that they have obtained all appropriate patient consent forms. In the form, the patient has given her consent for her images and other clinical information to be reported in the journal. The patient understands that name and initials will not be published and due efforts will be made to conceal identity, but anonymity cannot be guaranteed.

Financial support and sponsorship

Nil.

Conflicts of interest

There are no conflicts of interest.

Daniel Rizo-Potau, Ignasi Marti-Marti, Encarnación Martín-Ortega

Department of Dermatology, Hospital Clínic de Barcelona, University of Barcelona, Barcelona, Spain

Corresponding author:

Dr. Daniel Rizo-Potau,

Department of Dermatology, Hospital Clínic de Barcelona, University of Barcelona, Barcelona, Spain.

rizo@clinic.cat

References

1. Giacaman-von der Weth MM, Partarrieu-Mejías F, Ferrer-Guillén B, Hernández-Bel P. Circumscribed palmar hypokeratosis. *J CutanPathol* 2019;46:713-6.
2. Vilas Boas da Silva PT, Rodríguez-Lomba E, Avilés-Izquierdo JA, Ciudad-Blanco C, Suárez-Fernández R. Dermoscopic features of circumscribed palmar hypokeratosis. *JAMA Dermatol* 2017;153:609-11.
3. Urbina F, Pérez A, Requena L, Rütten A. Circumscribed palmar or plantar hypokeratosis 10 years after the first description: What is known and the issues under discussion. *ActasDermosifiliogr* 2014;105:574-82.
4. Erkek E, Çetin ED, Sezer E, Sahin S. Circumscribed acralhypokeratosis: A report of 2 cases and a brief review of the literature. *Cutis* 2014;93:97-101.
5. Kanitakis J, Lora V, Balme B, Roby J. Premalignant circumscribed palmar hypokeratosis: A new form of circumscribed palmar hypokeratosis? Case report and literature review. *Dermatology* 2010;220:143-6.